

Is Elevated Gastric Tissue NOX2 Associated with Lymphoma of Mucosa-Associated Lymphoid Tissue?

Emilie Bessède^{1,2#}, Christiane Copie-Bergman^{3,4#}, Philippe Lehours^{1,2}, Michael Levy⁵, Karen Leroy⁴, Maryse Baia^{3,4}, Audrey Riou⁶, Francis Mégraud^{1,2}, Jean-Charles Delchier⁵, Nathalie Salles^{1,2,7*}

¹ Infection à *helicobacter*, inflammation et cancer INSERM : U853, Université Victor Segalen - Bordeaux II, 146, rue leo saignat 33076 Bordeaux Cedex,FR

² Laboratoire de bactériologie CHU Bordeaux, Hôpital Pellegrin, Place Amélie Rabat-Léon, 33000 Bordeaux, FR

³ Institut Mondor de Recherche Biomédicale INSERM : U955, Université Paris XII - Paris Est Créteil Val-de-Marne, IFR10, FR

⁴ Service d'anatomie pathologique Assistance publique - Hôpitaux de Paris (AP-HP), Hôpital Henri Mondor, Université Paris XII - Paris Est Créteil Val-de-Marne, Créteil,FR

⁵ Service d'hépatogastro-entérologie Assistance publique - Hôpitaux de Paris (AP-HP), Hôpital Henri Mondor, Université Paris XII - Paris Est Créteil Val-de-Marne, 94000 Créteil,FR

⁶ Plateforme de Ressources Biologiques Assistance publique - Hôpitaux de Paris (AP-HP), Hôpital Henri Mondor, Hôpital Albert Chenevier, 94010 Créteil,FR

⁷ Pôle de Gériatrie Clinique CHU Bordeaux, Hôpital Xavier Arnoz, 33604 Pessac,FR

* Correspondence should be addressed to: Nathalie Salles <nathalie.salles@chu-bordeaux.fr >

E. Bessède and C. Copie-Bergman contributed equally to the work.

Abstract

***Helicobacter pylori* infection plays a crucial role in the pathogenesis of gastric extranodal marginal zone lymphoma of mucosa-associated lymphoid tissue (MALT). However, the host response to this infection is also important in the development of the disease. In particular, NADPH oxidases (NOX) which generate reactive oxygen species (ROS) are known to induce cell damage possibly leading to carcinogenesis. We analyze for the first time NOX expression in a series of well characterized Gastric MALT Lymphoma (GML) patients in comparison to controls. Our observation leads to the hypothesis that NOX2 expression is significantly associated with GML.**

Helicobacter pylori is involved in the pathogenesis of gastritis, peptic ulcer disease and gastric adenocarcinoma. In addition, a causal role of *H. pylori* infection in the development of primary gastric extranodal marginal zone lymphoma of Mucosa-Associated Lymphoid Tissue (MALT) is now well established. Indeed, the eradication of *H. pylori* infection leads to a regression of Gastric MALT Lymphoma (GML) in 75% of the cases.

The clinical evolution of patients responding to *H. pylori* eradication or to chemotherapy is usually favourable. However histological monitoring of GML patients has shown a higher incidence of corpus predominant and pangastric atrophy with intestinal metaplasia as well as an evolution to gastric adenocarcinoma in a limited number of cases. The development of gastric adenocarcinoma at the initial location of the lymphoma suggests that the process of carcinogenesis is favoured by the persistence of a residual disease.

Chronic gastric inflammation may certainly lead to an increased production of reactive oxygen species (ROS) implying the NOX family of superoxide-generating NADPH oxidases. Indeed, Salles *et al.* showed that NOX family (NOX2 and NOX5) was expressed in human stomach biopsies and was associated with the severity of inflammation and atrophic gastric lesions (8).

The NOX family consists of multiple members, including NOX2 and NOX5. The NOX2 enzyme is traditionally referred to as the gp91phox subunit of the "phagocyte NADPH oxidase" as white blood cells of myeloid lineage are the predominant site of expression. NOX2 is without a doubt an enzyme involved in host defense. NOX5 is essentially found in lymphoid tissue but not in circulating lymphocytes; NOX5 is enriched/abundant in B cell rich regions surrounding germinal centers, as well as in T cell rich regions.

Based on the fact that 1) NOX5 is generally found in lymphoid tissue (1) and 2) tumor cells of hairy cell leukemia express NOX5 (5), we decided to explore NOX5 expression in GML patients. Furthermore, since GML is associated with *H. pylori* infection and an inflammatory immune response, NOX2 expression was studied as well. As a result, the aim of this study was to quantify NOX2 and NOX5 mRNA expression in GML biopsies compared to chronic gastritis biopsies in order to establish a potential link between NOX activity and GML development.

The clinical data, *H. pylori* status, histopathological (Sydney system) and molecular features of gastric biopsies of GML patients and controls are summarized in Table 1.

GML patients

Nineteen of 39 GML patients were *H. pylori* positive at the time of diagnosis. One of them had a past history of *H. pylori* infection but was negative at the time of the gastric biopsy used for this study. Most patients presented with localized disease (n=23) while 9 and 7 patients were stage IIE and IV, respectively. In 17 patients, the t(11;18)(*API2-MALT1*) translocation was detected in tumour cells.

Eighteen patients received anti-*H. pylori* treatment and 5 of them were in remission of the disease at the end of the treatment. These 5 patients had t(11;18) negative GML.

The remaining patients were treated with either chlorambucil alone, rituximab alone, or a combination of rituximab–chlorambucil as previously described.

After a median follow-up of 3 years (range 0–20 years), 30 patients were in histological remission (9 Complete Remission (CR), 21 probable Minimal Residual Disease (pMRD) according to the GELA score), 5 were in partial remission (responding Residual Disease (rRD)), three patients presented persisting disease (No Change (NC)) and one patient was lost to follow-up.

Gastritis patients

In the control group, 17 out of 43 were *H. pylori* positive.

Comparison of the Sydney score between GML patients at diagnosis and the control group

The percentages of activity, inflammation, atrophy and intestinal metaplasia observed in gastric biopsies of GML patients and in the control group were compared following the updated Sydney System for the classification of gastritis. A statistical difference was found for inflammation ($X^2 = 6.23$) and for intestinal metaplasia ($X^2 = 3.86$). Inflammation was significantly higher in the control group than in GML patients, and intestinal metaplasia was significantly higher in GML patients than in the control group. None of the patients with GML or in the control group had gastric dysplasia.

NOX expression according to *H. pylori* status

NOX2 and NOX5 were detected in all biopsies included in the present study. Considering all of the biopsies, NOX2 expression was almost 167 times higher than NOX5 expression: NOX2 relative mRNA levels: 0.212 ± 0.532 , and NOX5: 0.001 ± 0.003 . NOX2 and NOX5 gastric mRNA expression were positively correlated ($r=0.36$, $p=0.001$) (Figure 1).

No difference was observed in NOX2 and NOX5 expression according to *H. pylori* status in GML patients ($p=0.633$ and $p=0.620$, respectively) (Figure 2A). Considering gastritis patients, there was also no difference in NOX2 expression and *H. pylori* status ($p=0.441$). However, NOX5 expression was less important in *H. pylori* negative gastritis patients than in *H. pylori* positive gastritis patients ($p=0.001$) (Figure 2B).

NOX expression in GML patients compared to gastritis patients

NOX2 expression increased significantly in GML patients compared to gastritis patients ($p<0.0001$), whereas NOX5 expression did not vary between these two populations ($p=0.149$) (Figure 3). NOX2 expression was also significantly lower in gastric biopsies obtained from 10 patients after lymphoma remission whereas NOX5 expression did not vary ($p<0.0001$ and $p=0.45$, respectively) (Figure 4).

NOX expression according to the presence of the t(11;18) translocation in GML patients

There was no association between NOX2 ($p=0.301$) or NOX5 expression ($p=0.581$) and the presence of the t(11;18) translocation ($p=0.966$ and $p=0.166$, respectively).

NOX expression according to the Sydney system

Mean values of NOX2 and NOX5 expression according to the Sydney system are presented in Table 2. No difference was found between NOX2 and NOX5 expression and the score of the different histopathological parameters, i.e. activity, inflammation, atrophy and intestinal metaplasia.

The aim of the present study was to investigate the putative role of the NOX family of superoxide-generating NADPH oxidases in the process of GML development and occurrence of preneoplastic lesions (atrophy and intestinal metaplasia). We focused on the expression of NOX2 and NOX5 mRNA in GML biopsies compared to biopsies from gastritis patients as the control group. Presented data are primary data; further studies are needed using 1) immunohistochemistry in order to identify the nature of NOX2 and NOX5 producing cells and 2) ROS measurement.

In the present study, the cases and controls were not chosen randomly but we deliberately included a high proportion of *H. pylori* negative in both groups in order to be able to compare the impact of *H. pylori* status. An association between NOX2 expression and gastric MALT lymphoma is shown for the first time.

In both groups of patients, high levels of NOX were found which may reflect the recruitment of polynuclear and mononuclear cells in gastric mucosa which can therefore influence the inflammatory response. However, there was no correlation between *H. pylori* status and NOX2 expression, hence the NOX2 expression levels merely reflect the innate immune response rather than the adaptive immune response of the gastric mucosa. In contrast, NOX5 expression is significantly lower in *H. pylori* infected gastritis patients. Indeed *H. pylori* γ -glutamyl transpeptidase (GGT) (9), and the VacA cytotoxin described as a ubiquitous immunosuppressive factor for the bacteria (3) inhibit T lymphocyte proliferation and are of major importance in gastric colonization and persistence of the infection, explaining the NOX5 expression decrease. The inverse correlation between NOX5 and *H. pylori* status found in gastritis patients but not in gastric MALT lymphoma patients may be explained by the fact that tumor infiltrating T lymphocytes do not recognize the same antigens as gastritis T lymphocytes and are already engaged in a cross talk with B lymphocytes (4). GML patients showed higher NOX2 expression than gastritis patients. NOX2 expression significantly decreased after lymphoma remission. No association was found between NOX2 levels and t(11;18) suggesting that NOX2 do not play a major role in the occurrence of GML-associated cytogenetic abnormalities.

The exact type of NOX2 producing cells remains to be determined and whether NOX2 production is related to cells of the GML immune microenvironment or to the tumor cells (per se themselves) is currently unknown. The tumor immune microenvironment is composed of follicular dendritic cells, macrophages, mast cells, granulocytes and regulatory T-cells and plays a major role in various types of lymphomas, as demonstrated for example in follicular lymphomas (2). However, few studies have addressed the question of the role of the immune microenvironment in the context of GML. Mouse models of GML have shown, in the early stages of the disease, the recruitment of neutrophils which, in coordination with the inflammatory response of epithelial cells, participate in the recruitment of macrophages and lymphoid infiltrating cells (7). The role of antigen presenting cells has also been shown in BALB/c mice infected with *Helicobacter felis* which develop GML. Dendritic cells rapidly disappear after eradication of *H. pylori*, and reappear in recurrent GML, and their density clearly correlates with disease outcome (6). This peculiar subset of antigen presenting cells could be a good candidate for producing NOX in human GML.

The second aim of this study was to consider the potential role of NOX in the development of preneoplastic lesions in GML. Previous studies conducted by our group have shown that GML patients develop significantly more preneoplastic lesions, e.g. atrophy and intestinal metaplasia during the follow-up period as compared to patients with non-ulcer dysplasia. Similar results were observed in the present study with GML patients showing an elevated percentage of intestinal metaplasia (7%) as compared to the control group (4%). It is therefore tempting to speculate that NOX2 may have a significant impact on the development of preneoplastic lesions in the context of GML but further studies are needed using immunohistochemistry in order to better understand the pathogenesis.

In conclusion, this is the first study to demonstrate an association between NOX2 expression in a large series of GML patients when compared to a gastritis control group. Further studies are ongoing to identify the nature of the NOX2 producing cells which may be either GML tumor cells or cells from the immune microenvironment.

Innovation

For the first time, NOX expression was studied directly on human stomach biopsies issued from patients suffering from GML or gastritis. Interestingly, we found that NOX2 expression was higher in GML patients as compared to the control group and that NOX2 expression decreased with the remission of the disease. These results raise the question of the potential role of NOX2 in the development of GML and associated preneoplastic lesions, namely atrophy and intestinal metaplasia which have been shown to be increased in the context of GML.

Notes

Material and methods

Patients

Thirty-nine patients (23 men, 16 women; median age = 57.5 years, range = 24–80 years) with primary GML treated and followed from November 1995 to May 2010 in the Gastroenterology Unit of Henri Mondor Hospital were included in the study. Diagnosis of GML was made on upper endoscopic examination and then ascertained by histological analysis of gastric biopsies from all of the patients.

Tumors were graded according to the Ann Arbor system, modified by Musshof. The initial evaluation included blood tests for lacticodeshydrogenase (LDH) and beta2microglobulinemia, chest x-ray, thoracic and abdominal CT scans, colonoscopy, small bowel barium x-ray, and bone marrow biopsy. In addition, endoscopic ultrasonography (EUS) was performed, according to the method described in a previous study. Presence or absence of perigastric lymph nodes was recorded.

Forty-three patients (20 men, 23 women; median age 56 years (range=23–92 years) with chronic gastritis without any macroscopic lesions were enrolled in the study as a control group (28 patients from the Henri Mondor Hospital and 15 patients from the Bordeaux Hospital). Written informed consent of non-opposition to use biological material for study purposes was obtained from all patients.

Histology and immunohistochemistry

Tissues analyzed were human gastric biopsies. Tissue specimens were fixed in formalin, paraffin-embedded and routinely processed for histological studies. In addition, gastric biopsies were snap-frozen in liquid nitrogen for genotypic studies. Hematoxylin and eosin stained sections were reviewed for all cases.

Histological diagnosis of GML was made according to the criteria defined by Isaacson *et al.* : presence of a diffuse infiltrate of CD20+ CD5- centrocyte-like B cells in the lamina propria with prominent lymphoepithelial lesions and reactive lymphoid follicles. Immunohistochemistry was performed in all cases on paraffin sections. Presence of *H. pylori* was assessed on modified Giemsa stained sections and by culture.

After treatment, follow-up gastric biopsies were analyzed and tumoral response to treatment was assessed using the GELA histological grading system.

Gastric biopsies of GML patients at diagnosis and of control group patients were evaluated for the severity of gastritis (activity, inflammation, atrophy, intestinal metaplasia, dysplasia, *H. pylori*) and graded on a 0–3 scale according to the Updated Sydney system.

All gastric biopsies of GML patients at diagnosis and of the control group were analyzed for NOXmRNA expression. In addition, follow-up gastric biopsies of 10 GML patients were analysed at partial (1 rRD) or histological remission (3 CR/6 pMRD).

RNA extraction

Total RNAs were extracted from frozen tissue samples using the TRIzol reagent (Life Technologies, Cergy-Pontoise, France). Two µg of total RNAs were reverse transcribed with Superscript II (Life technologies) in a final volume of 20 µl containing 300 ng random hexamers, according to the manufacturer's instructions. Following enzyme heat inactivation, cDNAs were diluted 1:5 in water and stored at -20°C.

Real-time PCR

RNA extraction was performed using the RNeasy Mini-kit (Qiagen SA, Courtaboeuf, France) following the manufacturer's instructions. cDNA was generated using the High-Capacity cDNA Archive kit (Applied Biosystems, Courtaboeuf, France). Real-time quantitative PCRs were performed using Assays-on-Demand kits from Applied Biosystems for gene expression products of NOX2, NOX5 and a control endogen gene, glyceraldehyde-3-phosphate dehydrogenase (GAPDH), designed with the corresponding sequences of the GenBank accession numbers Hs00166163_m1, Hs00225846_m1, Hs99999905_m1. TaqMan Minor Groove Binder probes were synthesized with the reporter dye FAM covalently linked to the 5'P ends and the non-fluorescent quencher at the 3'P ends, which were phosphorylated to prevent probe extension. The reaction components were prepared for a 50 µL mixture in a 96 well plate according to the manufacturer's recommendations: 25 µL of TaqMan Universal PCR Master Mix, 2.5 µL of 20X Assays-on-Demand Gene Expression Assay Mix, 20 µL of RNase-free water and 2.5 µL of cDNA. Thermal cycling conditions were the following: 50°C for 2 minutes and 95°C for 10 minutes, followed by 15 seconds of denaturation at 95°C and 1 minute of annealing and extension at 60°C for 40 cycles in an ABI PRISM 7000 (Applied Biosystems).

The different genes were all tested in duplicate for each patient. Data were normalized for the amount of GAPDH ($2^{\delta C_{tNOX}} - \delta C_{tGAPDH}$) using an ABIPrism pre-developed taqman assay reagent as already described.

Detection of the t(11;18) fusion transcript

The presence of a t(11;18) translocation was determined by amplification and sequencing of the API2-MALT1 fusion transcript as previously published.

Treatment of H. pylori-positive patients

H. pylori positive patients received as eradication regimen a combination of omeprazole (20 mg b.i.d.) plus amoxicillin (1 g b.i.d.) and clarithromycin (500 mg b.i.d.) or metronidazole (500 mg b.i.d.) for 7 days.

For GML *H. pylori* -positive patients , eradication of *H. pylori* infection was evaluated 2 months after the end of the treatment by performing a new upper endoscopy with biopsy samples. If the infection was still present, a new *H. pylori* eradication treatment was given. The tumoral response was assessed 6 months after treatment by upper endoscopy with biopsy samples on residual lesions or on the previous location of the disease.

H. pylori -negative GML patients or GML patients who failed to respond despite effective *H. pylori* eradication received either 1) chlorambucil (6mg/m²/day, 14 days/month for 12 months) when t(11;18) negative, 2) the association rituximab–chlorambucil according to the protocol proposed by Martinelli *et al.* for indolent non-Hodgkin's lymphoma or 3) rituximab alone when t(11;18) positive.

Statistical analysis

The association between categorical variables was examined using the X^2 test. NOX2 and NOX5 gastric mRNA levels were compared for more than two groups by Kruskal–Wallis analysis of variance and between two groups by the Mann–Whitney test. Bivariate correlations were tested by Spearman test between NOX2 and NOX5 mRNA levels. Differences with a p value of less than 0.05 were considered significant. All statistics were performed using SPSS 16.0F for Windows software (SPSS Inc., Chicago, IL, USA).

References:

- 1 . Banfi B , Molnar G , Maturana A , Steger K , Hegedus B , Demarex N , Krause KH . A Ca(2+)-activated NADPH oxidase in testis, spleen, and lymph nodes . The Journal of biological chemistry . 276 : 37594 - 37601 2001 ;
- 2 . de Jong D , Fest T . The microenvironment in follicular lymphoma . Best Pract Res Clin Haematol . 24 : 135 - 146 2011 ;
- 3 . Gebert B , Fischer W , Weiss E , Hoffmann R , Haas R . Helicobacter pylori vacuolating cytotoxin inhibits T lymphocyte activation . Science . 301 : 1099 - 1102 2003 ;
- 4 . Hussell T , Isaacson PG , Crabtree JE , Spencer J . The response of cells from low-grade B-cell gastric lymphomas of mucosa-associated lymphoid tissue to Helicobacter pylori . Lancet . 342 : 571 - 574 1993 ;
- 5 . Kamiguti AS , Serrander L , Lin K , Harris RJ , Cawley JC , Allsup DJ , Slupsky JR , Krause KH , Zuzel M . Expression and activity of NOX5 in the circulating malignant B cells of hairy cell leukemia . J Immunol . 175 : 8424 - 8430 2005 ;
- 6 . Mueller A , O'Rourke J , Chu P , Chu A , Dixon MF , Bouley DM , Lee A , Falkow S . The role of antigenic drive and tumor-infiltrating accessory cells in the pathogenesis of helicobacter-induced mucosa-associated lymphoid tissue lymphoma . The American journal of pathology . 167 : 797 - 812 2005 ;
- 7 . Nakamura M , Murayama SY , Serizawa H , Sekiya Y , Eguchi M , Takahashi S , Nishikawa K , Takahashi T , Matsumoto T , Yamada H , Hibi T , Tsuchimoto K , Matsui H . "Candidatus Helicobacter heilmannii" from a cynomolgus monkey induces gastric mucosa-associated lymphoid tissue lymphomas in C57BL/6 mice . Infect Immun . 75 : 1214 - 1222 2007 ;
- 8 . Salles N , Szanto I , Herrmann F , Armenian B , Stumm M , Stauffer E , Michel JP , Krause KH . Expression of mRNA for ROS-generating NADPH oxidases in the aging stomach . Experimental gerontology . 40 : 353 - 357 2005 ;
- 9 . Schmees C , Prinz C , Treptau T , Rad R , Hengst L , Voland P , Bauer S , Brenner L , Schmid RM , Gerhard M . Inhibition of T-cell proliferation by Helicobacter pylori gamma-glutamyl transpeptidase . Gastroenterology . 132 : 1820 - 1833 2007 ;

Figure 1

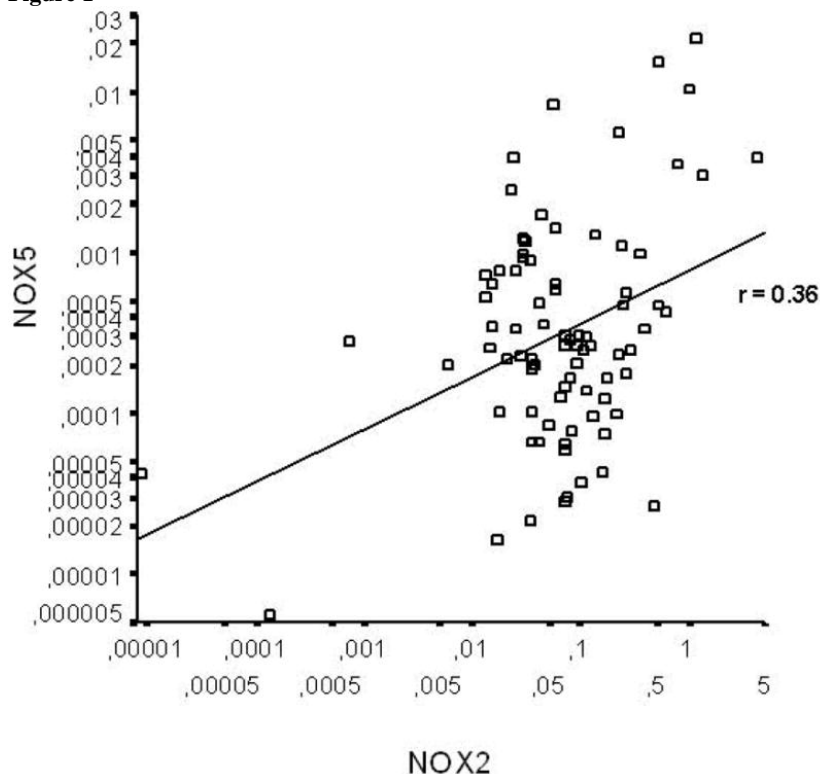


Figure 2

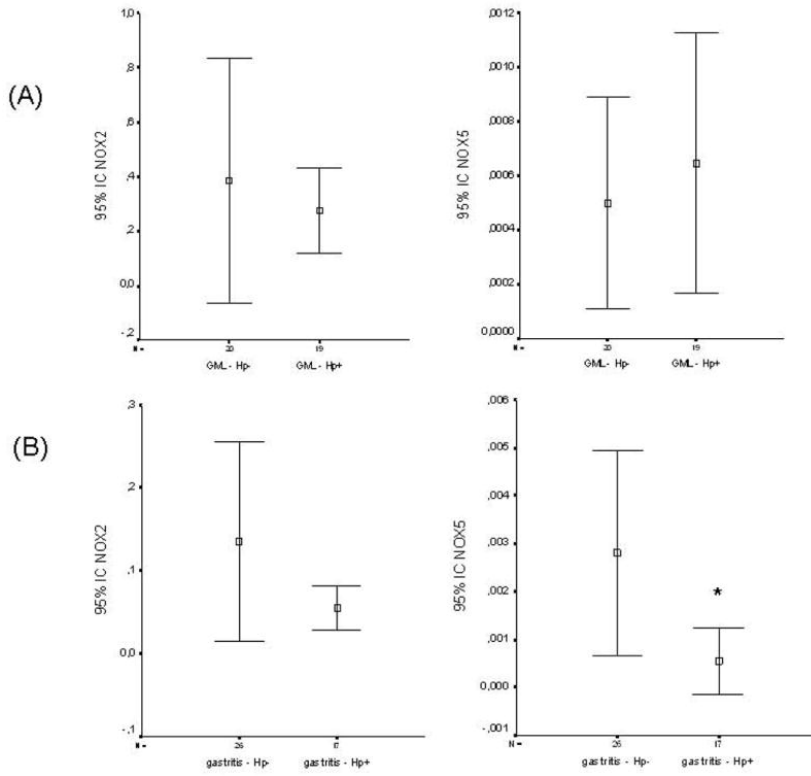


Figure 3

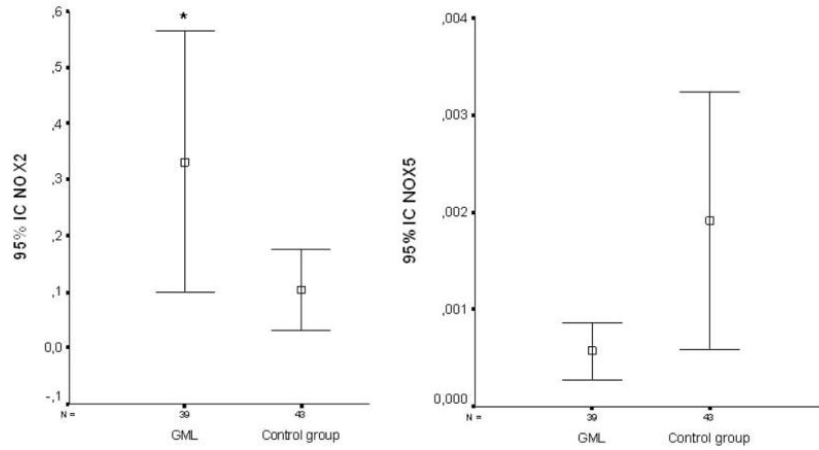


Figure 4

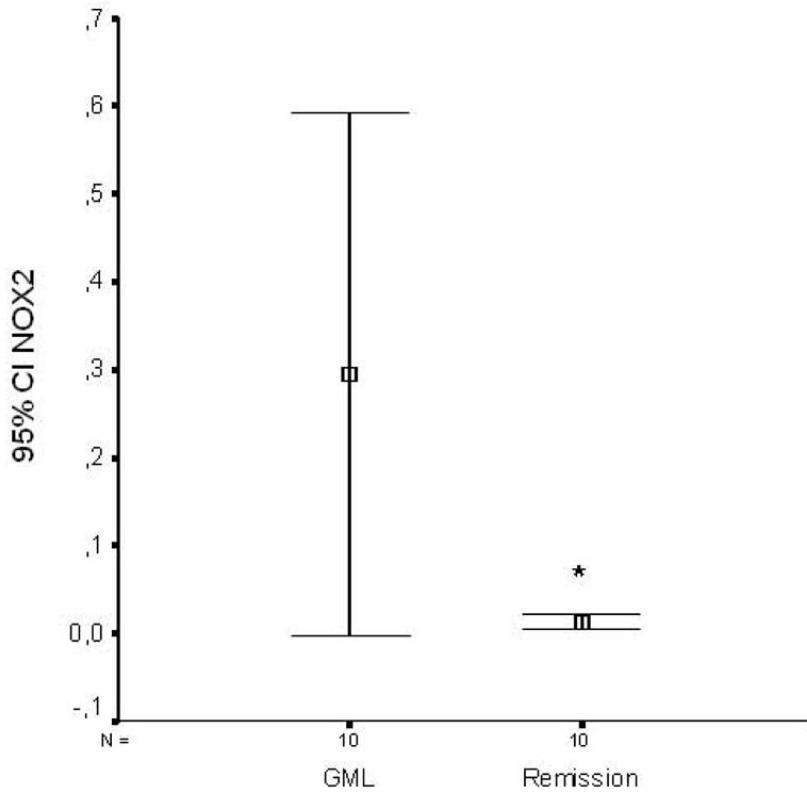


Table 1

Clinical and molecular features of the 39 patients with primary gastric MALT lymphoma and 43 patients with gastritis (Control group).

	MALT lymphoma	Control group
Number of patients	39	43
Age at diagnosis	57.5	56
median age (range)	24–80	23–92
Men/women	23/16	20/23
Follow-up since diagnosis		
Median (range)	3 yrs [0–20yrs]	0
<i>H. pylori</i> -positive/<i>H. pylori</i>- negative	19/20	17/26
Extent of the disease		
Stage IE [*] /II E ^o /IV ^{**} (n)	23/9/7	–
Molecular status at diagnosis		
Detectable t(11;18), n	17	0
Sydney score at diagnosis		
Activity ≥ 2	4 (10%)	10 (23%)
Inflammation ≥ 2	13 (33%)	26 (60%)
Atrophy ≥ 2	5 (12,8%)	6 (14%)
Intestinal metaplasia ≥ 2	3 (7%)	2 (4%)

* disease limited to the stomach

^o perigastric lymph nodes on endoscopic ultra sound^{**} medullar and/or pulmonary involvement

Table 2

Expression of NOX2 and NOX5 in different biopsies according to the Updated Sydney system.

GML=39			Control group =43		
Sydney score	NOX5	NOX2	Sydney score	NOX5	NOX2
(N = number of biopsies)	mean	mean	(N = number of biopsies)	mean	mean
activity = 0 (N=26)	0.00069	0,42697	activity = 0 (N=27)	0.00229	0.11760
activity = 1 (N=9)	0.00040	0,14821	activity = 1 (N=6)	0.00269	0.12649
activity = 2 (N=2)	0.00012	0,12849	activity = 2 (N=4)	0.00056	0.07035
activity = 3 (N=2)	0.00045	0,19357	activity = 3 (N=6)	0.00027	0.03783
inflammation = 0 (N=1)	0.00386	4,40762	inflammation = 0 (N=2)	0.00024	0.04669
inflammation = 1 (N=25)	0.00055	0,25169	inflammation = 1 (N=15)	0.00315	0.11444
inflammation = 2 (N=12)	0.00035	0,18026	inflammation = 2 (N=22)	0.00152	0.10853
inflammation = 3 (N=1)	0.00016	0,08105	inflammation = 3 (N=4)	0.00020	0.06120
atrophy = 0 (N=28)	0.00055	0,36885	atrophy = 0 (N=29)	0.00186	0.11647
atrophy = 1 (N=6)	0.00085	0,28605	atrophy = 1 (N=8)	0.00328	0.11401
atrophy = 2 (N=5)	0.00034	0,18000	atrophy = 2 (N=4)	0.00029	0.01942
atrophy = 3 (N=0)	-	-	atrophy = 3 (N=2)	0.00020	0.03762
intestinal metaplasia = 0 (N=34)	0.00061	0,36438	intestinal metaplasia = 0 (N=37)	0.00218	0.11400
intestinal metaplasia = 1(N=2)	0.00041	0,05450	intestinal metaplasia = 1 (N=4)	0.00021	0.04506
intestinal metaplasia = 2 (N=2)	0.00020	0,15561	intestinal metaplasia = 2 (N=2)	0.00019	0.02215
intestinal metaplasia = 3 (N=1)	0.00009	0,13490	intestinal metaplasia = 3 (N=0)	-	-