



**HAL**  
open science

## Evolution of the upper and lower landing site after endovascular aortic aneurysm repair.

Adrien Kaladji, Alain Cardon, Bruno Laviolle, Jean-François Heautot, Guillaume Pinel, Antoine Lucas

► **To cite this version:**

Adrien Kaladji, Alain Cardon, Bruno Laviolle, Jean-François Heautot, Guillaume Pinel, et al.. Evolution of the upper and lower landing site after endovascular aortic aneurysm repair.. *Journal of Vascular Surgery*, 2012, 55 (1), pp.24-32. 10.1016/j.jvs.2011.07.067 . inserm-00696582

**HAL Id: inserm-00696582**

**<https://inserm.hal.science/inserm-00696582>**

Submitted on 9 Jan 2013

**HAL** is a multi-disciplinary open access archive for the deposit and dissemination of scientific research documents, whether they are published or not. The documents may come from teaching and research institutions in France or abroad, or from public or private research centers.

L'archive ouverte pluridisciplinaire **HAL**, est destinée au dépôt et à la diffusion de documents scientifiques de niveau recherche, publiés ou non, émanant des établissements d'enseignement et de recherche français ou étrangers, des laboratoires publics ou privés.

# Evolution of the upper and lower landing site after endovascular aortic aneurysm repair

Adrien Kaladji<sup>1,2,3</sup>, Alain Cardon<sup>1</sup>, Bruno Laviolle<sup>4,5,6</sup>, Jean-François Heautot<sup>7</sup>, Guillaume Pinel<sup>1</sup>, and Antoine Lucas<sup>1,2,3</sup>

1. CHU Rennes, Vascular surgery unit, F-35033 Rennes, France
2. INSERM, U642, F-35000 Rennes, France
3. Université de Rennes 1, LTSI, F-35000 Rennes, France
4. CHU Rennes, Department of clinical pharmacology, F-35033 Rennes, France
5. INSERM, 0203, Clinical Research Center, F-35033 Rennes, France
6. University Rennes 1, Faculté de médecine, F-35043 Rennes, France
7. CHU Rennes, Department of medical imaging, F-35033 Rennes, France

## **Corresponding author:**

Adrien Kaladji, Service de Chirurgie Vasculaire, CHU Hôpital Pontchaillou, 2 rue Henri Le Guilloux, 35033 Rennes cedex 9, France

Email: kaladrien@hotmail.fr

## **ABSTRACT**

**Background:** To study the evolution and correlation between the aortic neck and distally-located iliac necks following endovascular treatment of abdominal aortic aneurysms (AAA).

**Methods:** Of 179 patients who had undergone AAA repair between 2003 and 2007, 61 were included in this retrospective study as they received the same radiological follow-up. In total, 61 aortic necks and 115 iliac arteries were analyzed using the data collected at the preoperative scan, 1-month visit, and final follow-up, with a minimum follow-up period of 24 months and a mean of 39 months ( $\pm 15.2$ ). Three measurements were taken of the aortic neck (subrenal D1a, 15mm below the lowest renal artery D1b, and at the origin of the aneurysm D1c) and three at the level of the iliac arteries (origin Da, middle Db, and the iliac bifurcation Dc). These measurements were analyzed using ANOVA and Spearman correlation coefficient. The results were evaluated in terms of subsequent endoleaks, migrations, and reinterventions. All diameters were compared between patients with a regression of more than 10% in the greatest diameter of AAA at last follow-up (Group A, n=35) and those without (Group B, n=26).

**Results:** All diameters increased significantly over time at the level of both the proximal neck (D1a=3.7 $\pm$ 2.8, P=0.018; D1b=4.4 $\pm$ 2.5, P=0.016; D1c=4.3 $\pm$ 3.1, P=0.036) and iliac arteries (Da=2.1 $\pm$ 0.2, P=0.0006; Db=2.5 $\pm$ 0.5, P=0.0006; Dc=3 $\pm$ 0.7, P=0.007). The increase in diameters at the proximal neck and iliac arteries evolved independently (insignificant correlation) with the exception of D1b and Dc (P=0.006), which showed a weak correlation ( $r=0.363$ ). The patients of Group A presented increases in all diameters, although to a less significant extent (P<0.05) than Group B. During follow-up, a proximal endoleak and a distal endoleak occurred, both requiring reintervention.

**Conclusion:** Our results show a trend towards dilatation of the aortic neck and iliac arteries with no correlation between the two levels, even in patients with a regression of the aneurysm sac during follow-up. Although there was no correlation with the occurrence of endoleaks in this study, our results suggest the need for a longer follow-up, especially on the landing sites.

## **INTRODUCTION**

The long-term results of endovascular treatment (EVAR) of abdominal aortic aneurysms (AAA) in terms of morbidity and mortality are well-known<sup>1,2</sup>. However, certain complications are directly related to the presence of endoprosthesis in native arteries. One such complication is the dilatation of the aortic neck, which may be responsible for proximal leaks and even endoprosthesis migration, requiring reintervention. This dilatation may relate to the oversizing and radial force of the endoprosthesis, especially during the early months<sup>3</sup>. In the long-term, dilatation may be due to the progression of artery wall degeneration<sup>4</sup>. At the level of the distal iliac necks, there appears to be a dilatation, yet only a few studies have treated the subject<sup>5</sup>. We do not know, however, if the dilatations develop in parallel, *i.e.*, affecting the proximal and distal necks in the same proportions, or if they have two distinct evolutions. In addition, we do not know whether the dilatation concerns only the anchor zone based on which the endoprosthesis diameter was chosen, or if it encompasses the adjacent vascular segments covered by the endoprosthesis. The aim of our study was to examine the correlation between the diameter increases at the proximal and distal necks, while investigating both the anchor zones and adjacent vascular segments, as well as observing clinical events such as endoleaks.

## **METHODS**

Of 179 patients having undergone AAA repair using EVAR in our clinic between 2003 and 2007, 61 (57 men, 4 women) with the same follow-up protocol and scan analysis undertaken in the radiology department of our centre were included in this retrospective study, with a mean follow-up of 39 months (standard deviation=15.2 months; minimum 24 months; maximum 84 months; median 36 months). AAA repair was considered provided that the maximum aneurysmal diameter exceeded 50mm, the patient suffered from pain, or its annual

growth was more than 10mm. During the studied period, endovascular treatment was considered whenever the patient was not eligible for open surgery in accordance with the criteria<sup>6</sup> of the French National Agency of Health Accreditation and Evaluation. Patients who had undergone emergency surgery, isolated iliac aneurysm or those with branched or fenestrated endoprostheses were excluded from analysis.

### Preoperative medical imaging

All patients were evaluated using spiral computed tomography angiography (CTA) prior to EVAR. All imaging examinations were performed on a multislice CT scanner (General Electric Medical Systems, Milwaukee, Wisconsin, LightSpeed16). Parameters for the acquisitions were 1.25mm slice thickness, 120kVp, and 215-360mA tube current. Imaging was initiated after administering 120mL of low-osmolar iodinated contrast agent (Hexabrix, iodine concentration 320mg/ml). Soft tissue window settings with a width of 400HU and a center of 40HU were applied. At the aortic neck, diameters were measured at the subrenal aorta (D1a), 15mm below the lowest renal artery (D1b), origin of the aneurysm (D1c), as well as the greatest diameter of the aneurysm (DAAA) (Fig 1). At the iliac artery level, the diameters were taken at the origin (Da), middle (Db), and bifurcation (Dc). For patients in whom the end of the endograft did not correspond with the iliac bifurcation, a landmark was positioned and then recorded on the preoperative CT, to ensure that the diameter Dc would be measured at exactly the same position.

### Intervention

The diameters of the implanted prosthesis conformed to the manufacturers' instructions with  $16\pm 9\%$  oversizing at the aortic neck and  $8\pm 7\%$  at the iliac arteries. An aorto-bi-iliac endoprosthesis was implanted (54 patients) when the diameter of the aortic bifurcation permitted; in all other cases, an aorto-uni-iliac device with a femorofemoral crossover bypass

was used (seven patients). The proximal extremity of the endoprosthesis was implanted close to the renal arteries and its distal extremity as close to the iliac bifurcation as possible. Different endoprostheses were used: 31 (51%) Talent Medtronic (World Medical/Medtronic, Sunrise, FL, U.S.A), 23 (38%) Zenith Cook (William Cook Europe, Bjaeverskow, Denmark), 6 (10%) Excluder Gore-Tex (WL Gore and Associates, Flagstaff, AZ, U.S.A), and one (1%) Anaconda Sulzer-Vascutek (Edinburgh, U.K).

### Follow-up

For the purpose of this study, CT scans taken prior to the intervention, at 1 month, and at last follow-up were analyzed. The control scans followed the same procedure as the preoperative scans, but in addition to the acquisition at the arterial phase, another at 60 seconds was obtained in order to visualize late-phase, low-flow endoleaks. For the control scans, all preoperative diameters were taken again, and where applicable, endoleaks noted and migration length measured. In total, 61 proximal necks and 115 iliac arteries were analyzed.

### CT analysis

All pre- and post-operative imaging was analyzed using the dedicated program, Endosize (Therenva<sup>©</sup>), which had previously been validated by our department (Fig.2)<sup>7</sup>. All diameters were measured perpendicularly to the central line, from adventitia to adventitia, by the same person.

### Statistical analysis

Statistical analysis was performed with SAS statistical software V9.2 (SAS Institute, Cary, NC, USA). Data are presented as means $\pm$ SD for quantitative variable unless otherwise noted, and as numbers with corresponding percentages for qualitative variables. Evolution with time of mean aorto-iliac measures was analyzed by use of a one-way ANOVA with preoperative

CT scan taken as baseline values. Separate analyses according to the type of endoprotheses were also performed. Correlations between growths of different aortic and iliac measurements, and between growth of aortic neck and baseline characteristics, were calculated by use of the Spearman correlation coefficient. Subgroup analyses were performed between patients with aortic aneurysm regression >10% (group A) and those without (group B). Comparisons of the evolution with time of mean aorto-iliac measures between the two subgroups were performed by use of a two-way (time, group) ANOVA. For each of the different endoprotheses, the evolution of each diameter was analyzed using the Kruskal-Wallis and the Mann-Whitney test. The cumulative proportion of patients with a proximal neck evolution greater than 20% was assessed by means of a Kaplan-Meier analysis. For all analyses, a P value < 0.05 was considered to be significant.

## **RESULTS**

### **Demographics**

The general characteristics of the patients included in the study are shown in table 1. The main risk factor in our patients was the coronary risk.

### **Type 1 endoleaks and secondary interventions**

In our population, one patient (1.6%) with a distal endoleak was treated using iliac extension because he had presented a 5mm progression of the anchor zone with a secondary retraction at the bifurcation level, with a common iliac artery measuring 16mm prior to the intervention without associated iliac aneurysm. Another patient (1.6%) with proximal endoleak was treated using an aortic cuff because he had presented a 10mm migration (endoprosthesis Talent, Medtronic) with a moderate neck dilatation (3mm) but a 5mm aneurysmal growth.



## Aortic neck

The three diameters taken at the proximal neck increased over time (Fig.3, Table 2), with a mean increase of  $3.7\pm 2.8$ mm for D1a,  $4.4\pm 2.5$ mm for D1b, and  $4.4\pm 3.1$  mm for D1c. This increase was homogeneous across the three levels as there was a significant correlation between the three levels, with  $P=0.001$  between D1a and D1b,  $P<0.0001$  between D1a and D1c, and  $P<0.0001$  between D1b and D1c (Fig.4). The increase in the proximal neck appeared to be more marked at the level closest to the aneurysm than at the level of the renal arteries (Table 2). When the first month post-implant CT scan was taken as a reference, the observed dilatation of the aortic neck was also significant: D1a increased by  $8.0\pm 7.8\%$  ( $P<0.0001$ ),  $10\pm 8.7\%$  for D1b ( $P<0.0001$ ), and  $10\pm 8.9\%$  for D1c ( $P<0.0001$ ). The percentage of patients with an increase in aortic neck diameter greater than 20% was 11.5% for D1a, 13.1% for D1b and 14.8% for D1c (Fig. 5). No baseline risk factor was found to be correlated with an aortic neck evolution greater than 20%.

## Iliac arteries

The three iliac artery diameters significantly increased over time (Fig.6, Table 2), with a mean increase of  $2.1\pm 0.2$ mm for Da,  $2.5\pm 0.5$ mm for Db, and  $3\pm 0.7$ mm for Dc. Similarly, the dilatation homogeneously affected the iliac artery as significant correlations were found between the three levels, with  $P<0.0001$  between Da and Db (Fig.7),  $P=0.004$  between Da and Dc, and  $P=0.001$  between Db and Dc. The increase at the level of the iliac arteries was distally more marked than at its origin (Table 2). When the first month post-implant CT scan was taken as a reference, the observed dilatation of the iliac artery was still significant for all diameters: Da increased by  $6\pm 10\%$  ( $P<0.0001$ ),  $8\pm 11\%$  for Db ( $P<0.0001$ ), and  $12\pm 13\%$  for Dc ( $P<0.0001$ ). The percentage of patients with an increase in iliac artery diameter greater than 20% was 11.4% for D1a, 17.2% for D1b and 19.0% for D1c.

### Correlation between aortic neck and iliac arteries

The increase in the three measurements at the proximal neck was compared with that observed at the iliac artery level (Fig.8, Table 3). No significant correlation was found between the diameter increase at the proximal level and that at the iliac artery level, with the exception of D1b and Dc ( $P=0.006$ ), which showed a weak correlation ( $r=0.363$ ).

### Correlation between neck dilatation and baseline characteristics

Only D1a and Dc diameters, on which the choice of endoprosthesis diameter was based, were found to be correlated with the oversizing. A significant but weak correlation was observed between the progression of D1a and the oversizing ( $r=0.296$ ,  $P=0.023$ ), and between the evolution of Dc and the oversizing ( $r=0.279$ ,  $P=0.004$ ). No correlation was found between the evolution of D1a and the preoperative neck diameter ( $P=0.242$ ), or the preoperative AAA sac size ( $P=0.71$ ).

### Subgroups analysis

In Group A ( $n=35$ ), a significant increase ( $P<0.001$ ) in all diameters was observed over time at both the proximal neck and iliac artery necks (Fig. 9 and 10), which was also the case for Group B ( $n=26$ ) ( $P<0.001$ ). When comparing the two groups, the increase was statistically more marked in Group B for all diameters with the exception of the iliac bifurcation diameter. Separate analysis of each type of endoprosthesis showed a significant difference at the aortic neck (Fig. 11) for the three diameters ( $P=0.023$  for D1a,  $P=0.021$  for D1b and  $P=0.004$  for D1c). Although no difference was noted between the Talent and Zenith devices ( $P=0.164$ ), there was a moderate difference between the Talent and Excluder devices ( $P=0.022$ ), and between the Zenith and Excluder devices ( $P=0.042$ ). At the iliac artery, no difference was noted between the endoprostheses ( $P=0.15$  for Da,  $P=0.917$  and  $P=0.319$  for Dc).

## DISCUSSION

Currently, scarce data is available regarding the long-term progression of distal necks following EVAR, whereas proximal necks have been extensively investigated in a number of studies<sup>3,4,8-9</sup>. However, most studies conducted to date used different methodologies, and differing results were observed. Badran *et al.*<sup>4</sup> took the measurements 7.5mm below the lowest renal artery using axial slices; therefore, in cases of iliac tortuosities, the diameter taken on the image was smaller. We believe that this measuring method is not accurate, due to an obvious parallax error, which cannot only be corrected by taking into account the smallest diameter. For this reason, we measured all diameters perpendicular to the central line, which is a reproducible<sup>10</sup> and well-accepted method. In the study of Badran *et al.*<sup>4</sup>, neck dilatation during the first 2 years of follow-up was possibly linked to oversizing, after which, in their opinion, further progression of parietal wall degeneration may come into play. Napoli *et al.*<sup>8</sup> found no correlation between the suprarenal and infrarenal necks, while showing that neck dilatation affected only 33% of the patients following EVAR. In contrast to this, our results indicate that dilatation affects all patients, which is in line with the observation of Monahan *et al.*<sup>11</sup>. Soberon *et al.*<sup>3</sup> considered that dilation due to oversizing occurred mainly at 6 months. Cao *et al.*<sup>12</sup> identified the following factors predictive of neck dilatation: presence of circumferential thrombus, preoperative neck diameter, and maximal AAA diameter. With respect to this last parameter, the study by Dillavou *et al.*<sup>9</sup> showed that the dilatation of the neck was just as marked as the preoperative diameter was small (cut-off 25 mm). In our study, the dilatation of the proximal neck seemed to homogeneously affect the entire area rather than just the zone immediately below the renal arteries. This is, in theory, the reference diameter used to calculate the implemented prosthesis, and thus oversizing. Thus, the progression of diameters D1b and D1c cannot be accounted for by oversizing. The heterogeneity of the nature of various aneurysm neck dilatation (AND) studies has been widely highlighted by

Diehm *et al*<sup>13</sup>, explain the origin of the highly variable results reported for AND. In order to harmonize the clinical and morphologic outcomes following EVAR, the Society of Vascular Surgery and the International Society of Vascular Surgery have published reporting standards<sup>14</sup>, recommending the use of the first set of postoperative images. We thus compared the first and last CT scan measurements, in addition to the ANOVA analysis. In both cases, the dilatation of the necks was significant. To characterize AND, assessment of the full proximal landing zone is necessary<sup>13</sup>. It is therefore recommended to use the AAA neck volumetry for the assessment of AND<sup>15</sup>. Although the Endosize software has not been designed to perform volumetric analyses of AAA, its algorithm could be used for this purpose. We thus measured three different diameters, along the full proximal neck (and the iliac artery). In our study, these diameters were shown to increase significantly over time, the increase being more marked in the proximal zones of the aneurysm, as shown in Fig. 5. From a physiological point of view, this kind of progression may point to a gradual extension of the aneurysmal disease. This hypothesis was partially demonstrated by Diehm *et al*<sup>16</sup>, by means of a histological and biochemical analysis. They determined in “seemingly non-diseased infrarenal AAA neck” a number of histological signs of destruction and biochemical disorders, which could explain the appearance of AND. This explanation would also apply to patients presenting an aneurysm growth over time. Nevertheless, dilatation of the proximal neck also affected patients exhibiting aneurysmal regressions, as shown by the results of subgroup analyses. Therefore, while the difference between both groups was significant, more relevant was the fact that in patients with aneurysm retraction on imaging, neck dilatation could still be evidenced at all levels, suggesting that EVAR settles the mechanical<sup>17</sup>, but not the biological aspects of AAA. In our series, there were not enough cases of proximal endoleaks to draw any conclusions as to a potential correlation between both parameters, especially since migrations may also lead to endoleaks, independently from the dilatation of

the proximal neck, as shown in our own series. In line with this observation, Monahan *et al.*<sup>11</sup> concluded that the dilatation of the proximal neck was not correlated to Type I endoleaks or migrations.

Scientific literature on distal necks is rather scarce. For conventional AAA surgery, the question has already been raised as to whether associated ectatic iliac arteries should be treated simultaneously. In the retrospective study of Sala *et al.*<sup>18</sup>, the authors proposed to treat routinely all patients with ectatic common iliac arteries larger than 18mm and a life-expectancy of at least 7-8 years. Regarding endovascular AAA treatment, several studies have attempted to demonstrate that patients with ectatic iliac arteries at the distal anchor zone could be treated efficiently without further postoperative complications by using either the bell bottom<sup>19</sup> or standard endoprosthesis<sup>20</sup>, without loss of the hypogastric artery<sup>21</sup>. However, in the medium-term, Mc Donnell *et al.*<sup>22</sup> found a 7% rate of distal endoleaks in patients with iliac arteries larger than 16mm. It should further be mentioned that only a few articles reported exclusively the evolution of normal and pathological iliac arteries over time. Falkensammer *et al.*<sup>5</sup> showed that dilatation of the distal anchor zone, while present in all patients, was more marked in patients with concomitant iliac aneurysm, but was not associated with an increased rate of endoleaks or reinterventions<sup>23,24</sup>, which is in contradiction with the findings of other studies<sup>25,26</sup>. In addition, Adiseshiah *et al.*<sup>27</sup> highlighted that long-term follow-up of these areas was critical, as aneurysmal evolution was more likely to occur later in time in distal necks than in proximal necks.

Our study yielded similar results, showing a significant increase over time in iliac artery measurements at the three levels. Similarly to the proximal neck, there appears to be a progression in all iliac artery diameters in patients presenting aneurysmal regression. This trend, however, has to be put into perspective because, even if the analysis revealed a statistically significant progression, a clinical correlation could not be established due to the

insufficient number of distal endoleaks. As for the proximal neck, it may be assumed that the parietal degeneration process is likely to extend to the iliac arteries progressively. However, the correlation analysis revealed that diameter progressions of the distal and proximal necks were an independent phenomenon and the increase at the level of the iliac arteries was distally more marked than at its origin. A tentative explanation of these findings is based on alterations in parietal hemodynamic constraints due to the endoprosthesis. In fact, the increase in pressure was shown to be more marked at the level of the iliac bifurcation than at the proximal neck<sup>28, 29</sup>, and this difference was more pronounced when the vessels were long and tortuous<sup>30</sup>. Likewise, wall shear stress was shown to be more relevant at areas of overlap<sup>28</sup>, as well as in the kinking zones of the endoprosthesis. It seems likely that the presence of the endoprosthesis, in addition to decreasing pressure in the aneurysmal sac, also alters the constraints at the level of the iliac arteries with a more significant stress and pressure as compared to the preoperative period. It should be noted, however, that this hemodynamic modification alone is not sufficient to explain the results we observed with respect to iliac artery dilatation.

The evolution with each endoprosthesis appears to be similar in our study. There was a difference at the aortic neck only with the Excluder device, suggesting that AND is related to supra or infra-renal fixation<sup>31</sup>. Nevertheless, in our study the number of patients treated with the Excluder device is too small to draw any conclusions on the effects of supra or infra-renal fixation. No difference was found between the Talent and Zenith devices, and in both cases there was a dilatation at the aortic neck, in agreement with the findings of Badger *et al*<sup>32</sup>.

Overall, our results show a trend towards a neck dilatation incidence rate, which is greater than that observed by other authors. Concerning the level of accuracy of the measurements, the observed differences, which are only slightly greater, sometimes by only one or two millimeters (to be compared with the aortic diameters, which ranged from 10 to 30 mm), are

sufficient to affect the results of a statistical test. Although we used a 3D reconstruction based on the use of spiral CT images, intra- or inter-observer variabilities could lead to difficulties, especially with measurements requiring an accuracy of one millimeter. As most of the studies investigating AND or iliac evolution do not make use of software with an automated centerline extraction, we expected that by using the Endosize software, this type of variability would be reduced. In order to reduce the measurement errors related to image quality, we included only those patients of whom high quality images had been recorded in our hospital. This was important, since the same acquisition parameters, in particular the slice thickness, are not always used in other establishments. Moreover, Wever *et al*<sup>33</sup> also showed that, for all patients, the proximal neck demonstrates continued dilatation during follow-up, with a median increase of 15.5% (cross-sectional area) at 12 months.

Our study was directly focused on the final status of necks without taking into account intermediary scans except for the immediate postoperative scan. Our aim was not to investigate the kinetics of progression but rather the potential correlations between the progressions in the different anchor zones of the endoprosthesis. In spite of the retrospective nature of the study design, this trend towards dilatation, which was even observed in successfully-treated patients, is a new finding that must be taken into account as it raises the question as to the modifications of native arteries caused by the endoprosthesis itself. Presently, not enough time has passed, and there have been too few clinical events to allow us to understand whether there is an implication on the occurrence of distal endoleaks and aneurysms on the landing zones. This highlights the need for a sufficiently long follow-up for recovered patients (young patients). To confirm these results, further long-term studies are needed in this patient population.

No competing interest declared

## REFERENCES

1. Investigators UKET, Greenhalgh RM, Brown LC, Powell JT, Thompson SG, Epstein D, et al. Endovascular versus open repair of abdominal aortic aneurysm. *N Engl J Med* 2010;362:1863-71.
2. Investigators UKET, Greenhalgh RM, Brown LC, Powell JT, Thompson SG, Epstein D. Endovascular repair of aortic aneurysm in patients physically ineligible for open repair. *N Engl J Med* 2010;362:1872-80.
3. Soberón AB, de Garcia MM, Möll GG, Vigil BR, Krauel MA, Alvarez-Sala Walter R. Follow-up of aneurysm neck diameter after endovascular repair of abdominal aortic aneurysms. *Ann Vasc Surg* 2008;22:559-63.
4. Badran MF, Gould DA, Raza I, McWilliams RG, Brown O, Harris PL, et al. Aneurysm neck diameter after endovascular repair of abdominal aortic aneurysms. *J Vasc Interv Radiol* 2002;13:887-92.
5. Falkensammer J, Hakaim AG, Andrew Oldenburg W, Neuhauser B, Paz-Fumagalli R, McKinney JM, et al. Natural history of the iliac arteries after endovascular abdominal aortic aneurysm repair and suitability of ectatic iliac arteries as a distal sealing zone. *J Endovasc Ther* 2007;14:619-24.
6. Long A, Perez-Niddam K, Maisonneuve H. Abdominal aortic aneurysm repair treated with endoprosthesis: technical and economic evaluation by ANAES (National Agency of Health Accreditation and Evaluation). *J Mal Vasc* 2000;25:263-9
7. Kaladji A, Lucas A, Kervio G, Haigron P, Cardon A. Sizing for endovascular aneurysm repair: clinical evaluation of a new automated three-dimensional software. *Ann Vasc Surg* 2010;24:912-20.
8. Napoli V, Sardella SG, Bargellini I, Petrucci P, Cioni R, Vignali C, et al. Evaluation of



the proximal aortic neck enlargement following endovascular repair of abdominal aortic aneurysm: 3-years experience. *Eur Radiol* 2003;13:1962-71.

9. Dillavou ED, Muluk S, Makaroun MS. Is neck dilatation after endovascular aneurysm repair graft dependent? Results of 4 US Phase II trials. *Vasc Endovascular Surg* 2005;39:47-54.
10. Velazquez OC, Woo EY, Carpenter JP, Golden MA, Barker CF, Fairman RM. Decreased use of iliac extensions and reduced graft junctions with software-assisted centerline measurements in selection of endograft components for endovascular aneurysm repair. *J Vasc. Surg* 2004;40:222-7.
11. Monhan TS, Chuter TAM, Reilly LM, Rapp JH, Hiramoto JS. Long-term follow-up of neck expansion after endovascular aortic aneurysm repair. *J Vasc Surg* 2010;52:303-7
12. Cao P, Verzini F, Parlani G, Rango PD, Parente B, Giordano G, et al. Predictive factors and clinical consequences of proximal aortic neck dilatation in 230 patients undergoing abdominal aorta aneurysm repair with self-expandable stent-grafts. *J Vasc Surg* 2003;37:1200-05.
13. Diehm N, Dick F, Katzen BT, Schmidli J, Kalka C, Baumgartner I. Aortic neck dilatation after endovascular abdominal aortic aneurysm repair : A word of caution. *J Vasc Surg* 2008;47:886-92
14. Chaikof EL, Blankensteijn JD, Harris PL, White GH, Zarins CK, Bernhard VM, et al. Reporting standards for endovascular aortic aneurysm repair. *J Vasc Surg* 2002;35:1048-60
15. Diehm N, Kickuth R, Gahl B, Do DD, Schmidli J, Rattunde H, et al. Intraobserver and interobserver variability of 64-row computed tomography abdominal aortic aneurysm neck measurements. *J Vasc Surg* 2007;45:263-8
16. Diehm N, Di Santo S, Schaffner T, Schmidli J, Völzmann J, Jüni P, et al. Severe structural

damage of the seemingly non-diseased infrarenal aortic aneurysm neck. *J Vasc Surg* 2008;48:425-34

17. Diehm N, Dick F, Katzen BT, Do DD, Baumgartner I. Endovascular repair of abdominal aortic aneurysms: Only a mechanical solution to a biological problem? *J Endovasc Ther* 2009;16(Suppl 1):119-26
18. Sala F, Hassen-Khodja R, Branchereau P, Berthet J, Batt M, Mary H, et al. Outcome of common iliac arteries after aortoaortic graft placement during elective repair of infrarenal abdominal aortic aneurysms. *J Vasc Surg* 2002;36:982-7.
19. Karch LA, Hodgson KJ, Mattos MA, Bohannon WT, Ramsey DE, McLafferty RB. Management of ectatic, nonaneurysmal iliac arteries during endoluminal aortic aneurysm repair. *J Vasc Surg* 2001;33:33-38.
20. Timaran CH, Lipsitz EC, Veith FJ, Chuter T, Greenberg RK, Ohki T, et al. Endovascular aortic aneurysm repair with the Zenith endograft in patients with ectatic iliac arteries. *Ann Vasc Surg* 2005;19:161-6.
21. England A, Butterfield JS, McCollum CN, Ashleigh RJ. Endovascular aortic aneurysm repair with the Talent stent-graft: outcomes in patients with large iliac arteries. *Cardiovasc Intervent Radiol* 2008;31:723-7.
22. McDonnell CO, Semmens JB, Allen YB, Jansen SJ, Brooks DM, Lawrence-Brown MMD. Large iliac arteries: a high-risk group for endovascular aortic aneurysm repair. *J Endovasc Ther* 2007;14:625-9.
23. Parlani G, Zannetti S, Verzini F, De Rango P, Carlini G, Lenti M, et al. Does the presence of an iliac aneurysm affect outcome of endoluminal AAA repair? An analysis of 336 cases. *Eur J Vasc Endovasc Surg* 2002;24:134-8.
24. Kirkwood ML, Saunders A, Jackson BM, Wang GJ, Fairman RM, Woo EY. Aneurysmal iliac arteries do not portend future iliac aneurysmal enlargement after endovascular

aneurysm repair for abdominal aortic aneurysm. *J Vasc Surg* 2010; Available from: <http://www.ncbi.nlm.nih.gov/pubmed/21030200>

25. Albertini J, Favre J, Bouziane Z, Haase C, Nourrissat G, Barral X. Aneurysmal extension to the iliac bifurcation increases the risk of complications and secondary procedures after endovascular repair of abdominal aortic aneurysms. *Ann Vasc Surg* 2010;24:663-9.
26. Hobo R, Sybrandy JEM, Harris PL, Buth J. Endovascular repair of abdominal aortic aneurysms with concomitant common iliac artery aneurysm: outcome analysis of the EUROSTAR Experience. *J Endovasc Ther* 2008;15:12-22.
27. Adiseshiah M, Boardley D, Raphael MJ. Late iliac artery aneurysm formation: implications for the lower landing site after EVAR. *J Endovasc Ther* 2008;15:246-7.
28. Molony DS, Callanan A, Kavanagh EG, Walsh MT, McGloughlin TM. Fluid-structure interaction of a patient-specific abdominal aortic aneurysm treated with an endovascular stent-graft. *Biomed Eng Online* 2009;8:24.
29. Figueroa CA, Taylor CA, Yeh V, Chiou AJ, Zarins CK. Effect of curvature on displacement forces acting on aortic endografts: a 3-dimensional computational analysis. *J Endovasc Ther* 2009;16:284-94.
30. Frauenfelder T, Lotfey M, Boehm T, Wildermuth S. Computational fluid dynamics: hemodynamic changes in abdominal aortic aneurysm after stent-graft implantation. *Cardiovasc Intervent Radiol* 2006;29:613-23.
31. Leurs LJ, Stultiëns G, Kievit J, Buth J, EUROSTAR collaborators. Adverse events at the aneurysmal neck identified at follow-up after endovascular abdominal aortic aneurysm repair: how do they correlate? *Vasc* 2005;13:261-7
32. Badger SA, O'Donnell ME, Loan W, Hannon RJ, Lau LL, Lee B et al. No difference in medium-term outcome between Zenith and Talent stent-grafts in endovascular aneurysm repair. *Vasc Endovasc Surg* 2007;41:500-5

33. Wever JJ, de Nie AJ, Blankensteijn JD, Broeders IAMJ, Mali WPTHM, Eikelboom BC.

Dilatation of the proximal neck of infrarenal aortic aneurysms after endovascular AAA repair. *Eur J Vasc Endovasc Surg* 2000;19:197-201

## TABLES

Table 1. Demographic and clinical characteristics of the patients

	Total Population (n=61)
Age (years; mean $\pm$ SD)	74,6 $\pm$ 8,3
Obesity (BMI>30)	8 (13,1%)
Coronary artery lesions	26 (42,6%)
Coronary artery by pass graft	10 (16,4%)
Aortic valve replacement	3 (4,9%)
Critical limb ischemia	2 (3,3%)
Severe respiratory insufficiency	2 (3,3%)
End-stage renal failure	1 (1,6%)
Poorly-controlled dyslipidemia	13 (21,3%)
Poorly-controlled arterial hypertension	5 (8,2%)
Active smoker	8 (13,1%)
Diabetes	5 (8,2%)

Table 2. Aortic measures. Mean  $\pm$  standard deviation (range) and P value from ANOVA analysis.

Diameter	Preoperative	1 month	Last follow-up	Growth	P value
D1a (n=61)	23.9 $\pm$ 3.3 (17; 26)	25.6 $\pm$ 4 (19; 43)	27.6 $\pm$ 4.6(20; 48	3.7 $\pm$ 2.8(-2; 12)	0.018
D1b (n=56)	24.3 $\pm$ 3.9 (18; 38)	26.3 $\pm$ 4.1 (20; 43)	28.7 $\pm$ 4.3(22; 44	4.4 $\pm$ 2.5(-1; 12)	0.0156
D1c (n=61)	25 $\pm$ 4 (18; 35)	27 $\pm$ 4.4 (20; 46)	29.4 $\pm$ 4.3(21; 41	4.4 $\pm$ 3.1(-3; 12)	0.0358
Da (n=115)	16.4 $\pm$ 3.6 (11; 30)	18 $\pm$ 4 (13; 39)	18.5 $\pm$ 3.3(11; 33	2.1 $\pm$ 0.2(2; 3)	0.0006
Db (n=115)	16.9 $\pm$ 5.2 (11; 48)	18,8 $\pm$ 5 (12; 51)	19.4 $\pm$ 4.8(10; 53	2.5 $\pm$ 0.5(1-3)	0.0005
Dc (n=115)	16.2 $\pm$ 4.2 (9; 48)	18.5 $\pm$ 4.6 (12; 53)	19.2 $\pm$ 3.6(11; 32	3 $\pm$ 0.7(1; 4)	0.0007
DAAA (n=61)	55 $\pm$ 7.7 (42; 83)	54.5 $\pm$ 7 (40; 74)	49 $\pm$ 12.6 (20;	- 6 $\pm$ 11(-34; 14)	

Table 3. Correlation between proximal aortic neck growth and iliac growth. Spearman coefficient (r) and P value.

Diameters	D1a	D1b	D1c
Da	r=0.086	r=0.095	r=0.221
	P=0.515	P=0.489	P=0.09
Db	r=0.051	r=0.231	r=0.237
	P=0.699	P=0.09	P=0.068
Dc	r=0.213	r=0.363	r=0.214
	P=0.102	P=0.006	P=0.101

**FIGURES**

Fig 1. Aortoiliac measurements

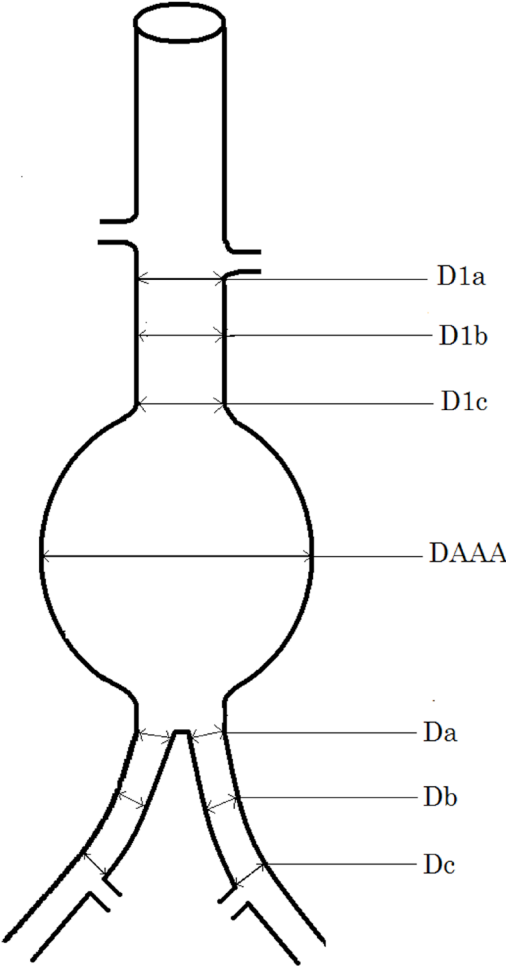


Fig 2. CTA analysis (Endosize, Therenva<sup>®</sup>). Outer-to-outer diameters were measured perpendicularly to the center-line

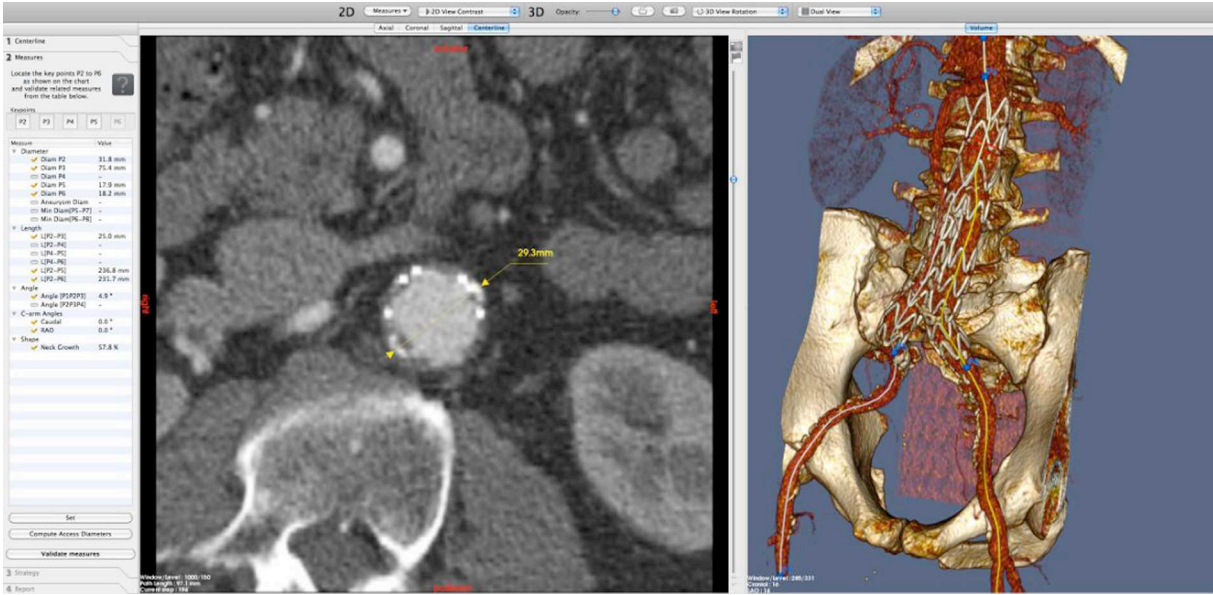


Fig 3. Evolution of diameters of the proximal aortic neck

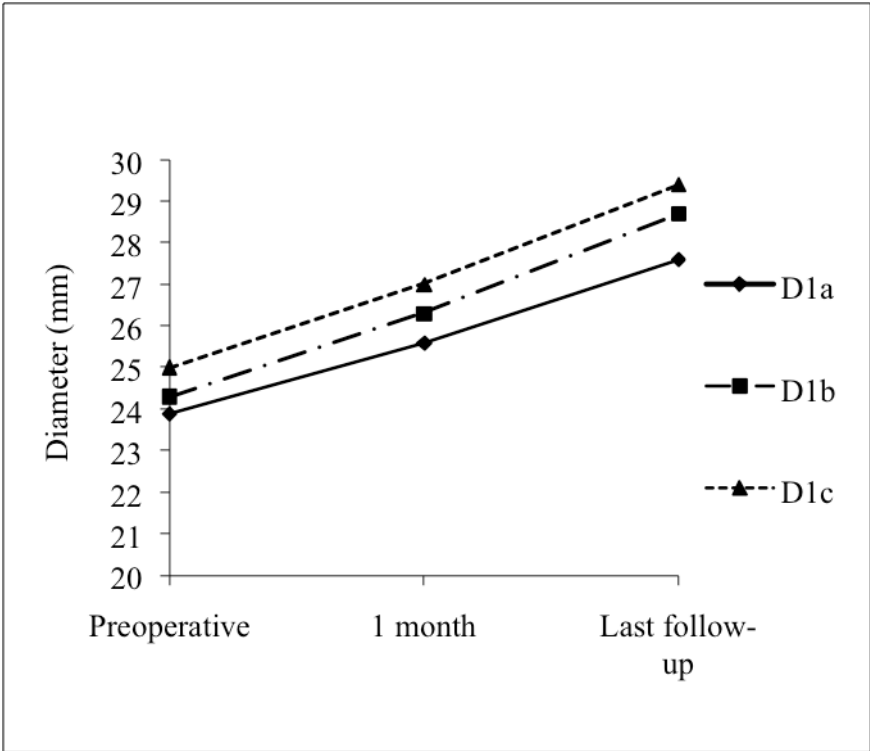




Fig 4. Correlation between growth of D1b and D1c (aortic neck)

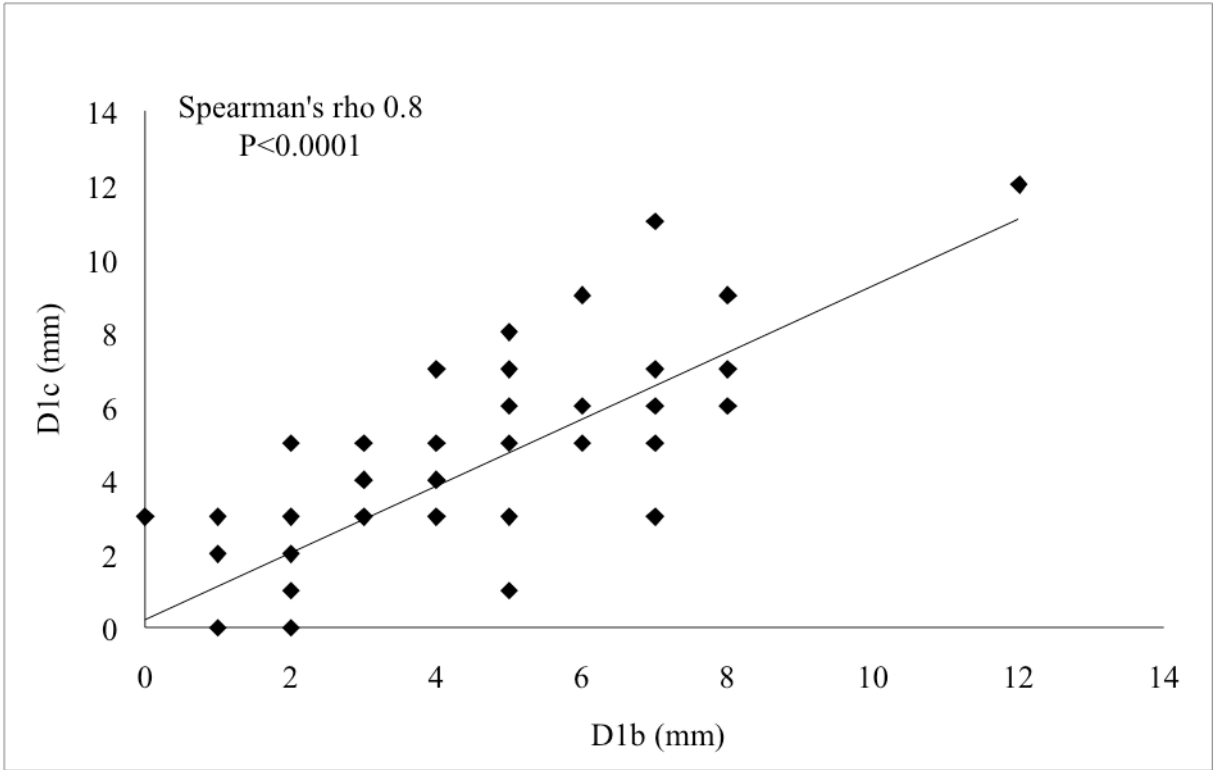


Fig 5. Cumulative proportion of patients with a proximal neck evolution greater than 20%

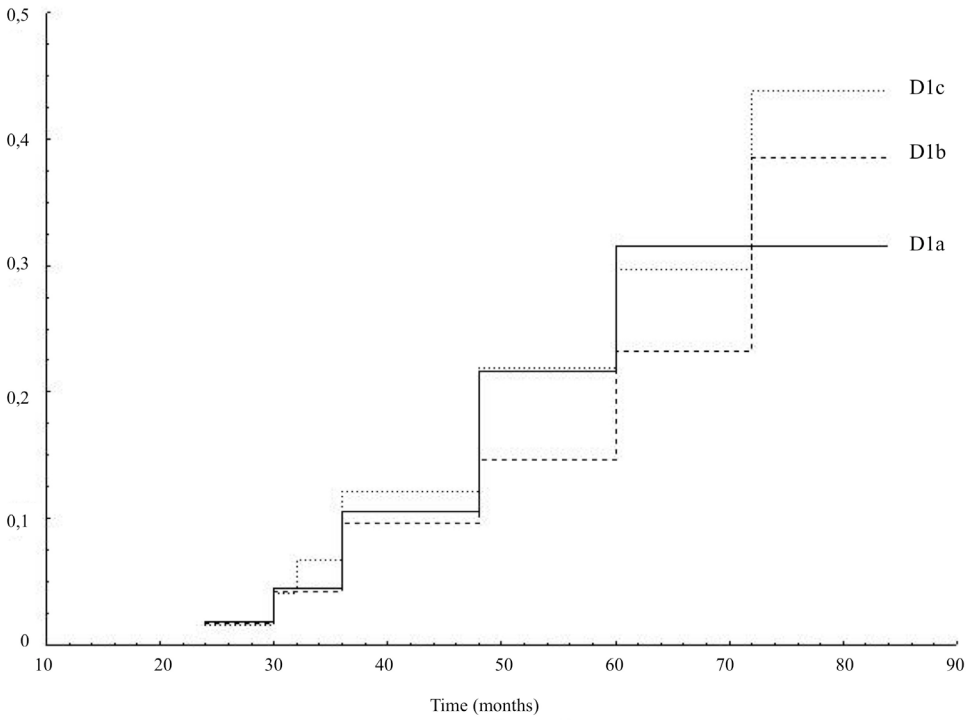


Fig 6. Evolution of distal landing site diameters

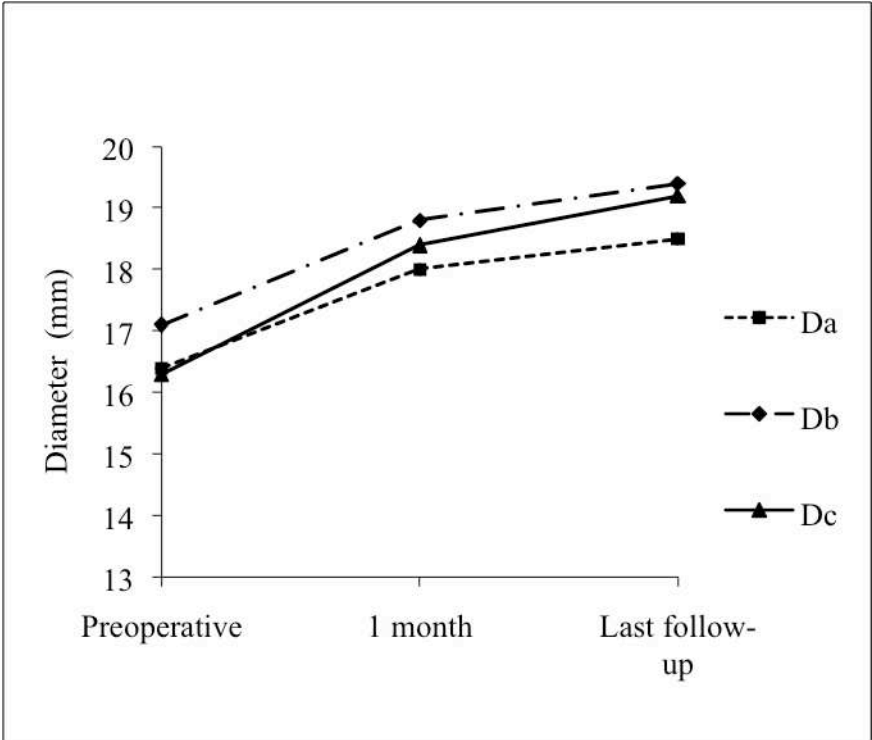


Fig 7. Correlation between growth of Da and Db (iliac arteries)

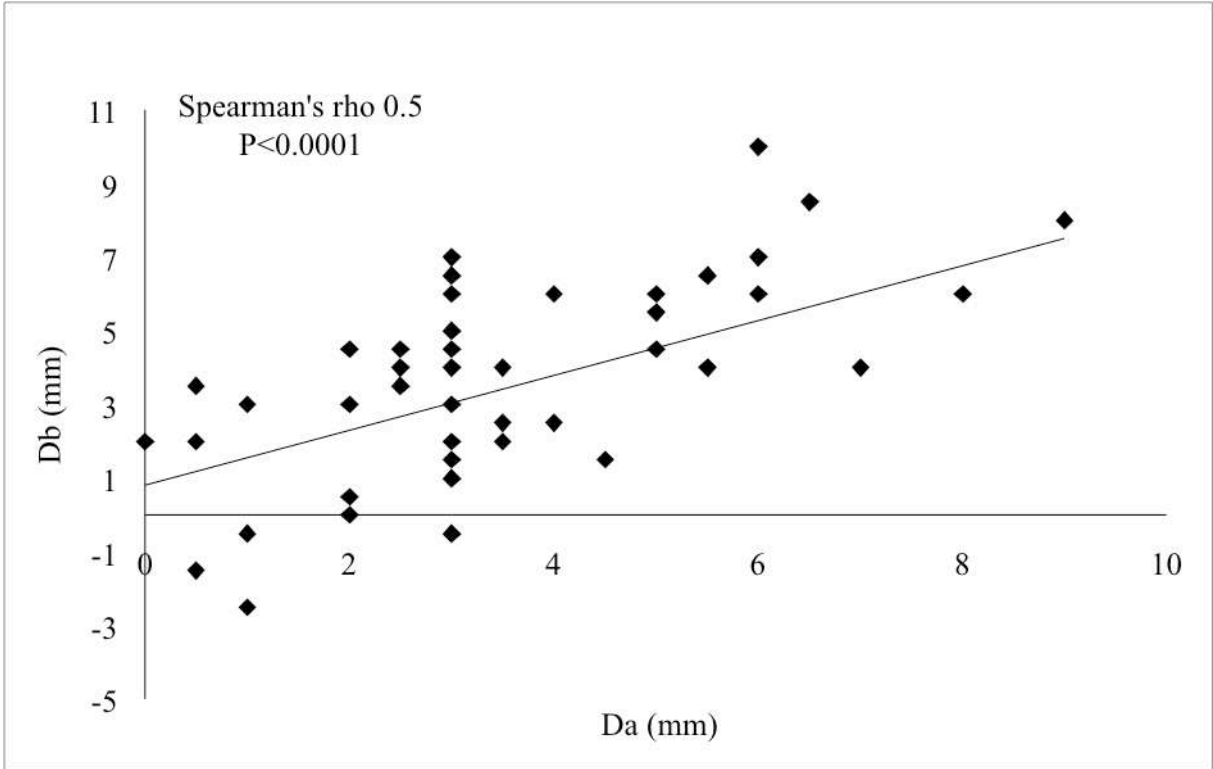


Fig 8. Correlation between growth of D1b and Da

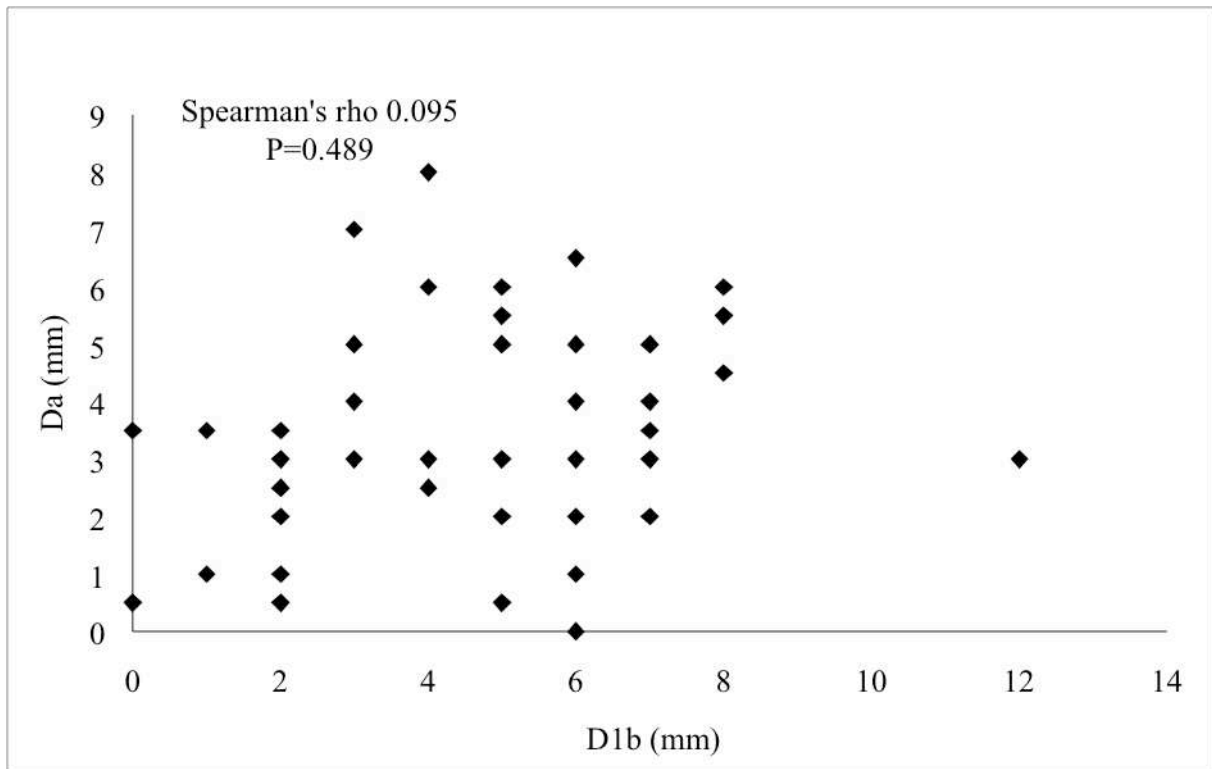


Fig 9. Proximal neck: mean±standard deviation at each time point (T0: preoperative; T1: 1 month; Tx: last follow-up) for Group A and Group B. The p value for the variables “Group” and “Time” (two-way ANOVA analysis)

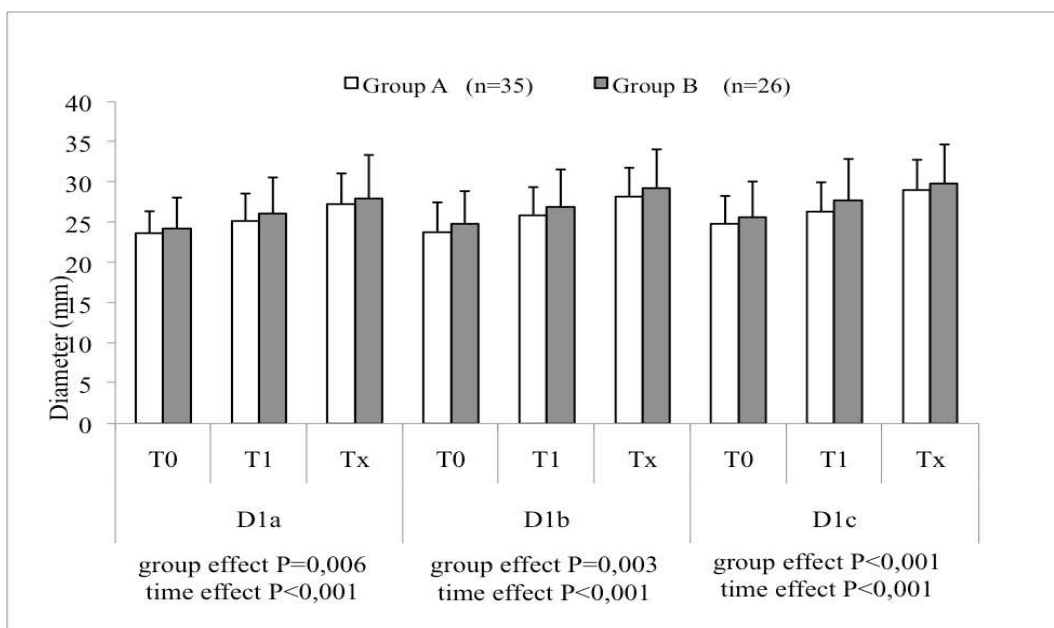


Fig 10. Iliac arteries: mean±standard deviation at each time point (T0: preoperative; T1: 1 month; Tx: last follow-up) for Group A and Group B. The p value for the variables “Group” and “Time” (two-way ANOVA analysis)

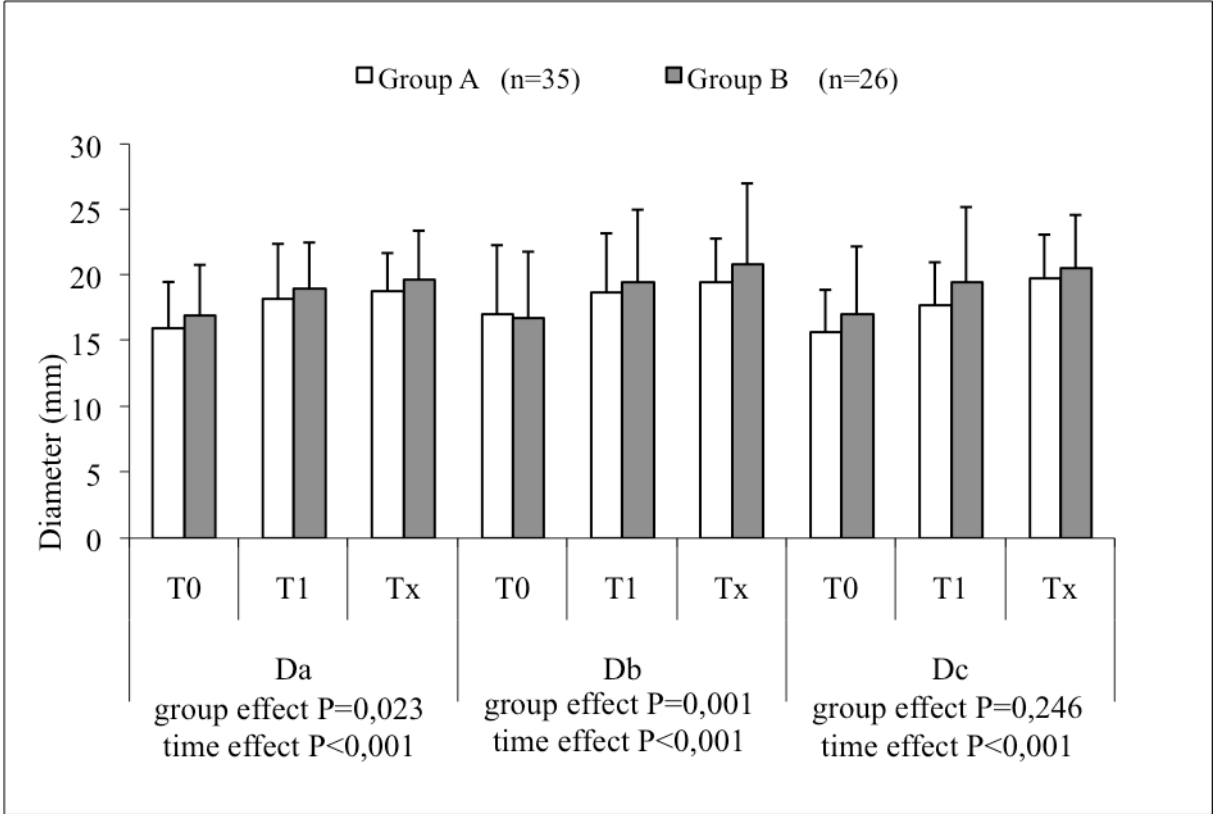


Fig 11. Evolution (percentage) of diameters with respect to each endoprosthesis used

\*P<0,05, \*\*P<0,005

