

Computer-aided surgery: concepts and applications in vascular surgery

Adrien Kaladji^{1,2,3}, Antoine Lucas^{1,2,3}, Alain Cardon¹, Pascal Haigron^{2,3}

(1) CHU Rennes, Vascular surgery unit, F-35033 Rennes, France

(2) INSERM, U642, F-35000 Rennes, France

(3) University Rennes 1, Signal and Image Processing Laboratory (LTSI), F-35000
Rennes, France

ABSTRACT

Computer-aided surgery makes use of a variety of technologies and information sources. The challenge over the last ten years has been to apply these methods to tissues that deform, as do vessels when relatively rigid flexible objects are introduced into them (Lunderquist rigid guidewire, aortic prosthesis, etc.) Three stages of computer-aided endovascular surgery are examined: sizing, planning and intra-operative assistance. Our work shows that an approach based on optimized use of the imaging data acquired during the various observation phases (pre and intra-operative), involving only lightweight computer equipment that is relatively transparent for the user, makes it possible to provide useful (i.e. necessary and sufficient) information at the appropriate moment, in order to aid decision-making and enhance the security of endovascular procedures.

INTRODUCTION

Computer-aided surgery (Fig.1) is a discipline based on a variety of technologies and information sources^{1,2} : Medical imaging, pre- or intra-operative (CT scan, MRI, ultrasonography, coelioscopic imaging)³; micro-technologies, used both for action (micro-instruments) and observation (micro-sensors)⁴; virtual reality⁵ and augmented reality⁶, in particular interactive simulation and the possibility of enriching reality, as perceived by the user, with data or pre-processed models; medical robotics⁷ used in master-slave mode and which is now being applied to new fields, in particular that of robot-controlled catheterization⁸.

Computer-assisted surgery tools were first developed for use in orthopaedics and neurosurgery. These were applications using rigid tools in the presence of tissues that were also, in the first place, rigid or supposedly so (organs encapsulated in bony structures). The challenge over the last ten years has been to apply these methods to tissues that deform, as do vessels when relatively rigid flexible objects are introduced into them (Lunderquist rigid guidewire, aortic prosthesis, etc.).

Progress in medical imaging is often seen as synonymous with high capital investment in equipment derived from technological research. We present here three applications in regular clinical use that are essentially the result of research into signal and image processing and algorithm development, requiring relatively little investment in hardware (CT scan, interventional MRI, sophisticated robotics). Three stages of computer-aided endovascular surgery are examined: sizing, planning and intra-operative assistance.

Sizing. Pre-operative sizing, particularly in tricky locations (supra-aortic trunks), and whether for an aortic stent or a stenotic lesion, necessitates a perfect description of the lesion and measurements that will lead to the choice of the most appropriate device.

In practice the surgeon is faced with the use of viewers that are generally not well suited to this type of task. He calls the help of a radiologist or uses a lightweight imaging console that represents a significant financial investment. He may also use non-specific devices made available free of charge, all of which are equivalent to a slimmed-down, multi-purpose radiology console. Sometimes the vascular surgeon may delegate sizing to product specialists working for the manufacturer of the device.

The aim of our works was to develop a tool, running on a simple portable computer, enabling the surgeon to perform sizing himself by automating the thresholding, centre-line detection and sizing functions⁹. The software should not be time-consuming, enabling sizing to be carried out with seven clicks and without a previous experience of imaging workstations for the user. It is a decision-making tool that is action-oriented (placement of a thoracic or abdominal endoprosthesis or an endo valve, or stenting of arterial stenosis).

The software developed by THERENVA (Fig.2) provides feasibility alarms (diameter of iliac arteries, sinuosity, angle of neck). This makes it possible to optimize ordering of available devices through a link to the manufacturer's catalogue. This tool was validated by an analysis of thirty-two patients and comparison with the measurements made by an endovascular radiologist using a General Electric Advanced Vessel Analysis system; in this study there was no significant difference between the sizing determined by the radiologist and that obtained by the surgeon on EndoSize in an average time of fifteen minutes (10 to 40 min. range)¹⁰.

Planning is also fully automated (Fig.3) and concerns three essential functions:

Pre-operative choice of operational viewing incidences, so as to limit injections of contrast medium and radiation doses in intra-operative fluoroscopy¹¹. Depending on the existence of

partnerships with the suppliers of operating-room imaging systems, this function can be associated with automatic steering of a motor-driven C-arm.

Preparation for endovascular navigation in lesions to which access is complex, particularly at carotid and supra-aortic level. This planning can be performed visually using virtual angiography¹², i.e. virtual exploratory navigation through pre-operative imaging, and/or be based on explicit study of interactions between the endovascular material and tissue^{13,14}. This implies that the mechanical behaviour of the material used has been modelled, that full CT images of the aortic arch and the supra-aortic vessels have been acquired pre-operatively, and that the material has been computer-tested to predict its behaviour (length, torque, whip). Industrial development of this application is limited first by the need to obtain the mechanical parameters of the guidewires and catheters on the market (industrially sensitive data that manufacturers are legitimately reluctant to reveal), and also by the considerable workload involved in creating material data-bases for a somewhat limited number of users.

Training, for which the application described above turns out to be an excellent tool. Surgeons are of course familiar with catheterization simulators, but generally speaking the latter do not allow quick and easy testing of endovascular tools with the data of the actual patients to be treated. Catheterization simulation with integration of the pre-operative CT-scan of a planned patient would make it possible not only to optimize device selection but also to test the material and train oneself quickly to use the new tools that are becoming available on the market with ever-greater frequency.

Intra-operative aid. It is paradoxical to note that very precise information is available pre-operatively thanks to CT-scan, with visualization of complete lesions, aneurysm or stenosis, detection of the presence of thrombus or calcification, and measurement capability, while intra-operatively, only subtraction images are available, with a notable loss of parietal information with the current c-arms. This intra-operative 2D imaging, in the absence of rotational capability, exposes the surgeon to errors (most frequently parallax error), faulty interpretation of sinuous vessels, and leads to a search for the

best angle of incidence involving repeated injections of contrast medium and additional doses of radiation.

Intra-operative imaging thus provides relatively little information compared to pre- or post-operative imaging. A certain number of complications – endoleaks, malpositioning, covering of renal or internal iliac arteries – result from sizing errors, failure to anticipate deformations, or faulty intra-operative positioning.

The assistance tool^{15,16} developed by the INSERM team and THERENVA was tested experimentally by Rennes CHU and was awarded first prize in the AGBM 2008 Innovative Medical Technologies competition.

The device consists of an assistance console (figure 4) which, after an automated registration procedure, enables the surgeon not only to perform the intervention in the usual way using the scope screen but also to monitor the progression of the inserted device through the 3D-space derived from the pre-operative CT-scan. This registration and image implantation correspond perfectly to the definition of augmented reality. Everything takes place in real time, allowing surgeons to benefit from a genuine instrument panel on which they can see: progression under fluoroscopy, progression through the large-scale 3D reconstruction of the aneurysm or the supra-aortic vessels and CT-scan slices corresponding to the position of the device. Information concerning the vessel wall is then visible: thrombus, calcification. This tool thus enables full localization to be performed using a single angle of incidence, and it is backed up by an alarm system based on the pre-operative sizing that alerts the operator in the event of deviation from the pre-established operating plan. Clinical evaluation is currently under way on ten aortic endoprostheses and four carotid angioplasties; it shows that device placement (endoprosthesis or stent) is optimized, with greater security; there is less use of fluoroscopy to look for different angles of view; and less contrast medium is injected.

The remaining technical problem concerns deformations. Introduction of an extrastiff guidewire or an aortic stentgraft naturally makes arteries, and in particular the iliac arteries, straighten and deform. Flexion/extension movements of the neck during carotid angioplasty can also modify the tortuosity of

the common or internal carotid arteries. Pre-operative planning based on the pre-operative CT-scan may thus turn out to not match the intra-operative morphology¹⁷. To solve this problem, the aortoiliac deformations during EVAR have been modelled using finite element simulation. This model is based on patient specific geometry from the preoperative CT-scan and is still assessed on a large cohort to represent various anatomies. According to this model imaging fusion, including the deformations of the aortoiliac structure, between preoperative CT and intraoperative fluoroscopy with a standard c-arm could be feasible.

CONCLUSION

Computer-aided vascular surgery is a newly-emerging practice. Our work shows that an approach based on optimized use of the imaging data acquired during the various observation phases (pre- and intra-operative), involving only lightweight computer equipment that is relatively transparent for the user, makes it possible to provide useful (i.e. necessary and sufficient) information at the appropriate moment in order to aid decision-making. These software solutions can be integrated into a standard operating room, and all the more easily into a hybrid high-tech installation.

In the long term, the addition of data derived from 2D or 3D intra-operative ultrasound, an intra-corporeal magnetic localizer or interventional MRI, coupled with adequate pre-operative sizing and planning taking into account possible future deformations should enable us to reach our intended goal, i.e. endovascular surgery with limited use of X-rays and with an already-available angio-navigation station at the heart of this merging of data.

Acknowledgments

This article is based on research that was partially funded the French national research agency (ANR) through the Tecsan program (project ANGIOVISION n°ANR-09-TECS-003)

REFERENCES

1. Lavallée S , Cinquin P, Troccaz J. Editor: Roux C , Coatrieux JL Computer Integrated Surgery and Therapy: State of the Art. Contemporary Perspectives in Three-Dimensional Biomedical Imaging. chapter 10: IOS Press; Amsterdam 1997; 239- 310.
2. Galloway R.L. The process and development of image-guided procedures. Annual Review of Biomedical Engineering, 2001; 3(1) :83-108.
3. Peters TM, Image Guidance for Surgical Procedures. Physics in Medicine and Biology. 2006; 51: (14) 505- 540.
4. Haignon P, Luo L, Coatrieux JL. Issues in image-guided therapy. IEEE Eng. Med. Biol. Mag. 2009; 28(4):96-8.
5. Fuchs P. and Moreau G. Le Traité de la réalité virtuelle. Les Presses de l'Ecole des Mines de Paris, deuxième édition, 2003.
6. Eggers G., Salb T., Hoppe H., Kahrs L., Ghanai S., Sudra G., Raczowsky J., Dillmann R., Worn H., Hassfeld S. and Marmulla R. Intraoperative augmented reality : the surgeons view. Stud Health Technol Inform, 2005; (111):123-5.
7. Taylor R, Stoianovici D, Medical robotics in computer-integrated surgery. IEEE Trans Robotics and Automation. 19: (5) 2003; 765- 781
8. Servatius H, Steven D, Rostock T, Hoffman B, Drewitz I, Müllerleile K, Aydin M, Meinertz T Willems S. Robotic Navigation Minimizes the X-ray Exposure in Pulmonary Vein Isolation: A Randomized Comparison with the Conventional Approach. *Heart Rhythm* 2009; 6(5): S341.

9. Acosta O, Göksu G, Lucas A, Kulik C, Rolland Y, Haigron P. Geometrical description of anatomical structures based on virtual exploratory navigation. *Surgetica*; 2005; Sauramps Medical, 2005. p.437-45.
10. Kaladji A, Lucas A, Kervio G, Haigron P, Cardon A. Sizing for endovascular aneurysm repair: clinical evaluation of a new automated three-dimensional software. *Ann Vasc Surg*. 2010 Oct;24(7):912-20.
11. Goksu G, Haigron P, Zhang H, Soulas T, Le Certen G, Lucas A. 3D intraoperative localization for endovascular navigation guidance. *Surgetica'2002, Computer-aided medical interventions: tools and applications*: Sauramps Medical; 2002. p. 323-9.
12. Haigron P, Bellemare ME, Acosta O, Goksu C, Kulik C, Rioual K, Lucas A. Depth-map-based scene analysis for active navigation in virtual angioscopy. *IEEE Transactions on Medical Imaging*. 2004;23(11):1380-90.
13. Guilloux V, Haigron P, Göksu C, Kulik C, Lucas A. Simulation of guide-wire navigation in complex vascular structures. *Proceedings of SPIE Medical Imaging 2006:Visualization, Image-Guided Procedures, and Display*; 2006; San Diego, USA: SPIE, Bellingham, WA; 2006. 6141(07):1-11.
14. Pelerin J.L, Kulik C., Goksu C., Coatrieux J.L, Rochette M., Fluid-structure interaction applied to the simulation of Abdominal Aortic Aneurysms, *Proceedings International IEEE Engineering In Medicine and Biology Conference*, New York, August 2006.
15. Haigron P., Lucas A. Method for assisting and guiding the navigation of a tool in anatomical structures. *Brevet FR 02/04898*. Université de Rennes 1. 2002.
16. Goksu C, Haigron P, Acosta O, Lucas A. Endovascular navigation based on real/virtual environments cooperation for computer assisted TEAM procedures. *Proceedings of SPIE Medical Imaging 2004:Visualization, Image-Guided Procedures, and Display*; 2004; San Diego, USA: SPIE, Bellingham, WA; 2004. p. 257-66.

17. Carrell TW, Modarai B, Brown JR, Penney GP. Feasibility and limitations of an automated 2D-3D rigid image registration system for complex endovascular aortic procedures. *J Endovasc Ther.* 2010 Aug;17(4):527-33.

FIGURES

Fig. 1 Computer Aided Surgery (CAS)

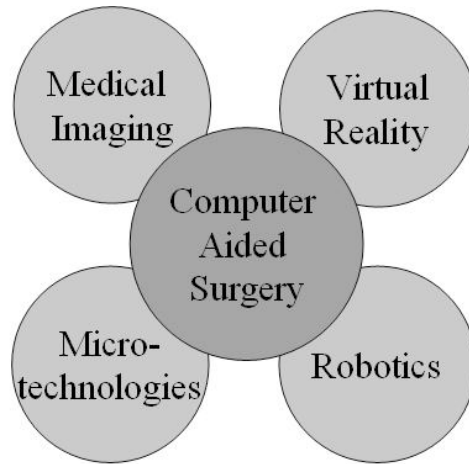


Fig.2 EndoSize intuitive sizing tool

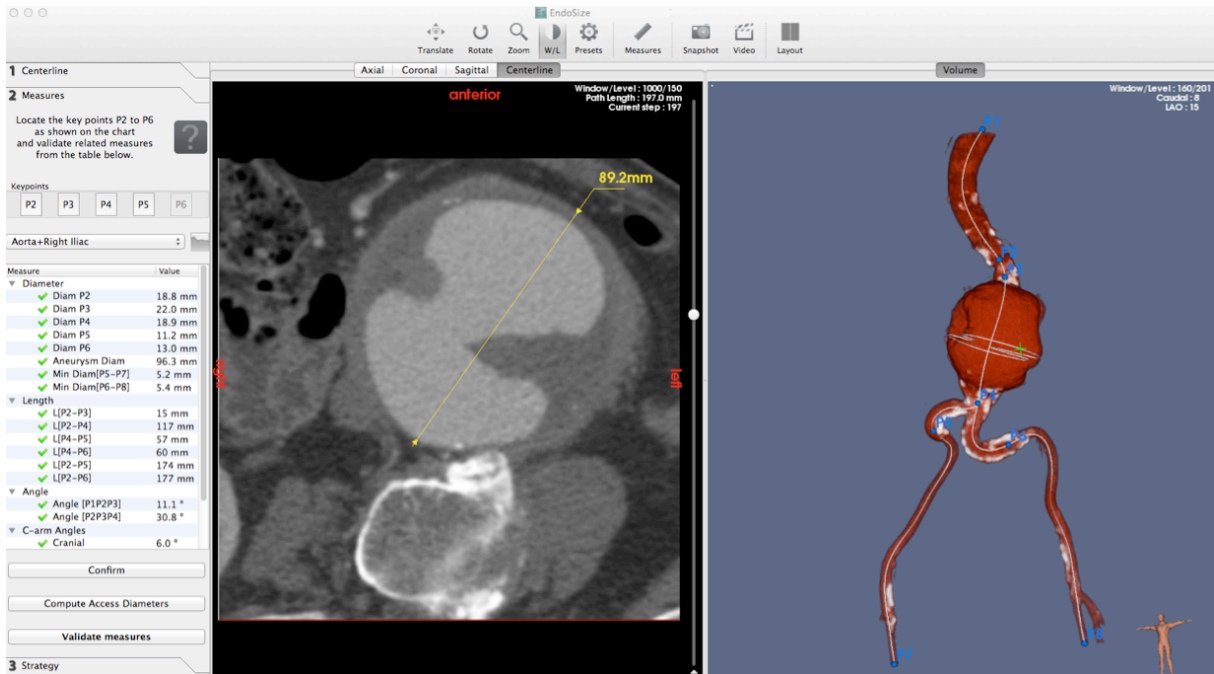


Fig. 3 Planning: choice of angles of incidence and preparation for catheterization




Fig. 4 EndoNaut augmented reality device

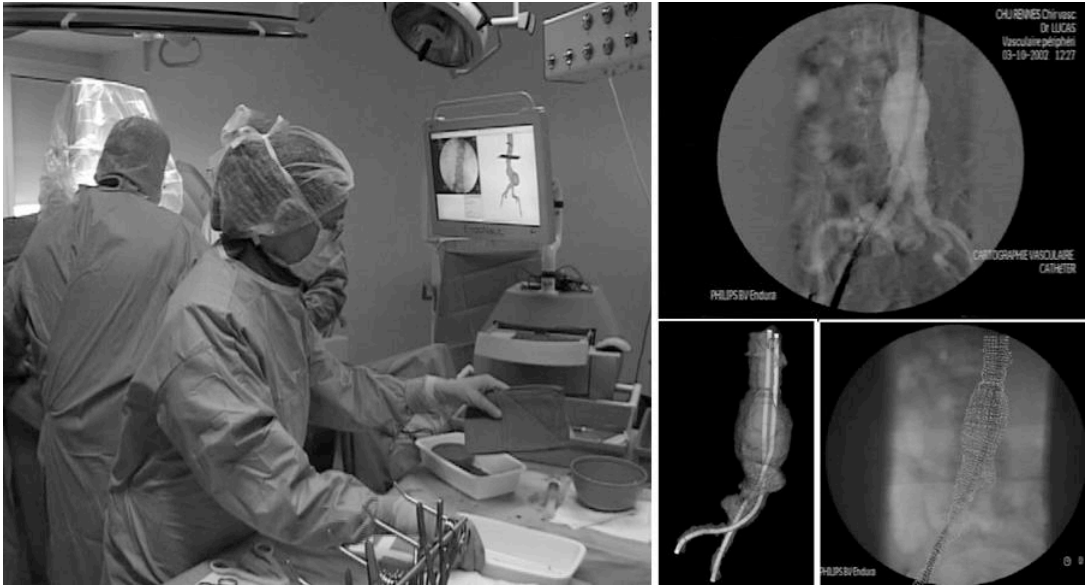

Fig. 5 Simulation of deformations of the aortoiliac structure by an extrastiff guidewire. In blue the non deformed aortoiliac structure, in red the deformed structure.

