



## **Autism multiplex family with 16p11.2p12.2 microduplication syndrome in monozygotic twins and distal 16p11.2 deletion in their brother.**

Anne-Claude Tabet, Marion Pilorge, Richard Delorme, Frédérique Amsellem, Jean-Marc Pinard, Marion Leboyer, Alain Verloes, Brigitte Benzacken, Catalina Betancur

### **► To cite this version:**

Anne-Claude Tabet, Marion Pilorge, Richard Delorme, Frédérique Amsellem, Jean-Marc Pinard, et al.. Autism multiplex family with 16p11.2p12.2 microduplication syndrome in monozygotic twins and distal 16p11.2 deletion in their brother.. European Journal of Human Genetics, 2012, 20 (5), pp.540-6. 10.1038/ejhg.2011.244 . inserm-00661857

**HAL Id: inserm-00661857**

**<https://inserm.hal.science/inserm-00661857>**

Submitted on 20 Jul 2012

**HAL** is a multi-disciplinary open access archive for the deposit and dissemination of scientific research documents, whether they are published or not. The documents may come from teaching and research institutions in France or abroad, or from public or private research centers.

L'archive ouverte pluridisciplinaire **HAL**, est destinée au dépôt et à la diffusion de documents scientifiques de niveau recherche, publiés ou non, émanant des établissements d'enseignement et de recherche français ou étrangers, des laboratoires publics ou privés.



## Autism multiplex family with 16p11.2p12.2 microduplication syndrome in monozygotic twins and distal 16p11.2 deletion in their brother

Anne-Claude Tabet<sup>1,2,3,4</sup>, Marion Pilorge<sup>2,3,4</sup>, Richard Delorme<sup>5,6</sup>, Frédérique Amsellem<sup>5,6</sup>, Jean-Marc Pinard<sup>7</sup>, Marion Leboyer<sup>6,8,9</sup>, Alain Verloes<sup>10</sup>, Brigitte Benzacken<sup>1,11,12</sup>, Catalina Betancur<sup>2,3,4</sup>

<sup>1</sup> AP-HP, Robert Debré Hospital, Department of Genetics, Cytogenetics Unit, Paris, France

<sup>2</sup> Inserm U952, Paris, France

<sup>3</sup> CNRS UMR 7224, Paris, France

<sup>4</sup> UPMC Univ Paris 06, Paris, France

<sup>5</sup> AP-HP, Robert Debré Hospital, Department of Child and Adolescent Psychiatry, Paris, France

<sup>6</sup> INSERM U955, Institut Mondor de Recherche Biomédicale, Psychiatric Genetics, Créteil, France

<sup>7</sup> AP-HP, Raymond Poincaré Hospital, Pediatric Neurology Unit, Garches, France

<sup>8</sup> AP-HP, Henri Mondor-Albert Chenevier Hospital, Department of Psychiatry, Créteil, France

<sup>9</sup> University Paris-Est Créteil, Faculty of Medicine, Créteil, France

<sup>10</sup> AP-HP, Robert Debré Hospital, Department of Genetics, Clinical Unit, Paris, France

<sup>11</sup> Inserm U676, Paris, France

<sup>12</sup> AP-HP, Jean Verdier Hospital, Cytogenetics Unit, Bondy, France

Running title: Duplication 16p11.2p12.2 in twins with autism

Corresponding author: C. Betancur, INSERM U952, Université Pierre et Marie Curie, 9 quai Saint Bernard, 75005 Paris, France. Tel: +33 1 44 27 61 19; fax: +33 1 44 27 60 69; e-mail: Catalina.Betancur@inserm.fr

### ABSTRACT

The pericentromeric region of chromosome 16p is rich in segmental duplications that predispose to rearrangements through non-allelic homologous recombination. Several recurrent copy number variations have been described recently in chromosome 16p. 16p11.2 rearrangements (29.5-30.1 Mb) are associated with autism, intellectual disability and other neurodevelopmental disorders. Another recognizable but less common microdeletion syndrome in 16p11.2p12.2 (21.4 to 28.5-30.1 Mb) has been described in six individuals with intellectual disability, while apparently reciprocal duplications, studied by standard cytogenetic and FISH techniques, have been reported in three patients with autism spectrum disorders. Here we report a multiplex family with three boys affected with autism, including two monozygotic twins carrying a *de novo* 16p11.2p12.2 duplication of 8.95 Mb (21.28-30.23 Mb) characterized by SNP array, encompassing both the 16p11.2 and 16p11.2p12.2 regions. The twins exhibited autism, severe intellectual disability, and dysmorphic features, including a triangular face, deep-set eyes, large and prominent nasal bridge, and tall, slender build. The eldest brother presented with autism, mild intellectual disability, early onset obesity and normal craniofacial features, and carried a smaller, overlapping 16p11.2 microdeletion of 847 kb (28.40-29.25 Mb), inherited from his apparently healthy father. Recurrent deletions in this region encompassing the *SH2B1* gene were recently reported in early onset obesity and in individuals with neurodevelopmental disorders, associated with phenotypic variability. We discuss the clinical and genetic implications of two different 16p chromosomal rearrangements in this family, and suggest that the 16p11.2 deletion in the father predisposed to the formation of the duplication in his twin children.

**Kew words:** duplication 16p11.2p12.2, deletion 16p11.2, autism, intellectual disability, *SH2B1*, SNP array

## INTRODUCTION

Autism spectrum disorders (ASD) are neurodevelopmental disorders characterized by impairments in social communication and by restricted and stereotyped behaviors and interests, with an onset in the first three years of life and a sex ratio heavily skewed towards males (4:1). ASD are etiologically heterogeneous<sup>1</sup>. About 10%-20% of individuals have an identified genetic etiology, including chromosomal rearrangements, Mendelian disorders (e.g. fragile X syndrome, tuberous sclerosis, Rett syndrome), rare mutations in synaptic genes (e.g. *NLGN4X*, *SHANK3*, *SHANK2*), and copy number variations (CNVs). Microscopically visible chromosomal aberrations are observed in about 5% of individuals with autism<sup>2</sup>. The most frequent cytogenetic abnormality is maternal duplication 15q11q13; other recurrent abnormalities include deletions of 2q37, 22q11.2 and 22q13. Some of these recurrent rearrangements arise through non allelic homologous recombination (NAHR) between paired segmental duplications<sup>3</sup>.

As the short arm of chromosome 16 is rich in intrachromosomal segmental duplications, several microdeletion and microduplication syndromes have been described arising through NAHR. Recurrent ~600 kb deletions and duplications in the 16p11.2 region (29.5-30.1 Mb) are associated with a wide spectrum of neurobehavioral abnormalities, including ASD, intellectual disability (ID), attention deficit hyperactivity disorder (ADHD), seizures and schizophrenia<sup>4-9</sup>. Dysmorphic features and congenital anomalies are also observed frequently<sup>6,7</sup>. In addition, 16p11.2 deletions and duplications increase the risk of obesity and being underweight, respectively<sup>10,11</sup>. Another microdeletion syndrome in 16p11.2p12.2 involving a ~7-9 Mb region (with a common distal breakpoint at 21.4 Mb and proximal breakpoints varying between 28.5 and 30.1 Mb) was identified recently in six patients with common dysmorphic features and developmental delay without autism<sup>12-14</sup>. Three patients carrying a 16p11.2p12.2 duplication had been described earlier<sup>15,16</sup>, but as these cases were studied by standard cytogenetic and fluorescence *in situ* hybridization (FISH) techniques, it is difficult to prove that they are the reciprocal duplication product of the 16p11.2p12.2 microdeletion syndrome. The three patients had ASD and short stature, but only one had ID and dysmorphic features<sup>15,16</sup>. A 16p11.2p12.2 duplication identified prenatally was also reported<sup>17</sup>. Thus, the phenotype of the 16p11.2p12 duplication is not well defined.

Here, we report a multiplex family with three boys with autism, including two monozygotic twins with severe ID and dysmorphic features carrying a *de novo* 16p11.2p12.2 duplication encompassing both the region implicated in the 16p11.2p12 microdeletion syndrome and the 16p11.2 region predisposing to ASD. The eldest brother carried a smaller, overlapping paternally-inherited microdeletion in the distal 16p11.2 region recently involved in early onset obesity<sup>18</sup>. We present the phenotype, cytogenetic and molecular findings in the three patients and discuss the genetic heterogeneity observed in this multiplex family.

## CLINICAL REPORTS

### Patient 1

Patient 1 is a 21-year-old male, the first child of non-consanguineous parents. The father is Caucasian, the mother is from Mauritius. The father declined neuropsychological evaluation but was described by his wife as being non talkative, introverted and having few social relationships. One of his brothers

(among ten sibs) had severe ID with epilepsy; he died at age 42; no further details were available. The maternal personal and family history was negative.

This boy was born at 41 weeks after an uneventful pregnancy; prolonged labor required the use of forceps. Birth weight was 3450 g (44<sup>th</sup> centile), length 51 cm (65<sup>th</sup> centile), and occipitofrontal circumference (OFC) 36 cm (54<sup>th</sup> centile). Apgar scores were 6 and 10 at 1 and 5 min. Early development was normal; he walked at 15 months. He had gastroesophageal reflux and was operated for adenoidectomy and orchidopexy during childhood. The parents reported hyperactivity, motor stereotypies (flapping) and noise intolerance at age 2 years. Speech was severely delayed, with first words at 10 years. At 4 years he was diagnosed with autism based on DSM-IV criteria. He met criteria for autism on the Autism Diagnostic Interview-Revised (ADI-R). (Supplementary Table 1 shows the scores of the behavioral evaluations in the three siblings.) Obesity appeared in childhood; at 7 years 6 months, he was 135 cm tall and weighed 37.6 kg (body mass index [BMI] 20.6, >97<sup>th</sup> centile). He attended a special school where he acquired basic skills in reading and writing. At 16 years, his IQ was 47.

When examined at the age of 19, he was 187 cm tall (+2.5 SD), weighed 91.5 kg (+4 SD) and had an OFC of 58.5 cm (+1.5 SD). He had mild truncular obesity (BMI 26), and some unusual facial features (deep-set eyes, thick supra-orbital ridge with thick eyebrows, wide and prominent nasal bridge, receding chin and everted lower lip), which were difficult to assess considering his mixed ethnic background (Figure 1A). He had extensive acanthosis nigricans, mainly in the neck, axillae, and groin. Neurological examination was normal. His expressive language remained limited to restrictive sentences, mostly dyssyntactic, equivalent to a developmental age of 4 years.

Karyotype, fragile X testing, telomere analysis by multiplex ligation probe amplification (MLPA) and metabolic screening (amino acids, mucopolysaccharides, organic acids, and uric acid) were normal. Brain MRI performed at 5 years was normal. At 12 years, sleep polysomnography to explore difficulties to fall asleep showed temporo-occipital and temporo-parietal hypersynchrony with rapid rhythmic waves, but no significant epileptic event.

## Patient 2

Patient 2 was born at term from a monochorionic, monoamniotic twin pregnancy. Birth weight was 2450 g (4<sup>th</sup> centile), length 47 cm (13<sup>th</sup> centile) and OFC 33 cm (9<sup>th</sup> centile), with Apgar scores of 10 at 1 and 5 min. A small ventricular septal defect was diagnosed in the neonatal period and closed spontaneously. He wore glasses for myopia and strabismus since the first months of life. Recurrent ear, nose, and throat infections required adenoidectomy. Early development was considered normal, with walking at 15 months and first words before age 2. However, verbal communication and social interaction vanished completely in four months after the 26th month. Frequent outbursts and stereotypies such as auditory self-stimulation started at that time. At 3 years of age he was diagnosed with autism, according to DSM-IV criteria. He also met criteria for autism on the ADI-R. His behavioral difficulties made long-term schooling impossible until he was 14 years old, when he entered an inpatient clinic. Additional psychiatric evaluations were conducted at 18 years. The patient remained severely handicapped; he was not fully toilet-trained and required assistance for most basic needs, but was able to feed and dress himself. He was non-verbal, but had acquired basic communication skills using

pictograms. Assessment with the Autism Diagnostic Observation Schedule (ADOS) was difficult because of hyperactivity but confirmed the diagnosis of autism. He was unable to complete the Raven's Colored Progressive Matrices test. The scores on the Vineland Adaptive Behavior Scales II indicated severe to profound ID. Sleep difficulties, hyperactivity and impulsivity were treated with melatonin and risperidone.

When examined at 17 years of age, he was 173 cm tall (mean), weighed 49 kg (-2 SD) and had an OFC of 55 cm (-1 SD). He had a triangular face, with broad forehead and prominent orbital ridge (Figure 1B). The eyebrows were thick on the outer part, with a marked upslant; the eyes were deep set, the palpebral fissures were wide, almond shaped and upslanted and he had alternating strabismus. The nose had a prominent and large bridge, a wide, bulbous tip, and anteverted nares. The philtrum was tented, with a wide philtral groove and a wide cupid's bow, a thin vermilion border and everted lower lip. There was marked overbite and retrognathia despite the presence of a marked chin. The ears were tilted backward. He had a very slender habitus, poor muscle mass in limbs, hypotrophic thenar muscles, cubitus valgus, and mild scoliosis. An asymmetric sternal deformity was noted, with increased Louis angle, bulge of the upper part of the sternum, and depression of the lower part (Figure 1D). He had long fingers and toes, with hypermobile small joints, bilateral single palmar creases and sandal gap. Acanthosis nigricans was present in the neck. Neurological examination was normal, except for absent knee, bicipital and achillean reflexes, and pes cavus, without pyramidal signs. Further evaluations to rule out a peripheral neuropathy could not be performed because of non-compliance.

High-resolution karyotype showed an interstitial duplication on chromosome 16p. Fragile X testing, uric, lactic and pyruvic acid, plasma organic acids and amino acids were all normal except for isolated increase in cysteine in the latter. Brain MRI at 30 months showed white matter hyperintensities with moderate cortical atrophy and thin corpus callosum. An abdominal ultrasound and electroencephalogram were normal.

### Patient 3

The clinical presentation of Patient 3 is very similar to that of his twin brother (Patient 2), but he had no heart defect. His development followed an identical course, with verbal regression at 24 months. His cognitive abilities were also similar (Supplementary Table 1), but his behavior was more problematic, with frequent bouts of self-injurious behavior, clastic crises, and severe sleep disturbances. At 18 years, he was 172 cm tall (mean), weighed 55 kg (-1 SD) and had an OFC of 55 cm (-1 SD). He had dysmorphic features similar to his twin brother (Figure 1C), including the sternum malformation. The results of the karyotype, fragile X, brain MRI and metabolic screening were the same as in his twin brother.

## METHODS

### Cytogenetic analysis and FISH

High-resolution karyotypes were performed on peripheral blood lymphocytes using RHG and GTG banding. FISH using a whole chromosome painting probe for chromosome 16 (Oncor, Gaithersburg, MD, USA) was performed on metaphase spreads of the twins. Bacterial artificial chromosomes (BACs) ADELA-1G01 and APADA-2A01 (Integrigen) were used to confirm the duplication.

### Whole-genome SNP array

Genomic DNA was analyzed with the HumanCNV370-Duo DNA Analysis BeadChip (Illumina, San Diego, CA, USA) containing over 370000 markers, the majority of which are single nucleotide polymorphisms (SNPs). The mean resolution is ~20 kb. SNP copy numbers (log R ratio) and B allele frequencies were assessed using the Illumina BeadStudio software v3.2. CNV analysis was performed using CNV partition v3.1.1 (Illumina) and PennCNV algorithms ([www.openbioinformatics.org](http://www.openbioinformatics.org)). Genomic locations are based on NCBI Build 36 (hg18).

### Real-time qPCR

Quantitative PCR (qPCR) with the Universal Probe Library (Roche, Indianapolis, USA) was used to confirm and map the CNVs, as described previously<sup>19</sup>. Data analysis was performed with the qBase software (<http://medgen.ugent.be/qbase/>).

## RESULTS

High-resolution karyotype (800 bands) in the twins (Patients 2 and 3) showed additional material on the short arm of one chromosome 16. The whole chromosome 16 painting probe completely painted both chromosomes 16, showing that the extra material was from chromosome 16. Parental karyotypes were normal, indicating that the interstitial 16p duplication occurred *de novo*. The karyotype of Patient 1 was also normal. FISH analysis using clones ADELA-1G01 (16p12.1) and APADA-2A01 (16p11.2) in one of the twins (Patient 2) demonstrated a direct tandem duplication and ruled out an inversion in the parents (data not shown).

High-resolution SNP array in Patient 2 confirmed the presence of a ~8.95 Mb duplication at 16p11.2p12.2 flanked by segmental duplications; the minimal and maximal estimated sizes of the duplication are 21282605-30235818 and 21273056-30239704 (Figures 2A and 3). Analysis of genotypes and B allele frequency in the duplicated segment showed that the rearrangement arose on the paternal chromosome. No other rare CNVs were observed in Patient 2 (Supplementary Table 2).

The microarray in the eldest brother (Patient 1) showed a 847 kb microdeletion in 16p11.2 (28401454-29249055) (Figures 2A and 3). The same deletion was present in the father, whereas the mother had a normal profile (Figure 2A). The other CNVs identified in Patient 1 were reported in the Database of Genomic Variants (<http://projects.tcag.ca/variation>) (Supplementary Table 2).

The results of the SNP arrays were confirmed by qPCR (Figure 2B). In Patients 2 and 3, the qPCR confirmed the duplication of *VWA3A* located at 16p12.1, and *NUPR1*, *LAT*, and *ALDOA* located at 16p11.2, with normal dosage of the genes flanking the rearranged region. In Patient 1 and the father, both *NUPR1* and *LAT* were deleted.

## DISCUSSION

### 16p11.2p12.2 rearrangements

We report a family with three children with autism carrying different rearrangements on an overlapping region of chromosome 16p. The monozygotic twins carried a *de novo* 8.95 Mb duplication in 16p11.2p12.2 (21.28-30.23 Mb), encompassing the region associated with the novel 16p11.2p12.2 microdeletion syndrome<sup>12</sup>. The six deletion carriers described so far exhibit similar dysmorphic features,



ID, severe language impairment, short stature, feeding difficulties and recurrent ear infections<sup>12-14</sup>. None was reported to have autism or autistic traits, although only one was assessed formally for ASD<sup>13</sup>. These subjects share a common distal breakpoint around 21.4 Mb, but differ in the proximal breakpoint, ranging from 28.5 to 30.1 Mb<sup>12</sup>.

Our patients are the first with a molecularly characterized 16p11.2p12.2 duplication. Apparently reciprocal duplication of the 16p11.2p12.2 region has been reported in three patients<sup>15,16</sup>, as well as in a fetus diagnosed prenatally<sup>17</sup>; all were studied by standard cytogenetic analysis and FISH. The clinical features of the twins and previously reported patients are summarized in Supplementary Table 3; the only shared feature is ASD. A woman with autism, anxiety disorder and ADHD transmitted the duplication to her daughter, who had ASD and limited language; neither one had ID or dysmorphic features<sup>15,16</sup>. The third case, a male, had a more severe phenotype, with autism, severe ID, epilepsy, and dysmorphic features including hypertelorism, broad nasal bridge and tip, wide mouth, short stature and club feet<sup>16</sup>. In addition, a girl carrying a complex 16p11.2p12.1 rearrangement involving a duplication and triplication had moderate ID, short stature and dysmorphic features with short palpebral fissures, and wide nasal bridge and tip; she was described as friendly and talkative<sup>12</sup>. The twins described here had autism, severe ID and dysmorphic features including deep-set eyes and large nasal bridge and tip. They had recurrent infections during childhood, like the boy described previously<sup>16</sup>. Based on this limited number of patients, duplications of the 16p11.2p12.2 region appear to be associated with a more variable phenotype compared to deletions, with ASD being the only constant feature identified thus far. Other cases of molecularly defined 16p11.2p12.2 duplications are necessary in order to clarify the genotype–phenotype correlation.

The centromeric end of the 16p11.2p12.2 deletion can overlap the 600-kb region in 16p11.2 (29.5–30.1 Mb) associated with autism and other neurodevelopmental disorders<sup>12</sup>. The duplication in the twins also encompassed this 16p11.2 region. Initially reported in up to 1% of patients with ASD, this CNV was shown to occur in 0.3%–0.4% of ASD subjects in two recent large studies<sup>20,21</sup>, and in 0.6% patients submitted for clinical array-CGH<sup>6</sup>. Both the deletion and the duplication are associated with phenotypic heterogeneity, ranging from ASD, ID and/or multiple congenital anomalies, learning and speech problems, to an apparently normal phenotype<sup>6-8,22</sup>, but the deletion seems to be more penetrant compared to the duplication<sup>8</sup>. In addition to cognitive impairment and language deficits, individuals with the 16p11.2 duplication can exhibit motor delay, behavioral problems including ASD, ADHD, aggression or outbursts, schizophrenia, epilepsy, dysmorphic features without a recognizable pattern, and rare congenital anomalies<sup>5-8,23</sup>. Patients with microdeletion are at increased risk for obesity<sup>7,10</sup>, while the duplication is associated with being underweight<sup>11</sup>. In common with other 16p11.2 duplication carriers, the twins had autism, ID, lack of speech, severe behavioral problems with hyperactivity and clastic crises, dysmorphic features, and a tendency to being underweight (–1 to –2 SD). One of the twins had a ventricular septal defect; a microduplication carrier with a similar heart abnormality was reported previously<sup>23</sup>. Other features found in Patients 2 and 3, such as the sternal deformity and the muscular hypotrophy with absent reflexes, suggestive of peripheral neuropathy, have not been described before, either in association with 16p11.2 duplications or the larger 16p11.2p12.2 duplications.

The duplicated segment in the twins encompasses 125 RefSeq genes, including numerous brain-expressed genes with potential roles in neurodevelopment. Increased dosage of one or more genes in

the 16p11.2p12.2 or the 16p11.2 regions could contribute to their phenotype, given that ASD, ID and dysmorphic features have been reported in both.

### ***SH2B1*-containing distal 16p11.2 deletion**

In the eldest brother (Patient 1) the oligonucleotide array revealed a deletion of 847 kb in the 16p11.2 region (28.40-29.25 Mb), inherited from his healthy father. This microdeletion does not overlap the proximal 16p11.2 locus associated with ASD and ID, and encompasses 19 RefSeq genes (Figure 3). Interestingly, deletions in this region were recently implicated in early onset obesity, with a minimal overlapping region of 220 kb (28.73-28.95 Mb)<sup>18</sup> (Figure 3). Patients with longer deletions extending through the 600-kb region associated with ASD/ID exhibited developmental delay in addition to obesity. The 220-kb deletion was also identified in 2 out of 7366 controls. The minimal deleted interval contains 9 genes (Supplementary Table 4), including *SH2B1*, which encodes an adaptor protein involved in leptin and insulin signaling. *Sh2b1* disruption in mice results in obesity and insulin resistance, a phenotype rescued by neuron-specific expression of SH2B1<sup>24</sup>. Patient 1 had childhood obesity, while his father showed a tendency to be overweight, supporting the role of the *SH2B1*-containing region in obesity. However, in contrast to the patients with 16p11.2 deletions reported by Bochukova et al.<sup>18</sup>, who rapidly gained weight in the first years of life and became severely obese, our patient first met criteria for obesity at the age of 7 years (BMI 20.6, >97<sup>th</sup> centile) and when last examined at 19 years, he was mildly overweight, with a BMI of 26 (84<sup>th</sup> centile).

The frequency of the *SH2B1*-containing 220-kb deletion in patients with severe obesity is 0.51% (7/1362)<sup>18</sup>, while the 600-kb 16p11.2 deletion has a frequency of 0.36% in individuals ascertained for obesity (15/4197)<sup>10</sup>. Thus, both CNVs are among the most frequent genetic causes of obesity, after melanocortin-4 receptor (*MC4R*) point mutations.

The *SH2B1*-containing 16p11.2 deletion was recently reported in 31 of 23084 patients with developmental disabilities referred for chromosomal microarray analysis<sup>25</sup>. Only deletions not overlapping the ASD/ID proximal 16p11.2 CNV were included. When compared to published control datasets, where a single 200-kb deletion was identified in 7700 subjects (0.013%), deletions in this region appeared to be significantly enriched in the patient population (0.13%). Among 13 patients in which inheritance was determined, five were *de novo*. Detailed clinical information was only available for six subjects; all had developmental delay of varying severity, two had ASD, three had dysmorphic features and four had BMI ≥95<sup>th</sup> centile. Because the enrichment analysis was performed with control data generated on different microarray platforms with varying sensitivity and specificity, these findings need to be replicated. Future studies, comparing the frequency of 16p11.2 deletions that include the *SH2B1* gene in large samples ascertained for obesity alone, ID/ASD alone or both phenotypes, will help clarify the impact of this CNV in neurodevelopmental disorders.

Additional reports of eleven individuals with overlapping 16p11.2 distal deletions have been published recently (Figure 3), associated with highly variable phenotypes, including developmental delay (n=5), learning difficulties (n=1), behavioral problems such as ASD (n=2) and ADHD (n=1), unusual facial features (n=6), obesity (n=4), diabetes (n=2), seizures (n=1), congenital anomalies of the kidney and urinary tract (n=2), and Hirschsprung disease (n=2)<sup>7,22,26,27</sup>. Three of the deletions were *de*



*nov*o, five paternally inherited and three unknown. Two carrier relatives, a father and a sister, had obesity and diabetes, but were otherwise reportedly healthy<sup>27</sup>.

Of the other eight genes contained in the minimal deleted region, three are involved in autosomal recessive disorders (*TUFM*, *ATP2A*, *CD19*), three are involved in immunity (*NFATC2IP*, *LAT*, *ATXN2L*), *RABEP2* plays a role in membrane trafficking, and little is known about the function of *SPNS1* (Supplementary Table 4). *SH2B1* haploinsufficiency, already implicated in central nervous system-mediated obesity<sup>24</sup>, could also participate in neurodevelopmental and other phenotypes. The widely expressed scaffold protein SH2B1 binds to a variety of ligand-activated receptor tyrosine kinases, including the receptors for nerve growth factor (NGF), insulin and insulin-growth factor 1. SH2B1 facilitates glial-cell-line-derived neurotrophic factor (GDNF)-induced neurite outgrowth through RET receptor signaling<sup>28</sup>. Through its implication in the RET-GDNF signaling pathway, SH2B1 could also play a role in the abnormalities of renal morphogenesis and enteric innervation seen in patients with distal 16p11.2 deletions.<sup>26</sup>

### Potential molecular mechanisms

Most recurrent CNVs described in the short arm of chromosome 16 occur through NAHR<sup>5,12,18</sup>. A NAHR mechanism is also likely to be involved in the rearrangements observed in the present family, as the breakpoints of the 16p11.2p12.2 duplication and the 16p11.2 microdeletion were found to map within segmental duplications with a high degree of sequence identity (see Figure 3 and Supplementary Note). Both the duplication and the deletion are from paternal origin. Analysis of genotypes and B allele frequency indicated that Patients 1 and 2 shared the same paternal allele in the telomeric part of the region encompassing the duplication in the twins, but they inherited different paternal alleles in the region overlapping the deletion and the distal part of the duplication (Supplementary Table 5). This suggests that during meiosis in the father, a crossing over between the two homologous chromosomes 16 occurred distal to the deleted region. Thus, Patient 1 inherited part of the normal allele and part of the deleted allele comprising the deleted region.

We hypothesize that the 16p11.2 deletion in the father might have facilitated the appearance of the duplication in his twin children because of the formation during meiotic pairing of a deletion loop in the normal chromosome 16, together with misalignment of segmental duplications in the same orientation sharing >98% sequence identity (Figure 4 and Supplementary Note). After an intrachromosomal crossing-over within the loop, the recombined allele carried a direct duplication of the segment comprised in the loop. Thus, based on the suggested mechanism, the distal 16p11.2 microdeletion implicated in obesity<sup>18</sup> could contribute to increased risk of rearrangements of the 16p pericentromeric region in the progeny, some of which can result in ASD or other neurodevelopmental disorders, like in the present family. Further cases are needed to confirm this hypothesis.

### Conclusion

This multiplex family highlights the profound genetic heterogeneity underlying autism, including instances of intrafamilial heterogeneity like the one reported here. While the *de novo* 16p11.2p12.2 duplication is the likely cause of ASD, ID and malformations in the twins, the contribution of the paternally-inherited *SH2B1*-containing 16p11.2 deletion to the neurological phenotype of the eldest

brother is unclear at present, and further studies in large samples are needed to enable genotype/phenotype correlations.

## CONFLICT OF INTEREST

The authors declare no conflict of interest.

## ACKNOWLEDGEMENTS

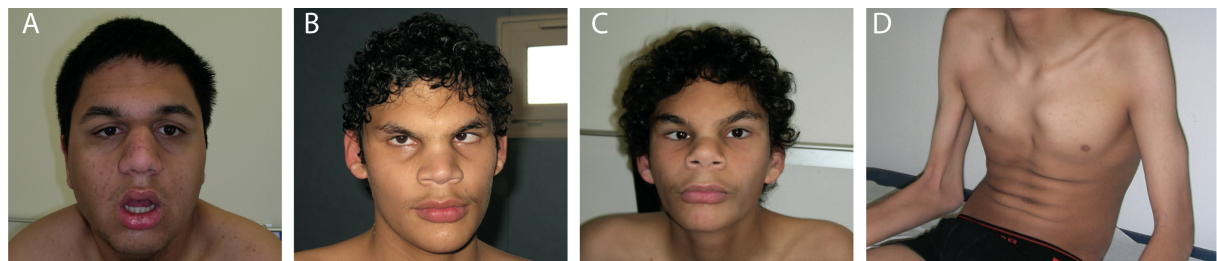We are grateful to the family for participating in this study. This research was supported by Fondation de France, INSERM and by a donation from Mr. Gabriel de Broglie of the Fondation Dehecq-Institut de France. M.P. is supported by a PhD fellowship from the French Ministry of Research.

Supplementary information is available at the *European Journal of Human Genetics* website.

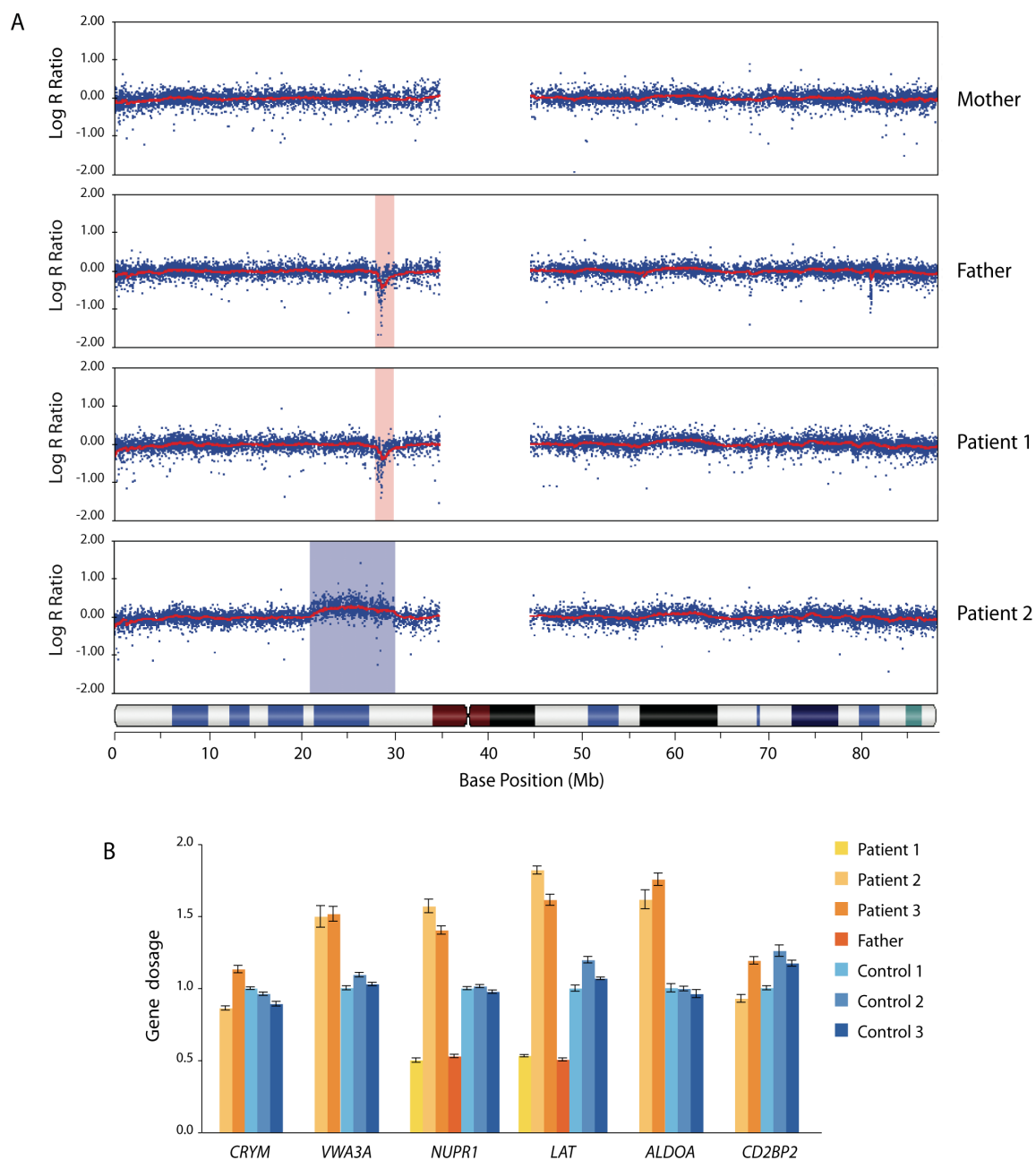
## REFERENCES

1. Betancur C: Etiological heterogeneity in autism spectrum disorders: More than 100 genetic and genomic disorders and still counting. *Brain Res* 2011; **1380**: 42-77.
2. Kielinen M, Rantala H, Timonen E, Linna SL, Moilanen I: Associated medical disorders and disabilities in children with autistic disorder: a population-based study. *Autism* 2004; **8**: 49-60.
3. Lupski JR, Stankiewicz P: Genomic disorders: molecular mechanisms for rearrangements and conveyed phenotypes. *PLoS Genet* 2005; **1**: e49.
4. Kumar RA, KaraMohamed S, Sudi J *et al*: Recurrent 16p11.2 microdeletions in autism. *Hum Mol Genet* 2008; **17**: 628-638.
5. Weiss LA, Shen Y, Korn JM *et al*: Association between microdeletion and microduplication at 16p11.2 and autism. *N Engl J Med* 2008; **358**: 667-675.
6. Shinawi M, Liu P, Kang SH *et al*: Recurrent reciprocal 16p11.2 rearrangements associated with global developmental delay, behavioral problems, dysmorphism, epilepsy, and abnormal head size. *J Med Genet* 2009; **47**: 332-341.
7. Bijlsma EK, Gijsbers AC, Schuurs-Hoeijmakers JH *et al*: Extending the phenotype of recurrent rearrangements of 16p11.2: deletions in mentally retarded patients without autism and in normal individuals. *Eur J Med Genet* 2009; **52**: 77-87.
8. Fernandez BA, Roberts W, Chung B *et al*: Phenotypic spectrum associated with de novo and inherited deletions and duplications at 16p11.2 in individuals ascertained for diagnosis of autism spectrum disorder. *J Med Genet* 2009; **47**: 195-203.
9. McCarthy SE, Makarov V, Kirov G *et al*: Microduplications of 16p11.2 are associated with schizophrenia. *Nat Genet* 2009; **41**: 1223-1227.
10. Walters RG, Jacquemont S, Valsesia A *et al*: A new highly penetrant form of obesity due to deletions on chromosome 16p11.2. *Nature* 2010; **463**: 671-675.
11. Jacquemont S, Reymond A, Zufferey F *et al*: Mirror extreme BMI phenotypes associated with gene dosage at the chromosome 16p11.2 locus. *Nature* 2011; **478**: 97-102.
12. Ballif BC, Hornor SA, Jenkins E *et al*: Discovery of a previously unrecognized microdeletion syndrome of 16p11.2-p12.2. *Nat Genet* 2007; **39**: 1071-1073.
13. Battaglia A, Novelli A, Bernardini L, Igliozzi R, Parrini B: Further characterization of the new microdeletion syndrome of 16p11.2-p12.2. *Am J Med Genet A* 2009; **149A**: 1200-1204.
14. Hempel M, Rivera Bragues N, Wagenstaller J *et al*: Microdeletion syndrome 16p11.2-p12.2: clinical and molecular characterization. *Am J Med Genet A* 2009; **149A**: 2106-2112.

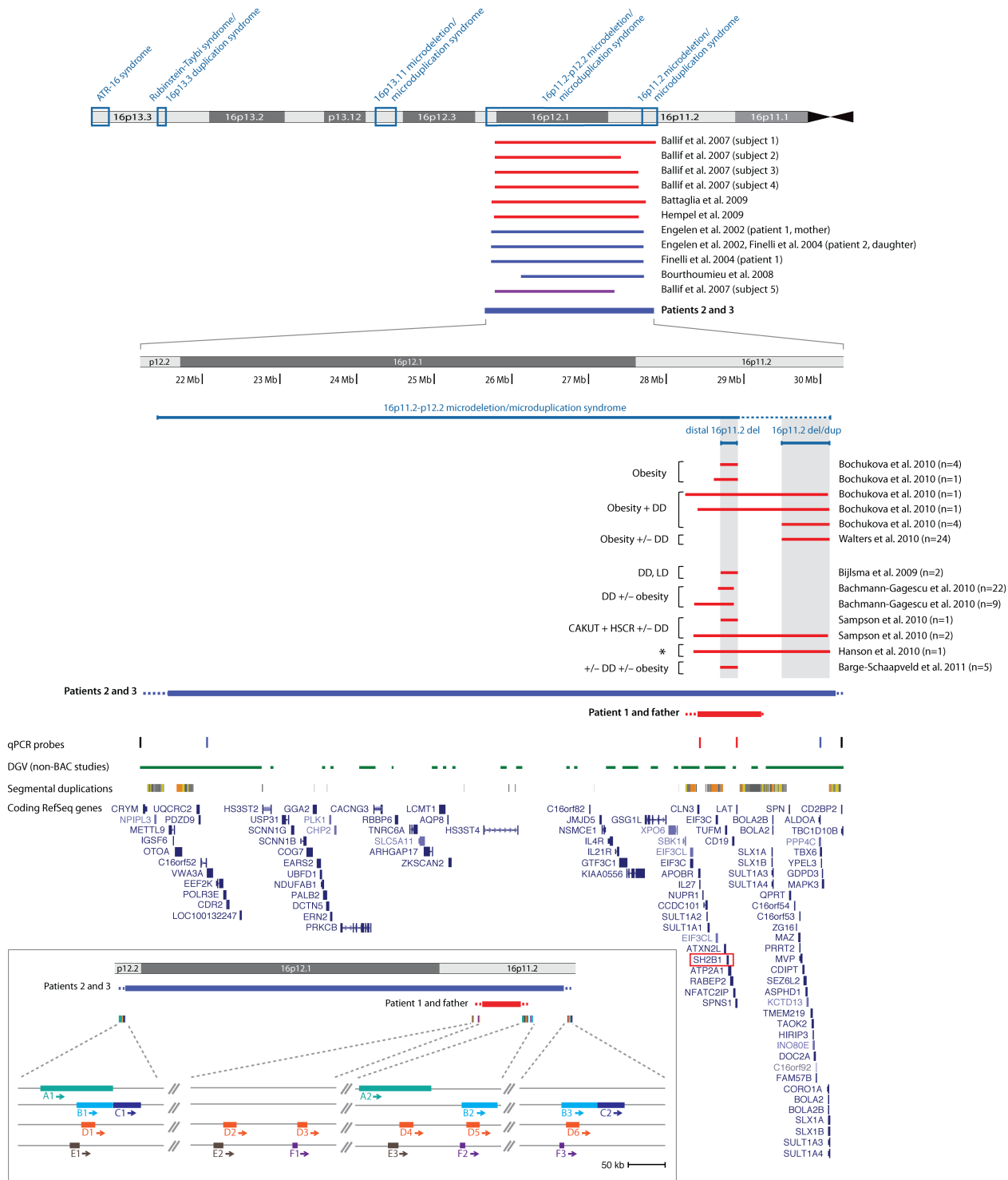
15. Engelen JJ, de Die-Smulders CE, Dirckx R *et al*: Duplication of chromosome region (16)(p11.2 -->p12.1) in a mother and daughter with mild mental retardation. *Am J Med Genet* 2002; **109**: 149-153.
16. Finelli P, Natacci F, Bonati MT *et al*: FISH characterisation of an identical (16)(p11.2p12.2) tandem duplication in two unrelated patients with autistic behaviour. *J Med Genet* 2004; **41**: e90.
17. Bourthoumieu S, Esclaire F, Terro F *et al*: First prenatally diagnosed case of 16p11.2p12.1 duplication. *Prenat Diagn* 2008; **28**: 254-256.
18. Bochukova EG, Huang N, Keogh J *et al*: Large, rare chromosomal deletions associated with severe early-onset obesity. *Nature* 2010; **463**: 666-670.
19. Tabet AC, Aboura A, Gerard M *et al*: Molecular characterization of a de novo 6q24.2q25.3 duplication interrupting UTRN in a patient with arthrogryposis. *Am J Med Genet A* 2010; **152A**: 1781-1788.
20. Glessner JT, Wang K, Cai G *et al*: Autism genome-wide copy number variation reveals ubiquitin and neuronal genes. *Nature* 2009; **459**: 569-573.
21. Pinto D, Pagnamenta AT, Klei L *et al*: Functional impact of global rare copy number variation in autism spectrum disorders. *Nature* 2010; **466**: 368-372.
22. Hanson E, Nasir RH, Fong A *et al*: Cognitive and behavioral characterization of 16p11.2 deletion syndrome. *J Dev Behav Pediatr* 2010; **31**: 649-657.
23. Rosenfeld JA, Coppinger J, Bejjani BA *et al*: Speech delays and behavioral problems are the predominant features in individuals with developmental delays and 16p11.2 microdeletions and microduplications. *J Neurodev Disord* 2010; **2**: 26-38.
24. Ren D, Zhou Y, Morris D, Li M, Li Z, Rui L: Neuronal SH2B1 is essential for controlling energy and glucose homeostasis. *J Clin Invest* 2007; **117**: 397-406.
25. Bachmann-Gagescu R, Mefford HC, Cowan C *et al*: Recurrent 200-kb deletions of 16p11.2 that include the SH2B1 gene are associated with developmental delay and obesity. *Genet Med* 2010; **12**: 641-647.
26. Sampson MG, Coughlin CR, 2nd, Kaplan P *et al*: Evidence for a recurrent microdeletion at chromosome 16p11.2 associated with congenital anomalies of the kidney and urinary tract (CAKUT) and Hirschsprung disease. *Am J Med Genet A* 2010; **152A**: 2618-2622.
27. Barge-Schaapveld DQ, Maas SM, Polstra A, Knecht LC, Hennekam RC: The atypical 16p11.2 deletion: A not so atypical microdeletion syndrome? *Am J Med Genet A* 2011; **155**: 1066-1072.
28. Zhang Y, Zhu W, Wang YG *et al*: Interaction of SH2-Bbeta with RET is involved in signaling of GDNF-induced neurite outgrowth. *J Cell Sci* 2006; **119**: 1666-1676.



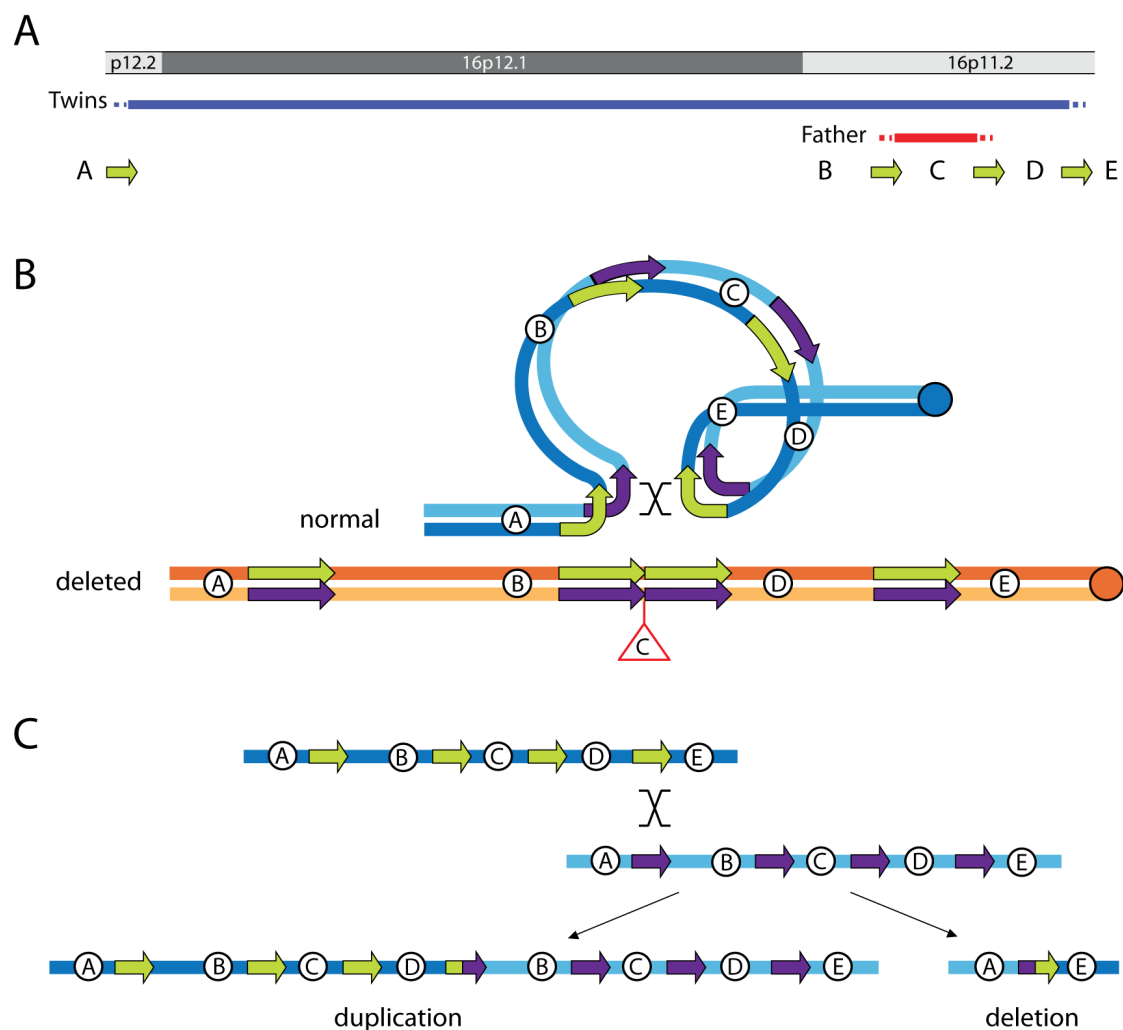
**Figure 1. Photos of Patients 1-3.** **A.** Patient 1, showing some unusual facial features (deep-set eyes, thick supra-orbital ridge with thick eyebrows, wide and prominent nasal bridge, receding chin and everted lower lip). **B-C.** Patient 2 (left) and 3 (right); note similar dysmorphic features with hypertelorism, upslanting palpebral fissures, broad nasal bridge and tip, everted lower lip and retrognathia with marked chin. **D.** Sternum deformity in Patient 2 (also present in his twin brother).



**Figure 2. Microarray and qPCR results. A.** SNP array profiles of chromosome 16 showing a 16p11.2 deletion in Patient 1, inherited from his father (both highlighted in red), a *de novo* 16p11.2p12.1 duplication in Patient 2 (highlighted in blue), and a normal profile in the mother. **B.** Quantitative PCR probes confirmed the 16p11.2p12.2 duplication in the twins (Patients 2 and 3) and the 16p11.2 deletion in Patient 1 and the father compared with 3 controls. Data represent mean  $\pm$  SEM.



**Figure 3. Map of the short arm of chromosome 16 with a summary of abnormalities identified in the 16p11.2-p12.2 region.** Schematic representation of chromosome 16p showing the 16p11.2-p12.2 duplication in Patients 2 and 3 (thick blue line) and other overlapping rearrangements reported previously: four duplications (thin blue lines), six deletions (red lines) and one complex rearrangement involving a duplication and a triplication (purple line). The location of five recurrent microdeletion/microduplication syndromes is represented by blue rectangles on the ideogram. A detailed map of ~9 Mb (21177300-30296811, hg 18), comprising the duplication in Patients 2 and 3 (thick blue line) and the deletion in Patient 1 and the father (thick red line) is shown. Additional horizontal thin red lines indicate deletions described previously in individuals with obesity, developmental delay (DD), learning disability (LD), congenital anomalies of the kidney and urinary tract (CAKUT), or Hirschsprung disease (HSCR). The patient marked with an asterisk was too young to evaluate the manifestations reliably. qPCR probes are shown as vertical bars; black bars represent a normal copy number, blue bars indicate a duplication (in Patients 2 and 3) and red bars indicate a deletion (in Patient 1 and the father). Horizontal green lines indicate the location of structural variations identified in non-BAC studies according to the Database of Genomic Variants (DGV). The inset shows a simplified interpretation of the segmental duplications located in the 16p11.2-p12.2 region (UCSC genome browser). See Supplementary Note for a detailed description of these segmental duplications and their possible role in the observed rearrangements in the family described here.



**Figure 4. Proposed mechanism for the formation of the 16p11.2-p12.2 duplication in the twins. A.** Chromosome 16p region comprising the duplication in the twins (blue line) and the 16p11.2 deletion in the father (red line). Blocks of segmental duplications in the same orientation with a high degree of identity overlapping the breakpoint regions are represented by green arrows (see Supplementary note for details). Letters A-E indicate the chromosomal regions represented in the panels below. **B.** One of the paternal chromosomes (orange) carries a deletion of the segment identified as C. During meiosis, the normal chromosome (blue) forms a deletion loop; the genome architecture of the region facilitates misalignment of directly oriented segmental duplications, followed by nonallelic homologous recombination (NAHR) within the loop. **C.** Interchromatid mispairing of direct repeats results in duplication (the recombinant product transmitted to the twins) and deletion.