



**HAL**  
open science

## Cortical representation of tympanic membrane movements due to pressure variation: an fMRI study.

Agnès Job, Jean-Charles Paucod, Greg A. O'Beirne, Chantal Delon-Martin

### ► To cite this version:

Agnès Job, Jean-Charles Paucod, Greg A. O'Beirne, Chantal Delon-Martin. Cortical representation of tympanic membrane movements due to pressure variation: an fMRI study.: fMRI study of tympanic movements. *Human Brain Mapping*, 2011, 32 (5), pp.744-9. 10.1002/hbm.21063 . inserm-00638231

**HAL Id: inserm-00638231**

**<https://inserm.hal.science/inserm-00638231>**

Submitted on 4 Nov 2011

**HAL** is a multi-disciplinary open access archive for the deposit and dissemination of scientific research documents, whether they are published or not. The documents may come from teaching and research institutions in France or abroad, or from public or private research centers.

L'archive ouverte pluridisciplinaire **HAL**, est destinée au dépôt et à la diffusion de documents scientifiques de niveau recherche, publiés ou non, émanant des établissements d'enseignement et de recherche français ou étrangers, des laboratoires publics ou privés.

## **Cortical Representation of Tympanic Membrane Movements due to Pressure Variation: An fMRI Study**

**Agnès Job,<sup>1\*</sup> Jean-Charles Paucod,<sup>1</sup> Greg A. O'Beirne,<sup>2</sup> Chantal Delon-Martin<sup>3,4</sup>**

<sup>1</sup> *Institut de Recherche Biomédicale des Armées, antenne La Tronche (CRSSA), Grenoble, France*

<sup>2</sup> *Department of Communication Disorders, University of Canterbury, Christchurch, New Zealand*

<sup>3</sup> *INSERM U836, Grenoble, France*

<sup>4</sup> *Université Joseph Fourier, Institut des Neurosciences de Grenoble, France*

Short title : fMRI study of tympanic movements

Keywords: middle ear; somatosensory cortex; hearing; fMRI; acoustic reflex; BA43; Eustachian tube; air pressure

\*Correspondence to: Agnès Job. Institut de Recherche Biomédicale des Armées (IRBA)-antenne-CRSSA, 24 avenue des maquis du Grésivaudan 38702 La Tronche-France. Email : [ajob.crssa@gmail.com](mailto:ajob.crssa@gmail.com)

## **Abstract**

Middle ear sensory information has never been localized in the homunculus of the somatosensory cortex (S1). We investigated the somatosensory representation of the middle ear in 15 normal hearing subjects. We applied small air pressure variations to the tympanic membrane while performing a 3T fMRI study. Unilateral stimulations of the right ear triggered bilateral activations in the caudal part of the postcentral gyrus in Brodmann area 43 (BA 43) and in the auditory associative areas 42 (BA 42) and 22 (BA 22). BA 43 has been found to be involved in activities accompanying oral intake, and could be more largely involved in pressure activities in the oropharynx area. The tympanic membrane is indirectly related to the pharynx area through the action of tensor tympani, which is a Eustachian tube muscle. The Eustachian tube muscles have a role in pressure equalisation in the middle ear and also have a role in the pharyngeal phase of swallowing. Activation of BA 42 and BA 22 could reflect activations associated with the bilateral acoustic reflex triggered prior to self-vocalization to adjust air pressure in the oropharynx during speech. We propose that BA 43, 42 and 22 are the cortical areas associated with middle ear function. We did not find representation of tympanic membrane movements due to pressure in S1, but its representation in the postcentral gyrus in BA 43 seems to suggest that at least part of this area conveys pure somatosensory information.

## **Introduction**

Mapping the functional topography of the primary somatosensory areas is essential to unravel the organization of somatosensory input at the level of the cerebral cortex. In humans, the somatosensory homunculus was first described by Penfield (Penfield and Rasmussen 1950). The human cortical map revealed a conspicuous overrepresentation of the hand and the orofacial body parts, compared to other body parts. In contrast there has been a lack of publications regarding the representation of the ear.

There has been only one fMRI study that attempted to map the superficial sensitivity of the pinna (i.e., helix, lobule, tragus) in the primary somatosensory cortex by using electrical stimulation. In this publication, electrical stimulation of the surface of the pinna activated the somatosensory areas for the neck or the face (Nihashi, et al. 2002). To date, the somatosensory homunculus lacks a defined area corresponding to middle ear sensitivity (i.e, to pressure variations on the tympanic membrane) and to our knowledge, the sensitivity of the middle ear has never been investigated by neuroimaging tools. Spatial localization of the middle ear in the somatosensory cortex through movements of the tympanic membrane could help to localize subclinical dysfunctions in clinical audiology. Subclinical dysfunctions of the middle ear are not detected by classical methods (Job and Nottet 2002) and seem to be insidiously deleterious to hearing if the origin of the problem is not localized (Job, et al. 1999). Various causes of hearing disorders are known to relate to middle ear dysfunction, such as progressive otosclerosis, otitis media, barotrauma, Menière's disease, ossicular disruption with tympanic perforation due to blast or impulse noise, myoclonus of tensor tympani, and so on (Hugues and Pensak 2007).

The middle ear muscles are not easily accessible and their sensitivity is essentially of a proprioceptive nature, in that they are sensitive to tension or pressure via their stretch receptors (Kierner, et al. 1999; Nagai 1995). The tympanic membrane stretch receptors are the more superficial sensors accessible.

The primary function of the middle ear system is to reduce the reflection of acoustic energy that would occur if the low impedance of the air in the ear canal made direct contact with the high-impedance cochlear fluids. This pre-cochlear impedance-matching mechanism is necessary for normal hearing to occur, and requires a normal external ear, and a middle ear with an intact tympanic membrane, a normal ossicular chain, and a well-ventilated tympanic cavity. The clinical manifestation of dysfunction or disease of these components is conductive hearing loss (Hugues and Pensak 2007). For the tympanic membrane to vibrate optimally in response to sound waves, the air pressure within the middle ear and the external environment must be equal. The Eustachian tube helps achieve this by acting as a pressure release valve to adjust the middle ear pressure (Bluestone, et al. 1974).

The Eustachian tube extends from the anterior wall of the tympanic cavity to the lateral wall of the nasopharynx. In its resting state, the Eustachian tube valve is closed because of the elastic forces of the tube and its supporting structures. The valve area within the nasopharynx dilates to equilibrate pressure if needed. This information is certainly conveyed by the mechanical proprioceptors of the tympanic membrane, which are sensitive to tension or pressure. Ultrastructural studies have revealed the presence of mechanoreceptors such as Pacinian corpuscles in the tympanic membrane (Nagai 1995). In addition, the middle ear tympano-ossicular chain possesses the two smallest striated muscles in the body: the tensor tympani and the stapedius. The tensor tympani muscle attaches to the superior portion of the

malleus, and the stapedius muscle emerges from the pyramidal eminence to attach to the upper portion of the stapes (Figure 1). The movement of the tympanic membrane by infrasonic variations in ear-canal air pressure should result in slight mechanical forces being transferred to the tensor tympani muscle tendons and to a lesser extent the stapedius muscle. The tensor tympani and stapedius muscles have been shown to contain a small number of muscle spindles and intrafusal fibers (Kierner, et al. 1999). Mobilisation of the tympano-ossicular chain by inducing air pressure changes across the tympanic membrane might therefore also activate these proprioceptors. Indeed, the high sensitivity of the primary endings of the intrafusal fibers to weak stretches of 100  $\mu\text{m}$  or less makes these neurons highly sensitive to muscle vibration (Roll, et al. 1989), which raises the possibility that tympanic movements by air pressure variation might be visible within the cortex using fMRI methods.

## **Materials and methods**

### **Subjects and experimental design**

Fifteen healthy, right-handed volunteers (mean age  $35 \pm 6$  years; 8 males, 7 females) participated in the study that was approved by a local ethics committee. All subjects gave written consent. Subjects had normal hearing as confirmed by otoscopy and pure-tone audiometry, had no particular past history of ear, nose and throat problems, and had normal middle-ear pressures. Volunteers were equipped with a soundproof headset. Under the headset a tympanometric probe tip was sealed in the ear canal of both ears and connected to a long plastic catheter ( $\text{\O} 1 \text{ mm}$ , L 12 m) that extended outside the scanner room via a waveguide. The left ear side was hermetically closed with air at atmospheric pressure, while the right ear side was

connected to a manometer (Delmo. Paris) and a 5 mL-syringe filled with air at atmospheric pressure (Figure 2). The syringe was used to vary the air pressure in the ear canal by up to + 40 mm H<sub>2</sub>O (~ + 40 daPa), as measured with the manometer. Stimulation was far less than the variations of pressure normally used by tympanometric instruments (i.e. ± 200 daPa). Stimuli were alternating compressions of 40 daPa and decompressions of 40 daPa (to return to atmospheric pressure). Over a 24 second period we administered randomly 24 to 30 air pressure variations (i.e., 12 to 15 pressure cycles). The inter-stimulus interval (ISI) with no variation was 24 seconds. The timing of periods was controlled by a computer using PRESENTATION® software (Neurobehavioural Systems) that also synchronized periods with the MR-scanner.

Because the stimulation was barely detectable by subjects and required a great deal of concentration, we checked that at least one slight tympanic movement could be perceived before entering the 3T tunnel.

Subjects were instructed to remain relaxed, not to focus attention on their ears, to put their hands upon their abdomen, and to keep their eyes closed during the fMRI measurements. They were not instructed about the ear where air pressure variations would be produced.

We deliberately restricted the stimulation to only one ear because interpretation of any bilateral activations of the cortex would be ambiguous if both ears were stimulated (i.e., possible contingent after-effects due to alternating stimulation, as has been shown for vision (Potts and Harris 1975), audition (Ehrenstein 1994) and movement (Maravita 1997).)

### **fMRI protocol**

MR images were acquired on a 3T whole-body MR scanner (Bruker Medspec S300) using a birdcage head coil. In order to limit the B0 non-homogeneities and thus, to prevent image distortions, we applied an automatic second-order shimming procedure. BOLD contrast functional images were acquired using a conventional single-shot gradient echo planar imaging sequence. A total of 38, 3 mm thick axial slices were acquired axially, parallel to AC-PC commissures. The main T2\* weighted EPI sequence parameters were: TR 2400 ms, TE 30 ms, flip angle 80°, spectral bandwidth 172 kHz, field of view 216 x 216 mm, matrix 72 x 72, providing isotropic voxels of 3 x 3 x 3 mm<sup>3</sup>. After 6 dummy images to allow the spin system to reach equilibrium, 210 brain volumes were acquired for each subject during a single functional run. The stimulation paradigm was presented following a block diagram of ten alternations of a 24-s long rest with a 24-s long irregular pressure variations applied to the right ear. Eventually, a high resolution (1 mm<sup>3</sup>) anatomical image of the whole brain was acquired with a T1 weighted MDEFT sequence (TR 11.975 ms, TE 4.57 ms, TI 900 ms, recovery time 2.5 s, FOV 256 x 256 x 176, matrix 256 x 256 x 176, 2 segments).

### **fMRI data processing and statistical analysis**

Imaging data were pre-processed and analyzed using Statistical Parametric Mapping software (SPM8, Wellcome Department of Cognitive Neurology, London, <http://www.fil.ion.ucl.ac.uk/spm>). All functional volumes were corrected for motion, spatially normalized, using the T1 weighted template provided by the Montreal Neurological Institute (MNI) and were spatially smoothed with a 6 mm full-width-at-half-maximum isotropic Gaussian kernel.



The individual statistical analysis of the variations of the BOLD signal was based on the application of a general linear model. We modelled the air pressure variation period by a boxcar function convolved by the canonical hemodynamic response function. The onsets of this regressor corresponded to the onset of stimulus period incremented by half a scan duration to take into account the delay for the manipulator to start the pressure variations. Re-alignment parameters were introduced in the model as regressors of no interest. The model was estimated after a high-pass filtering (cutting frequency 1/192 Hz) to remove slow drifts in the baseline of the data. The contrast image corresponding to the response to pressure variations as compared to resting periods was computed for each subject using a Student's t-test. These contrast images were then entered in a random effects analysis, permitting inferences across subjects that generalise to the population. A one-sample Student's t-test was applied to locate the regions where BOLD level was significant against the null hypothesis. We thresholded the computed statistical t-maps at  $p < 0.001$  and extent  $> 10$  voxels. At these thresholds, the probability at the cluster level was below  $p < 0.05$  after correction by the false discovery rate method.

### **Statistical test for hemispheric differences**

Hemispheric differences in the hemodynamic BOLD response were assessed using a voxel-based left versus right hemisphere comparison method (Stevens, et al. 2005). First, a hemispherically symmetric template was derived from the T1-weighted template of the standard MNI template. Second, functional images were spatially normalized onto this symmetric template and smoothed with the same Gaussian kernel as for the standard analysis. After application of the same individual statistical analysis as described above, a contrast image was derived for each subject

representing the difference between the stimulation period and the rest period using a Student's t-test. In order to create images representing the difference in the contrast between the two hemispheres for each individual, a symmetric contrast image was first derived by flipping the image along the antero-posterior y-axis leading to an image where hemispheres were permuted. Second, the individual differential left-right contrast image was calculated by simply subtracting the direct contrast image from the symmetric contrast image. Each subject's differential images were further entered in a one-sample t-test random effect analysis. Differences were considered significant at a voxelwise threshold of  $p < 0.001$ , uncorrected for multiple comparisons and extent  $>10$  voxels.

## Results

Most of the 15 subjects followed the instructions and reported that they did not pay any attention to the slight perceptions during fMRI measurements, but 6 subjects nevertheless reported having sometimes perceived some variations of pressure in the right ear. Interestingly, 3 of them had the impression of perceiving something in both ears. None of them reported any periodicity during the test. Moving the right tympanic membrane by variations in air pressure activated regions in temporal and parietal lobe bilaterally (Figure 3). The Brodmann areas concerned (Table 1) were the more anterior part of the auditory associative cortex (BA 42 and 22), and the caudal part of the postcentral gyrus (BA 43). Although activation within the two hemispheres looked slightly asymmetrical, contrast between right and left hemispheres did not reveal any statistically significant differences.

## Discussion

The fMRI experiment clearly showed that the tympanic membrane and the associated movements project into Brodmann area 43, the area involved in activities accompanying oral intake such as gustation and swallowing (Afifi and Bergmann 2005; Cerf-Ducastel, et al. 2001; Malandraki, et al. 2009; Mosier, et al. 1999; Soros, et al. 2009).

Our surprising result prompted us to analyse the mechanical phases of swallowing. The swallowing process is a highly complex sensorimotor process (Miller 1993) involving the oropharynx, larynx, mandible, tongue and face (Hamdy, et al. 1999). The three phases usually described for swallowing are oral, pharyngeal and oesophageal. The oral phase requires taste (Leow, et al. 2007), temperature, touch found in gustation activities and facial movements of mastication to prepare the bolus (Sessle 2006). Also, touch by air pulse in the oropharynx activates neighbouring regions to ours in the postcentral gyrus (Soros, et al. 2008). The pharyngeal phase of deglutition involves the muscles that attach to the Eustachian tube. The tensor tympani muscle which tenses the tympanic membrane, the veli palatini muscles and the salpingopharyngeus muscle are Eustachian tube muscles. A recent publication by Kierner and colleagues (Kierner, et al. 2002) demonstrated that the tensor tympani and the tensor veli palatini are in histochemical continuity with a long tendon. The authors suspected that these muscles could form a functional unit (Figure 4). Tensor veli palatini is clearly involved in deglutition. Also, Nagai and colleagues (Nagai 1995) at the time suspected a neural connection between sensory receptors of tympanic membrane and Eustachian tube muscles because of disturbed tubal function when swallowing if the tympanic membrane was anesthetized. Stretch receptors in the

tympanic membrane may be related to the modulation of middle-ear pressure through the tensor tympani muscle, thereby affecting the tensor veli palatini in opening the Eustachian tube.

The second and third activated areas were located in auditory associative areas BA 42 and BA 22. Tympanic stimulation, although strictly unilateral, triggered a bilateral activation. Bilateral activation of the middle-ear acoustic reflex can be triggered by unilateral stimulation (Borg and Nilson 1984). When presented with a high-intensity sound stimulus in one ear, the stapedius muscle contracts in both ears, pulling the stapes away from the oval window of the cochlea and tensing the ossicular chain.

However, bilateral middle-ear stiffening can also be elicited before sound is actually produced, like prior to vocal onset (Borg and Zakrisson 1975; Hage, et al. 2006) or synchronously with vocalisation (Avan, et al. 1992). Howell and colleagues (Howell, et al. 1986) suggested that tensor tympani is primarily responsible for the pre-vocalization reflex activity. Our results contribute to the idea that tensor tympani may also be involved in the acoustic reflex in human at some level, as it is in many other species.

Contraction of either of the middle-ear muscles transiently increases the impedance of the middle ear system. This increased impedance limits the resonance phenomenon produced by speech in the naso-pharynx by contributing to the tonic control of eardrum tension. BA 22 has been thought to be involved in speech processing (Giraud, et al. 2000). Tensing the eardrum by moving the tympanic membrane could roughly mimic these small modulations of pressure in the middle ear that occur during speech production and during optimal listening. Also, maintaining similar air pressures (and therefore, impedances) in both middle-ears

would allow for preservation of interaural level differences (ILDs) used to locate sound sources in the horizontal plane. This principal may be reflected the bilateral activation of the auditory reflex.

In our experiment, activations due to the possible anticipation of stimuli were unlikely, because there were almost no cue for the subjects to know precisely when these variations of pressure occurred. Indeed, acquisition was continuous, stimulation was barely detectable and the rhythm of pressure variations was irregular.

Further studies will be needed to test any right/left ear differences with regard to air pressure variations and to test the effects of other pressure variation situations.

## **Conclusion**

Our study has demonstrated that variations of pressure inducing movement or distension of the tympanic membrane projects into the postcentral gyrus in BA 43 and associative auditory area BA 42 and 22. Very little is known about BA 43, but it seems to be involved with somatosensory effects like pressure in the oropharynx and involuntary reflexes linked to adjustment of middle ear pressure before motor actions, as can be found in swallowing and in listening/vocalizing function.

We did not find representation of tympanic membrane movements due to pressure in S1, but its representation in the postcentral gyrus in BA 43 seems to suggest that at least part of this area conveys pure somatosensory information.

## **Acknowledgments**

We sincerely thank Renaud Maury, Alain Roux and Laurent Lamalle for their helpful technical assistance. This study was supported by a grant from the French government (DGA/PEA 010809/ project n°05Co002-05).

## Legends

Figure 1 : Anatomical representation of middle ear tympano-ossicular chain muscles. Drawing from André Leblanc. Atlas des organes de l'audition et de l'équilibration Springer Verlag France 1998 pp 58.

Figure 2 : MRI compatible air pressure variation system, sealed in the external auditory canal and controlled by a manometer.

Figure 3 : Activation foci revealed by fMRI related to right tympanic membrane motion due to pressure variation. Two of the foci are located in the inferior margin of the postcentral gyrus, corresponding to BA 43. The other foci are located in the superior temporal gyrus, corresponding to auditory associative areas BA 42 and BA 22. Functional activation foci are superimposed on the mean normalized anatomical image of our group of subjects. Right corresponds to right hemisphere.

Figure 4 : Anatomical relationship of the Eustachian tube muscles showing the probable connection between tensor tympani and tensor veli palatini. Drawing from Pediatric Otolaryngology, Vol. 1 Edition 2003. Chapter 25. Bluestone C. D. Klein J.O p 506.

Table 1 : MNI coordinates and maximal t values for main activation clusters in temporal and parietal cortices.

## References

- Afifi AK, Bergmann RA. 2005. Functional neuroanatomy: text and atlas: Mc Graw-Hill compagny. 494 p.
- Avan P, Loth D, Menguy C, Teyssou M. 1992. Hypothetical roles of middle ear muscles in the guinea-pig. *Hear Res* 59(1):59-69.
- Bluestone CD, Beery QC, Andrus WS. 1974. Mechanics of the Eustachian tube as it influences susceptibility to and persistence of middle ear effusions in children. *Ann Otol Rhinol Laryngol* 83:Suppl 11:27-34.
- Borg E, Nilson R. 1984. Acoustic reflex in industrial noise. New York: Academic Press.
- Borg E, Zakrisson JE. 1975. The activity of the stapedius muscle in man during vocalization. *Acta Otolaryngol* 79(5-6):325-33.
- Cerf-Ducastel B, Van de Moortele PF, MacLeod P, Le Bihan D, Faurion A. 2001. Interaction of gustatory and lingual somatosensory perceptions at the cortical level in the human: a functional magnetic resonance imaging study. *Chem Senses* 26(4):371-83.
- Ehrenstein WH. 1994. Auditory aftereffects following simulated motion produced by varying interaural intensity or time. *Perception* 23(10):1249-55.
- Giraud AL, Truy E, Frackowiak RS, Gregoire MC, Pujol JF, Collet L. 2000. Differential recruitment of the speech processing system in healthy subjects and rehabilitated cochlear implant patients. *Brain* 123 ( Pt 7):1391-402.
- Hage SR, Jurgens U, Ehret G. 2006. Audio-vocal interaction in the pontine brainstem during self-initiated vocalization in the squirrel monkey. *Eur J Neurosci* 23(12):3297-308.
- Hamdy S, Mikulis DJ, Crawley A, Xue S, Lau H, Henry S, Diamant NE. 1999. Cortical activation during human volitional swallowing: an event-related fMRI study. *Am J Physiol* 277(1 Pt 1):G219-25.
- Howell P, Marchbanks RJ, el-Yaniv N. 1986. Middle ear muscle activity during vocalization in normal speakers and stutterers. *Acta Otolaryngol* 102(5-6):396-402.
- Hugues GB, Pensak ML. 2007. Clinical otology: Thieme. 528 p.
- Job A, Nottet JB. 2002. DPOAEs in young normal-hearing subjects with histories of otitis media: evidence of sub-clinical impairments. *Hear Res* 167(1-2):28-32.
- Job A, Raynal M, Rondet P. 1999. Hearing loss and use of personal stereos in young adults with antecedents of otitis media. *Lancet* 353(9146):35.
- Kierner AC, Mayer R, v Kirschhofer K. 2002. Do the tensor tympani and tensor veli palatini muscles of man form a functional unit? A histochemical investigation of their putative connections. *Hear Res* 165(1-2):48-52.
- Kierner AC, Zelenka I, Lukas JR, Aigner M, Mayr R. 1999. Observations on the number, distribution and morphological peculiarities of muscle spindles in the tensor tympani and stapedius muscle of man. *Hear Res* 135(1-2):71-7.
- Leow LP, Huckabee ML, Sharma S, Tooley TP. 2007. The influence of taste on swallowing apnea, oral preparation time, and duration and amplitude of submental muscle contraction. *Chem Senses* 32(2):119-28.
- Malandraki GA, Sutton BP, Perlman AL, Karampinos DC, Conway C. 2009. Neural activation of swallowing and swallowing-related tasks in healthy young adults: An attempt to separate the components of deglutition. *Hum Brain Mapp*.



- Maravita A. 1997. Implicit processing of somatosensory stimuli disclosed by a perceptual after-effect. *Neuroreport* 8(7):1671-4.
- Miller AJ. 1993. The search for the central swallowing pathway: the quest for clarity. *Dysphagia* 8(3):185-94.
- Mosier K, Patel R, Liu WC, Kalnin A, Maldjian J, Baredes S. 1999. Cortical representation of swallowing in normal adults: functional implications. *Laryngoscope* 109(9):1417-23.
- Nagai T. 1995. Innervation of the tympanic membrane. *Acta Otorhinolaryngol Belg* 49(2):117-20.
- Nihashi T, Kakigi R, Okada T, Sadato N, Kashikura K, Kajita Y, Yoshida J. 2002. Functional magnetic resonance imaging evidence for a representation of the ear in human primary somatosensory cortex: comparison with magnetoencephalography study. *Neuroimage* 17(3):1217-26.
- Penfield W, Rasmussen T. 1950. *The cerebral cortex of Man*. New York. Mac Millian compagny
- Potts MJ, Harris JP. 1975. Movement aftereffects contingent on the colour or pattern of a stationary surround. *Vision Res* 15(11):1225-30.
- Roll JP, Vedel JP, Ribot E. 1989. Alteration of proprioceptive messages induced by tendon vibration in man: a microneurographic study. *Exp Brain Res* 76(1):213-22.
- Sessle BJ. 2006. Mechanisms of oral somatosensory and motor functions and their clinical correlates. *J Oral Rehabil* 33(4):243-61.
- Soros P, Inamoto Y, Martin RE. 2009. Functional brain imaging of swallowing: an activation likelihood estimation meta-analysis. *Hum Brain Mapp* 30(8):2426-39.
- Soros P, Lalone E, Smith R, Stevens T, Theurer J, Menon RS, Martin RE. 2008. Functional MRI of oropharyngeal air-pulse stimulation. *Neuroscience* 153(4):1300-8.
- Stevens MC, Calhoun VD, Kiehl KA. 2005. Hemispheric differences in hemodynamics elicited by auditory oddball stimuli. *Neuroimage* 26(3):782-92.

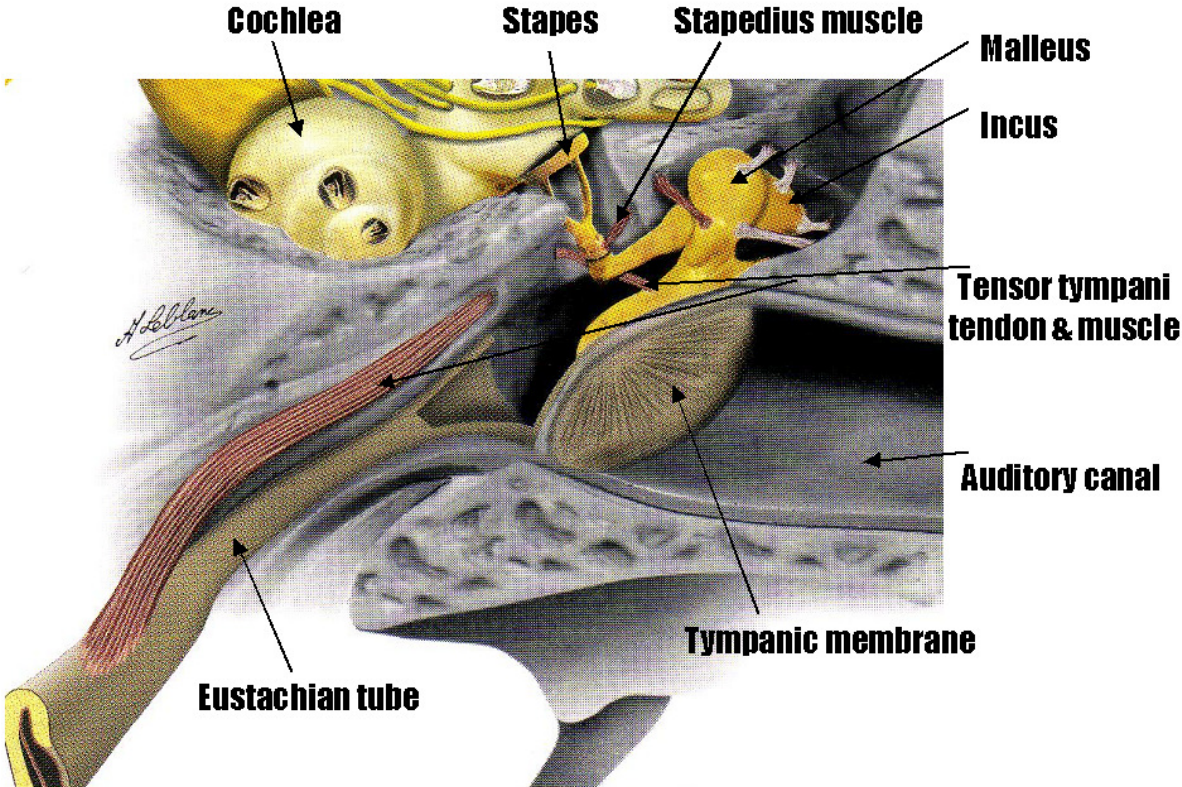


Fig1

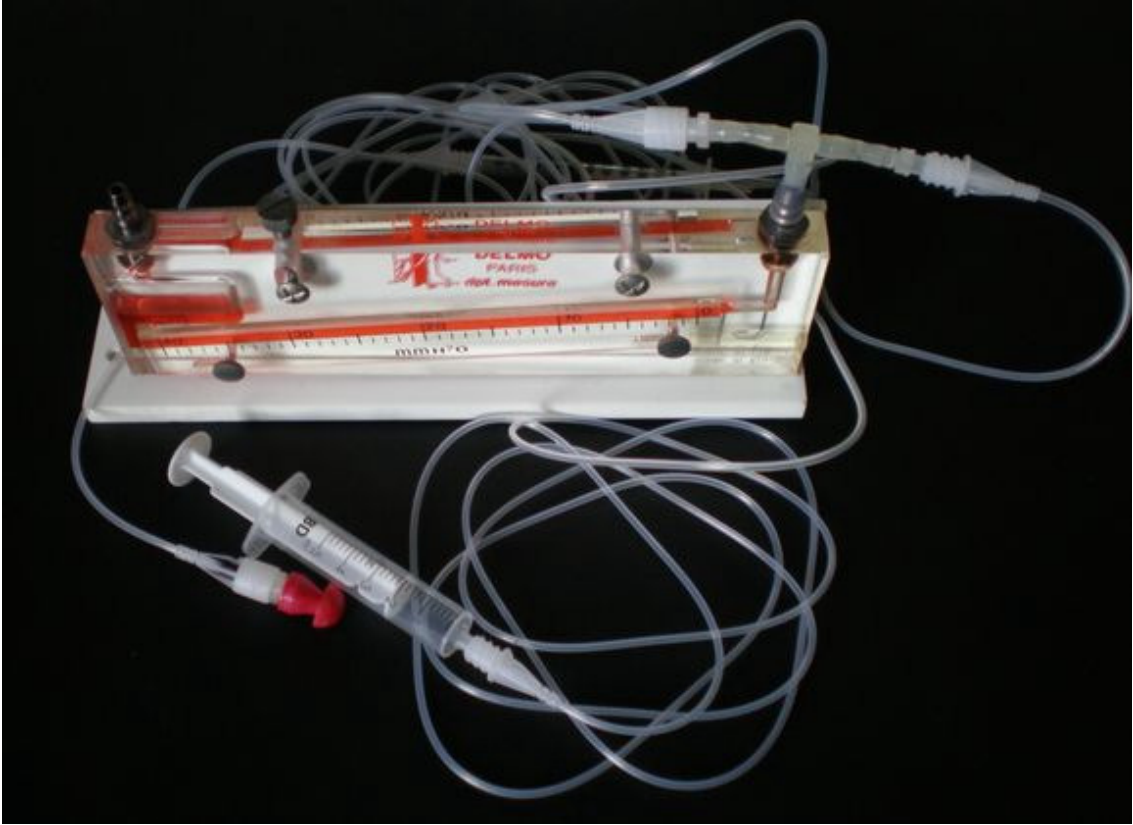


Fig 2

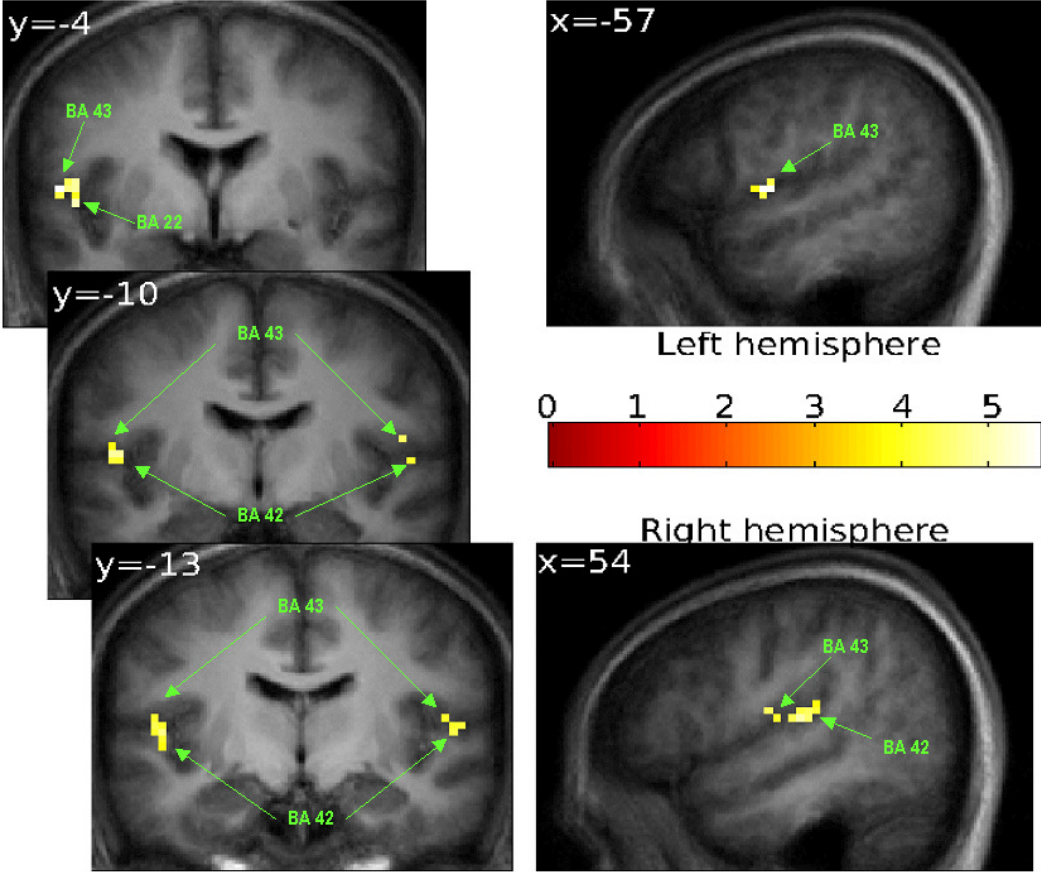


Fig 3

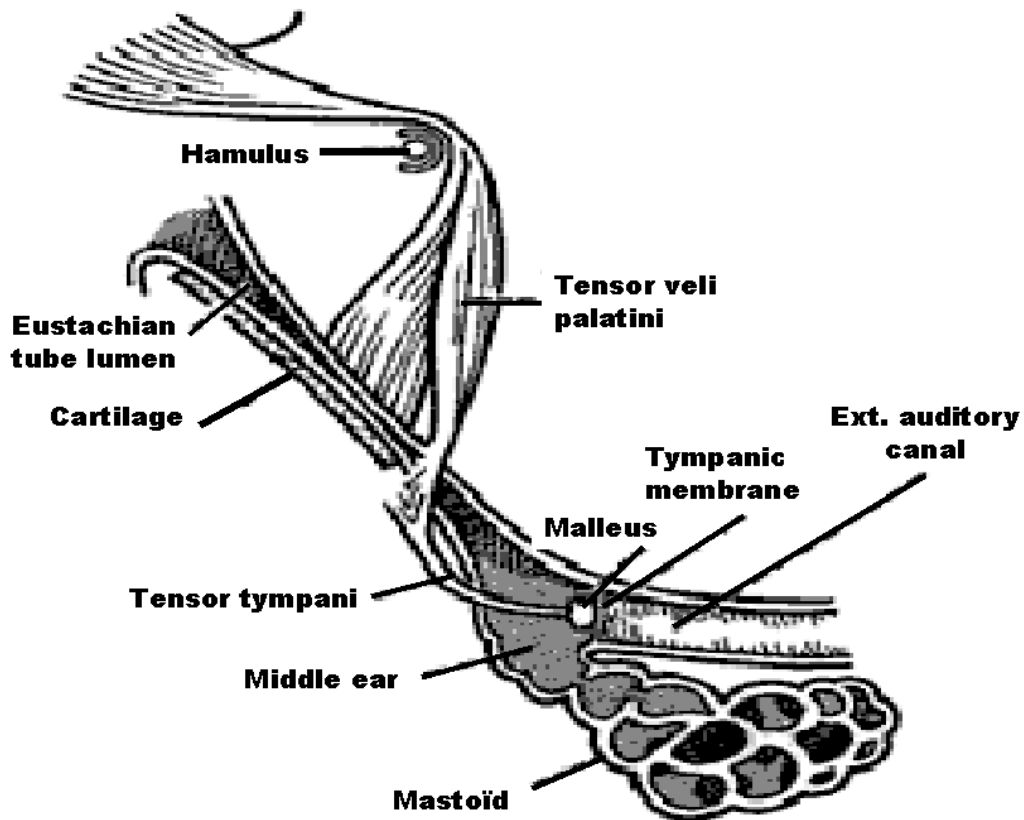


Fig 4.

Regions of Interest	Side	Brodmann Area (BA)	Voxel of peak Intergroup difference in t MNI coordinates				t
			X	Y	Z		
<b>TEMPORAL LOBES</b>							
Temporal superior gyrus	L	BA 42	-45	-31	7	5.58	
Temporal superior gyrus	L	BA 22	-51	-4	1	4.97	
Temporal superior gyrus	R	BA 42	54	-22	13	4.90	
Temporal superior gyrus	R	BA 42	51	-31	19	4.39	
<b>PARIETAL LOBES</b>							
Postcentral gyrus (caudal)	L	BA 43	-57	-4	7	5.49	
Postcentral gyrus (caudal)	R	BA 43	54	-10	16	4.34	

Table 1