



## **Clinical and molecular characterization of 17q21.31 microdeletion syndrome in 14 French patients with mental retardation.**

Christèle Dubourg, Damien Sanlaville, Martine Doco-Fenzy, Cédric Le Caignec, Chantal Missirian, Sylvie Jaillard, Caroline Schluth-Bolard, Emilie Landais, Odile Boute, Nicole Philip, et al.

### **► To cite this version:**

Christèle Dubourg, Damien Sanlaville, Martine Doco-Fenzy, Cédric Le Caignec, Chantal Missirian, et al.. Clinical and molecular characterization of 17q21.31 microdeletion syndrome in 14 French patients with mental retardation.. European Journal of Medical Genetics, 2011, 54 (2), pp.144-51. 10.1016/j.ejmg.2010.11.003 . inserm-00541962

**HAL Id: inserm-00541962**

**<https://inserm.hal.science/inserm-00541962>**

Submitted on 1 Dec 2010

**HAL** is a multi-disciplinary open access archive for the deposit and dissemination of scientific research documents, whether they are published or not. The documents may come from teaching and research institutions in France or abroad, or from public or private research centers.

L'archive ouverte pluridisciplinaire **HAL**, est destinée au dépôt et à la diffusion de documents scientifiques de niveau recherche, publiés ou non, émanant des établissements d'enseignement et de recherche français ou étrangers, des laboratoires publics ou privés.

# Clinical and molecular characterization of 17q21.31 microdeletion syndrome in 14 French patients with mental retardation

Christèle Dubourg<sup>1,2</sup>, Damien Sanlaville<sup>3,4</sup>, Martine Doco-Fenzy<sup>5,6</sup>, Cédric Le Caignec<sup>7</sup>, Chantal Missirian<sup>8</sup>, Sylvie Jaillard<sup>2,9</sup>, Caroline Schluth-Bolard<sup>3,4</sup>, Emilie Landais<sup>5,6</sup>, Odile Boute<sup>10</sup>, Nicole Philip<sup>8</sup>, Annick Toutain<sup>11</sup>, Albert David<sup>7</sup>, Patrick Ederly<sup>3,4</sup>, Anne Moncla<sup>8</sup>, Dominique Martin-Coignard<sup>12</sup>, Catherine Vincent-Delorme<sup>13</sup>, Isabelle Mortemousque<sup>11</sup>, Bénédicte Duban-Bedu<sup>14</sup>, Sèverine Drunat<sup>15</sup>, Mylène Beri<sup>16</sup>, Jean Mosser<sup>2,17</sup>, Sylvie Odent<sup>2,18</sup>, Véronique David<sup>1,2</sup>, Joris Andrieux<sup>19</sup>

(1) Laboratoire de Génétique Moléculaire, CHU Pontchaillou, Rennes, France

(2) CNRS UMR 6061, IFR140, Université de Rennes 1, Rennes, France

(3) Laboratoire de Cytogénétique, CBPE, Hospices Civils de Lyon, Bron, France

(4) Université Claude Bernard Lyon I, Faculté de Médecine, Lyon Nord, France

(5) Service de Génétique, HMB, CHRU de Reims, France

(6) EA 3801, UFR de Médecine, Reims, France

(7) Service de Génétique Médicale, CHU, Nantes, France

(8) Département de Génétique Médicale, Hôpital d'Enfants de la Timone, Marseille, France

(9) Laboratoire de Cytogénétique, CHU Pontchaillou, Rennes, France

(10) Service de Génétique Clinique, Hôpital Jeanne de Flandre, CHRU de Lille, France

(11) Service de Génétique, Hôpital Bretonneau, CHRU de Tours, France

(12) Service de Pédiatrie Génétique, CH, Le Mans, France

(13) Service de Pédiatrie Génétique, CH, Arras, France

(14) Centre de Génétique Chromosomique, Hôpital St Vincent de Paul, Lille

(15) Service de Génétique, CHU Hôpital Robert Debré, Paris, France

(16) Service de Génétique, CHU Hôpital Brabois, Nancy, France

(17) Plateforme Transcriptome Biogenouest<sup>®</sup>-IBiSA, Rennes, France

(18) Service de Génétique Médicale, CHU Hôpital Sud, Rennes, France

(19) Laboratoire de Génétique Médicale, Hôpital Jeanne de Flandre, CHRU de Lille, France

Keys words: 17q21.31 microdeletion, *MAPT*, mental retardation

Address for correspondence: Christèle Dubourg

Laboratoire de Génétique Moléculaire

CHU Pontchaillou

2 rue Henri Le Guilloux

35033 Rennes cedex

Tel: +33 299 28 98 29

Fax : +33 299 28 92 48

E-mail: [christele.dubourg@chu-rennes.fr](mailto:christele.dubourg@chu-rennes.fr)

## Abstract

Chromosome 17q21.31 microdeletion was one of the first genomic disorders identified by chromosome microarrays. We report here the clinical and molecular characterization of a new series of 14 French patients with this microdeletion syndrome. The most frequent clinical features were hypotonia, developmental delay and facial dysmorphism, but scaphocephaly, prenatal ischemic infarction and perception deafness were also described. Genotyping of the parents showed that the parent from which the abnormality was inherited carried the H2 inversion polymorphism, confirming that the H2 allele is necessary, but not sufficient to generate the 17q21.31 microdeletion. Previously reported molecular analyses of patients with 17q21.31 microdeletion syndrome defined a 493 kb genomic fragment that was deleted in most patients after taking into account frequent copy number variations in normal controls, but the deleted interval was significantly smaller (205 kb) in one of our patients, encompassing only the *MAPT*, *STH* and *KIAA1267* genes. As this patient presents the classical phenotype of 17q21.31 syndrome, these data make it possible to define a new minimal critical region of 160.8 kb, strengthening the evidence for involvement of the *MAPT* gene in this syndrome.

## Introduction

Array comparative genomic hybridization (aCGH) has revolutionized the diagnosis of mental retardation through the use of a “reverse phenotyping” approach making it possible to identify recurrent genomic rearrangements before their clinical description [1]. Such techniques led to the recent characterization of novel microdeletion and microduplication syndromes [2,3,4]. A recurrent 17q21.31 microdeletion [Mendelian Inheritance in Man (MIM) #610443], resulting in the loss of a 500 to 650 kb region between low-copy repeat (LCR) regions, was first described in 2006 in mentally retarded individuals with a clearly recognizable clinical phenotype of mental retardation, hypotonia and characteristic facial features [5,6,7]. The complex genomic architecture of this microdeletion, with large clusters of LCRs at the breakpoints, suggested an underlying mechanism of non allelic homologous recombination (NAHR) [8]. A common 900 kb inversion polymorphism occurs in this region, and chromosomes with the inverted fragment in different orientations correspond to two different haplotypes, H1 and H2 [9]. The direct orientation of LCRs flanking the deleted fragment in the H2 haplotype predisposes the offspring to NAHR, favoring the generation of this microdeletion [9]. This mechanism is similar to that described for predisposing inversion polymorphisms in other microdeletion syndromes, such as Williams-Beuren syndrome (WBS), Angelman syndrome, Sotos syndrome [10], and 15q13.3 microdeletion syndrome [11]. For several chromosomal loci subject to NAHR, reciprocal deletion and duplication syndromes have been identified, including WBS and 7q11.23 duplication [12], Smith-Magenis syndrome and Potocki-Lupski syndrome [13], Prader-Willi syndrome/Angelman syndrome and 15q11q13 duplication [14], Velocardiofacial syndrome and 22q11.2 duplication [15]. However, deletions are generated at a higher rate than their reciprocal duplications [16]. The first case of duplication of the 17q21.31 region was not described until 2007 [17], in a patient with severe psychomotor developmental delay, facial dysmorphism,

macrocephaly, abnormally broad fingers and toes and hirsutism. Four other patients with 17q21.31 microduplication and behavior problems and poor social interaction have also recently been reported [18].

With the use of higher resolution arrays, taking frequent copy number variations in normal controls into account, the minimal critical region involved in this 17q21.31 microdeletion syndrome was recently refined to a 424 kb region encompassing at least six genes: *C17orf69*, the corticotropin-releasing hormone receptor 1 gene (*CRHR1*) (MIM #122561), the intramembrane protease 5 gene (*IMP5*) (MIM #608284), the microtubule-associated protein tau gene (*MAPT*) (MIM #157140), the saitohein gene (*STH*) (MIM #607067), and *KIAA1267* [19]. *MAPT* seems to be the most interesting of these genes for further study, because it is strongly expressed in the brain and has been implicated in several neurodegenerative diseases [20].

The largest series of patients with 17q21.31 microdeletion syndromes reported to date was studied by Koolen *et al.* [19], who identified a clinically recognizable phenotype, including developmental delay, childhood hypotonia and facial dysmorphism. This phenotype was recently expanded to include aortic root dilatation, recurrent joint dislocation, conductive hearing loss, dental abnormalities, the persistence of fetal fingertip pads [21], iris-choroid coloboma and partial situs inversus [22].

We present here a new series of 14 patients with the 17q21.31 microdeletion syndrome ascertained through the network of French array CGH platforms (<http://www.renapa.univ-montp1.fr/>) and the BACH database (<https://www.genopole-lille.fr/bach/menu.php>), confirming the described phenotype, refining the minimal critical region and providing further

support for the role of *MAPT* in this syndrome. We also discuss the results of H1/H2 genotyping and parent-of-origin analysis, comparing our results with published findings.

## **Materials and methods**

### *Patients*

A collaborative study involving the French array CGH platforms analyzing patients with mental retardation (MR), dysmorphic features and multiple congenital abnormalities (MCA) was set up for the molecular and clinical characterization of all unpublished French patients carrying the 17q21.31 microdeletion. Molecular cytogenetics analyses of 2672 MR/MCA patients showed that 14 of these patients had a 17q21.31 microdeletion. Informed consent for genetic testing was obtained from all tested patients and their relatives.

### *Molecular cytogenetics*

Two platforms were used for genomic copy number analyses, which were carried out according to the manufacturer's protocol (Agilent Technologies, Santa Clara, CA, USA): the Human Genome CGH Microarray 44K (for all patients except patient 7) and 244K (patient 7). Data were processed with Feature Extraction (v. 9.1) software and results were interpreted with CGH analysis (v. 4.0) software (Agilent®). When a 17q21.31 deletion was identified by array CGH, the microrearrangement was confirmed either by FISH with various probes (RP11-597L17 or RP11-656O14 targeting *CRHRI*, RP11-413P22, RP11-669E4 or RP11-769P22 targeting *MAPT*) or by multiplex ligation-dependent probe amplification (MLPA) with the SALSA kit P245 from MRC-Holland (Amsterdam, the Netherlands) ([www.mlpa.com](http://www.mlpa.com)).

### *Genotyping for H1 and H2, and parent-of-origin analysis*

When material from the parents was available, a family study was performed (12 patients). H1/H2 genotyping was carried out for individuals with the 17q21.31 deletion and their parents, by PCR amplification of a region encompassing a potential 238 bp deletion in the intron 9 of the *MAPT* gene associated with the H2 background [9,19].

The parental origin of the chromosome with the deletion was determined with the *DG17S142* dinucleotide marker and three to five additional variable number tandem repeats within the deleted region, together with two flanking short tandem repeats, *D17S810* and *D17S920* [19]. Marker analyses were carried out according to standard procedures and data were interpreted with GeneMapper (v. 4.0) software (Applied Biosystems, Foster City, CA, USA).

## Results

### *Array CGH results*

All the patients studied had an overlapping heterozygous deletion of the 17q21.31 interval (Fig. 1). Oligonucleotide array CGH data identified a 493 kb region (chr17:41,073,486-41,566,599) (hg18-build36) as deleted in 11 affected individuals. In one patient (patient 7), the deletion was larger, being somewhere between 675 kb and 810 kb in size and extending to the distal part of the chromosome. However, the distal breakpoint region was a site of frequent copy number variation (CNV) in normal controls. The proximal breakpoint was also found to be located in a variable region. This may account for the subtle shifts in the breakpoints observed, as in patient 10 (chr17:41,212,860-41,566,599) (hg18-build36). By contrast, patient 3 had a significantly smaller deletion, of only 205 kb (chr17:41,310,123-41,515,622) (hg18-build36).



FISH studies confirmed the 17q21.31 deletion in patients 1, 2 and 4 to 13, with RP11-597L17 and/or RP11-656O14, RP11-413P22, RP11-669E4 or RP11-769P22 found to be deleted. The deletion identified in patient 3 was validated by MLPA, which confirmed the presence of a heterozygous deletion for the two probes targeting *MAPT* exons 8 and 11, whereas the signal obtained for the *CRHR1* probe (exon 8) showed that this gene was not deleted (data not shown).

#### *Clinical description* (Table 1)

The most typical clinical features of 17q21.31 syndrome include hypotonia, developmental delay, overly friendly/amiable behavior and facial dysmorphism with a long face, a tubular or pear-shaped nose and a bulbous nasal tip (Fig. 2). The principal clinical characteristics of patients 1 to 14 are described in Table 1. Additional features are described below.

**Patient 1** is the first and only child of unrelated parents. The pregnancy was complicated by intrauterine growth retardation (IUGR), which was interpreted as originating from a vascular cause. This child, a boy, was born at 39 weeks by cesarean section. Early problems included an inability to suck effectively and feeding problems, with enterocolitis causing ulcer and necrosis. Molecular analysis of the *GJB2* and *GJB6* genes were performed because of deafness, but no alteration was detected.

**Patient 2** is the second child of Moroccan and Breton parents. Prenatal imaging showed right hydronephrosis. A ventricular septal defect (VSD) observed at birth regressed spontaneously. This patient presented bronchiolitis and pyelonephritis at the age of six months, feeding problems, fainting due to hypotonia at the age of nine months, and epileptic seizures at the age of three years. He has a short stature and low weight (-2SD) and is prone to

frequent falls. He has discrete aortic dilatation, with measurements at the upper limit of the normal range (27.3 mm aortic sinus at 15 ½ years of age, 28.5 mm at 17 years).

**Patient 3** is the first child of healthy unrelated parents. The pregnancy was characterized by a hygroma colli during the first trimester and multicystic right renal dysplasia. An ischemic infarction of the superficial middle cerebral artery territory, on the right side, was diagnosed in the neonatal period and probably occurred before birth. It resulted in fronto-parietal ischemic sequelae, initially in the form of symptomatic ipsilateral temporo-occipital hemorrhage, subsequently progressing to cortico-subcortical atrophy. Explorations carried out during and after the early postnatal period demonstrated significant asymmetry in the development of the two hemispheres of the brain. At the age of 16 months, this patient still presents axial hypotonia, with an unstable sitting posture and retropulsion episodes.

**Patient 4** is a quiet child. Skin lesions were reported for this patient, with numerous nevi, including a hairy nevus on the face, a depigmented patch of the base of the neck and a pigmented spot on the left nipple.

**Patient 5** was born after a pregnancy complicated by IUGR. This patient, born to patients from a gypsy background, had a number of skin lesions, including generalized hyperpigmentation, a pigmented spot on the left side of the front of the neck, a depigmented patch above the left nipple and numerous nevi, including one on the right sole and another on the left hand.

**Patient 6** presented initial hypotonia, followed by seizures at the age of 14 months. His testes were located in the inguinal canal.

**Patient 7** was delivered at 31 weeks of gestation, by cesarean section due to acute fetal distress. Scaphocephaly was recorded, leading to the detection of metopic craniosynostosis at the age of two years.

**Patient 8** presented feeding difficulties in the neonatal period. Severe speech dyspraxia became apparent in infancy.

**Patient 9** is the second child of non consanguineous parents. She was hypotonic as a baby, with tongue protrusion. She also presented feeding difficulties and constipation.

**Patient 10** is the third child of unrelated parents. The pregnancy was uncomplicated. A bilateral cleft lip was discovered at birth, with no damage to the alveolar ridge or palate. This patient is very sociable and cheerful. Her skin is very dry.

**Patient 11** presented delayed development of axial tonus at four months. Seizures first appeared at the age of eight months, with temporo-occipital foci.

**Patient 12** presented hypotonia and feeding difficulties during the neonatal period. He also displayed cryptorchidism requiring surgical treatment.

**Patient 13** presented developmental delay, more serious for psychomotor development than for language.

For **patient 14**, the neonatal period was marked by feeding difficulties and hypotonia.

### *Genotyping*

The genotyping of 24 parents (in 12 families) showed that the deletion was inherited from the mother in seven families and from the father in four families. In the remaining family, the panel of repeat markers across the deleted region could not distinguish between the parental chromosomes (Table 2).

Fifteen of the 24 parents tested were heterozygous for the H2 inversion, whereas four were homozygous for this inversion. The parent from which the inversion originated carried the H2 inversion polymorphism in at least a heterozygous state.

## Discussion

All the patients with 17q21.31 microdeletion syndrome reported here were identified by array CGH screening, by the network of French array CGH platforms, of large heterogeneous cohorts of patients with mental retardation. The calculated prevalence of 17q21.31 syndrome in our French cohort was 0.52% (14 of the 2672 patients tested), which is of the same order of magnitude as previous estimates (0.64% for Koolen *et al.* [19], 0.5% for Sharkey *et al.* [22]).

Given the copy number polymorphisms located at either end of the deleted region, we investigated the size of the deletion in 11 of our patients conforming to the DECIPHER description of 17q21.31 syndrome as a standard deletion extending from 40.99 to 41.57 Mb. However, the critical region of 17q21.31 was recently refined and narrowed to a 424 kb genomic interval (chr17:41,046,729-41,470,954, hg18) by analyses based on SNP arrays and ultra-high density custom oligonucleotide arrays targeting the 17q21.31 region and excluding frequent copy number variations in normal controls [19]. In our patient 3 with classical clinical characteristics, including facial features (Fig. 2), a smaller, partially overlapping deletion was observed (chr17:41,310,123-41,515,622, hg18-build36). This deletion encompasses only *MAPT*, *STH* and *KIAA1267*, leaving the patient with two copies of the *CRHR1* gene, but the phenotype of this patient was no milder than that of the other patients. Comparison of this 205 kb deletion with the 424 kb critical region described by Koolen *et al.* [19] defined a new minimal critical region of 160.8 kb (chr17:41,310,123-41,470,954, hg18), providing strong evidence for the involvement of the *MAPT* (microtubule-associated protein Tau) gene (MIM #157140) in this syndrome. Gain-of-function mutations in *MAPT* have been identified in neurodegenerative diseases, such as autosomal dominant frontal-temporal dementia with parkinsonism [23,24], supranuclear bulbar palsy and corticobasal

degeneration [25], or Alzheimer's disease [26], in which abnormal deposition of insoluble tau protein is observed, with a decrease in the concentration of the normal soluble tau molecule in patients' brains, affecting the assembly, dynamic behavior and spatial organization of microtubules in neurons and glial cells [27]. The microdeletion event observed in 17q21.31 syndrome results in *MAPT* haploinsufficiency. In mice, *Mapt* haploinsufficiency in tau  $-/-$  animals affects microtubule density and stability in small-caliber axons [28], resulting in a murine phenotype including muscle weakness in a wire-hanging test, hyperactivity in a novel environment and impairment in contextual fear conditioning [29]. However, screening for mutations in *MAPT* in 122 individuals with a phenotype suggestive of 17q21.31 syndrome identified no disease-associated variants [19].

The facial features described by other groups [19,21] was found in our patients, but become increasingly obvious with age. Consistent with one patient described by Tan *et al.* [21], two of our patients presented scaphocephaly revealing metopic craniosynostosis. All our patients were hypotonic, with global developmental delay predominant over language problems. Other defects (ophthalmologic, cardiac, urologic, central nervous system, joint hypermobility, hip dysplasia) were commonly noted. Prenatal ischemic infarction was diagnosed in patient 3, as also reported for one of the patients described by Koolen *et al.* [19]. Tan *et al.* [21] reported hearing defects resulting from chronic otitis. One of our patients (patient 1) was deaf, but this problem was due to a neurosensorial defect rather than conductive problems, despite the occurrence of numerous ENT infections in early infancy.

The 17q21.31 genomic region contains a 900 kb inversion polymorphism generating two highly divergent haplotypes, H1 and H2, that are transmitted *en bloc* [9]. The frequency of the H2 lineage has been reported to be about 20% in the European population, whereas this

haplotype is rare in Africans and almost never detected in East Asians. We indirectly identified this H2 inversion in 23 of the 48 chromosomes from parents tested and, for each trio, the parent from which the chromosome 17 deletion was inherited carried the H2 inversion polymorphism in either the homozygous or heterozygous state, giving a significantly higher frequency. Seven of the deletions were of maternal origin and four were of paternal origin. Combining these data with those obtained by Koolen *et al.* [19], we can assume that there is no significant bias in the parental origin of the chromosome bearing the deletion. Unfortunately, we were unable to obtain DNA from the parents of patient 3. The H2 haplotype confers a genomic architecture in which LCR subunits are directly oriented, mediating the NAHR event leading to deletion [30]. However, as the frequency of 17q21.31 deletion in the offspring of H2 inversion carriers is low, the H2 allele is necessary, but not sufficient to generate the 17q21.31 deletion [19].

Considering our French series of 14 patients with the 17q21.31 microdeletion syndrome and previous reports of 22 [19] and 11 patients [21], it is clear that this microdeletion syndrome is clinically significant. Our study also narrowed the definition of the minimal deleted region to a restricted interval of 160.8 kb, strengthening the implication of the *MAPT* gene in this syndrome.

## Acknowledgments

We thank all the staff of the Biogenouest<sup>®</sup>-IBiSA (Rennes) transcriptomics platform. We also thank our colleagues for referring patients, and the patients and their families for participating in this study. This research was supported by grants from FEDER, DHOS and STIC 2004/EGMAR.

## Electronic databases

Network of the French array CGH platforms: Réseau AChro-Puce (*Réseau d'Analyse Chromosomique sur Puces à ADN*) <http://www.renapa.univ-montp1.fr/>

BACH database: <https://www.genopole-lille.fr/bach/menu.php>

UCSC Genome Browser on Human March 2006 Assembly – hg18:  
<http://genome.ucsc.edu/cgi-bin/hgGateway?org=human>.

Database for Genomic Variants: <http://projects.tcag.ca/variation>

DECIPHER Consortium: <https://decipher.sanger.ac.uk/>

## References

- [1 ] A.M. Slavotinek, Novel microdeletion syndromes detected by chromosome microarrays. Hum. Genet.124 (2008):1-17.
- [2 ] B.B. de Vries, R. Pfundt, M. Leisink, D.A. Koolen, L.E. Vissers, I.M. Janssen, S. van Reijmersdal, W.M. Nillesen, E.H. Huys, N. de Leeuw, D. Smeets, E.A. Sistermans, T. Feuth, C.M. van Ravenswaaij-Arts, A.G. van Kessel, E.F. Schoenmakers, H.G. Brunner, J.A. Veltman, Diagnostic genome profiling in mental retardation. Am. J. Hum. Genet. 77 (2005) 606-616.
- [3 ] P. Stankiewicz, A.L. Beaudet, Use of array CGH in the evaluation of dysmorphology, malformations, developmental delay, and idiopathic mental retardation. Curr. Opin. Genet. Dev. 17 (2007) 182-192.
- [4 ] A.M. Slavotinek, Novel microdeletion syndromes detected by chromosome microarrays. Hum. Genet. 124 (2008) 1-17.
- [5 ] D.A. Koolen, L.E. Vissers, R. Pfundt, N. de Leeuw, S.J. Knight, R. Regan, R.F. Kooy, E. Reyniers, C. Romano, M. Fichera, A. Schinzel, A. Baumer, B.M. Anderlid, J. Schoumans, N.V. Knoers, A.G. van Kessel, E.A. Sistermans, J.A. Veltman, H.G. Brunner, B.B. de Vries, A new chromosome 17q21.31 microdeletion syndrome associated with a common inversion polymorphism. Nat. Genet. 38 (2006) 999-1001.
- [6 ] C. Shaw-Smith, A.M. Pittman, L. Willatt, H. Martin, L. Rickman, S. Gribble, R. Curley, S. Cumming, C. Dunn, D. Kalaitzopoulos, K. Porter, E. Prigmore, A.C. Krepischi-Santos, M.C. Varela, C.P. Koiffmann, A.J. Lees, C. Rosenberg, H.V. Firth, R. de Silva, N.P. Carter, Microdeletion encompassing MAPT at chromosome 17q21.3 is associated with developmental delay and learning disability. Nat. Genet. 38 (2006) 1032-1037.
- [7 ] A.J. Sharp, S. Hansen, R.R. Selzer, Z. Cheng, R. Regan, J.A. Hurst, H. Stewart, S.M. Price, E. Blair, R.C. Hennekam, C.A. Fitzpatrick, R. Segraves, T.A. Richmond, C. Guiver, D.G. Albertson, D. Pinkel, P.S. Eis, S. Schwartz, S.J. Knight, E.E. Eichler, Discovery of previously



unidentified genomic disorders from the duplication architecture of the human genome. *Nat. Genet.* 38 (2006) 1038-1042.

- [8 ] P. Stankiewicz, J.R. Lupski, Genome architecture, rearrangements and genomic disorders. *Trends Genet.* 18 (2002) 74-82.
- [9 ] H. Stefansson, A. Helgason, G. Thorleifsson, V. Steinthorsdottir, G. Masson, J. Barnard, A. Baker, A. Jonasdottir, A. Ingason, V.G. Gudnadottir, N. Desnica, A. Hicks, A. Gylfason, D.F. Gudbjartsson, G.M. Jonsdottir, J. Sainz, K. Agnarsson, B. Birgisdottir, S. Ghosh, A. Olafsdottir, J.B. Cazier, K. Kristjansson, M.L. Frigge, T.E. Thorgeirsson, J.R. Gulcher, A. Kong, K. Stefansson, A common inversion under selection in Europeans. *Nat. Genet.* 37 (2005) 129-137.
- [10 ] L. Feuk, A.R. Carson, S.W. Scherer, Structural variation in the human genome. *Nat. Rev. Genet.* 7 (2006) 85-97.
- [11 ] A.J. Sharp, H.C. Mefford, K. Li, C. Baker, C. Skinner, R.E. Stevenson, R.J. Schroer, F. Novara, G.M. De, R. Ciccone, A. Broome, I. Casuga, Y. Wang, C. Xiao, C. Barbacioru, G. Gimelli, B.D. Bernardina, C. Torniero, R. Giorda, R. Regan, V. Murday, S. Mansour, M. Fichera, L. Castiglia, P. Failla, M. Ventura, Z. Jiang, G.M. Cooper, S.J. Knight, C. Romano, O. Zuffardi, C. Chen, C.E. Schwartz, E.E. Eichler, A recurrent 15q13.3 microdeletion syndrome associated with mental retardation and seizures. *Nat. Genet.* 40 (2008) 322-328.
- [12 ] M.J. Somerville, C.B. Mervis, E.J. Young, E.J. Seo, M. del Campo, S. Bamforth, E. Peregrine, W. Loo, M. Lilley, L.A. Pérez-Jurado, C.A. Morris, S.W. Scherer, L.R. Osborne, Severe expressive-language delay related to duplication of the Williams-Beuren locus. *N. Engl. J. Med.* 16 (2005) 1694-1701.
- [13 ] L. Potocki, K.S. Chen, S.S. Park, D.E. Osterholm, M.A. Withers, V. Kimonis, A.M. Summer, W.S. Meschino, K. Anyane-Yeboah, C.D. Kashork, L.G. Shaffer, J.R. Lupski, Molecular mechanism for duplication 17p11.2-the homologous recombination reciprocal of the Smith-Magenis microdeletion. *Nat. Genet.* 24 (2000) 84-87.

- [14 ] F.L. Long, D.P. Duckett, L.J. Billam, D.K. Williams, J.A. Crolla, Triplication of 15q11-q13 with inv dup(15) in a female with developmental delay. *J. Med. Genet.* 35 (1998) 425-428.
- [15 ] L. Edelmann, R.K. Pandita, E. Spiteri, B. Funke, R. Goldberg, N. Palanisamy, R.S. Chaganti, E. Magenis, R.J. Shprintzen, B.E. Morrow, A common molecular basis for rearrangement disorders on chromosome 22q11. *Hum. Mol. Genet.* 8 (1999) 1157-1167.
- [16 ] D.J. Turner, M. Miretti, D. Rajan, H. Fiegler, N.P. Carter, M.L. Blayney, S. Beck, M.E. Hurles, The rates of *de novo* meiotic deletions and duplications causing several genomic disorders in the male germline. *Nat. Genet.* 40 (2008) 90-95.
- [17 ] M. Kirchhoff, A.M. Bisgaard, M. Duno, F.J. Hansen, M. Schwartz, A 17q21.31 microduplication, reciprocal to the newly described 17q21.31 microdeletion, in a girl with severe psychomotor developmental delay and dysmorphic craniofacial features. *Eur. J. Med. Genet.* 50 (2007) 256-263.
- [18 ] B. Grisart, L. Willatt, A. Destrée, J.P. Fryns, K. Rack, T. de Ravel, J. Rosenfeld, J.R. Vermeesch, C. Verellen-Dumoulin, R. Sandford, 17q21.31 microduplication patients are characterised by behavioural problems and poor social interaction. *J. Med. Genet.* 46 (2009) 524-530.
- [19 ] D.A. Koolen, A.J. Sharp, J.A. Hurst, H.V. Firth, S.J. Knight, A. Goldenberg, P. Saugier-veber, R. Pfundt, L.E. Vissers, A. Destrée, B. Grisart, L. Rooms, N. Van der Aa, M. Field, A. Hackett, K. Bell, M.J. Nowaczyk, G.M. Mancini, P.J. Poddighe, C.E. Schwartz, E. Rossi, M. De Gregori, L.L. Antonacci-Fulton, M.D. 2<sup>nd</sup> McLellan, J.M. Garrett, M.A. Wiechert, T.L. Miner, S. Crosby, R. Ciccone, L. Willatt, A. Rauch, M. Zenker, S. Aradhya, M.A. Manning, T.M. Strom, J. Wagenstaller, A.C. Krepischi-Santos, A.M. Vianna-Morgante, C. Rosenberg, S.M. Price, H. Stewart, C. Shaw-Smith, H.G. Brunner, A.O. Wilkie, J.A. Veltman, O. Zuffardi, E.E. Eichler, B.B. de Vries, Clinical and molecular delineation of the 17q21.31 microdeletion syndrome. *J. Med. Genet.* 45 (2008) 710-720.
- [20 ] R. Rademakers, M. Cruts, C. van Broeckhoven, The role of tau (MAPT) in frontotemporal dementia and related tauopathies. *Hum. Mut.* 24 (2004) 277-295.

- [21 ] T.Y. Tan, S. Aftimos, L. Worgan, R. Susman, M. Wilson, S. Ghedia, E.P. Kirk, D. Love, A. Ronan, A. Darmanian, A. Slavotinek, J. Hogue, J.B. Moeschler, J. Ozmore, R. Widmer, R. Savarirayan, G. Peters, Phenotypic expansion and further characterisation of the 17q21.31 microdeletion syndrome. *J. Med. Genet.* 46 (2009) 480-489.
- [22 ] F.H. Sharkey, N. Morrison, R. Murray, J. Iremonger, J. Stephen, E. Maher, J. Tolmie, A.P. Jackson, 17q21.31 microdeletion syndrome: further expanding the clinical phenotype. *Cytogenet. Genome Res.* 127 (2009) 61-66.
- [23 ] M. Hutton, C.L. Lendon, P. Rizzu, M. Baker, S. Froelich, H. Houlden, S. Pickering-Brown, S. Chakraverty, A. Isaacs, A. Grover, J. Hackett, J. Adamson, S. Lincoln, D. Dickson, P. Davies, R.C. Petersen, M. Stevens, E. de Graaf, E. Wauters, J. van Baren, M. Hillebrand, M. Joosse, J.M. Kwon, P. Nowotny, L.K. Che, J. Norton, J.C. Morris, L.A. Reed, J. Trojanowski, H. Basun, L. Lannfelt, M. Neystat, S. Fahn, F. Dark, T. Tannenberg, P.R. Dood, N. Hayward, J.B. Kwok, P.R. Schofield, A. Andreadis, J. Snowden, D. Craufurd, D. Neary, F. Owen, B.A. Oostra, J. Hardy, A. Goate, J. van Swieten, D. Mann, T. Lynch, P. Heutink, Association of missense and 5'-splice-site mutations in tau with the inherited dementia FTDP-17. *Nature* 393 (1998) 702-705.
- [24 ] I. D'Souza, P. Poorkaj, M. Hong, D. Nochlin, V.M. Lee, T.D. Bird, G.D. Schellenberg, Missense and silent tau gene mutations cause frontotemporal dementia with parkinsonism-chromosome 17 type, by affecting multiple alternative RNA splicing regulatory elements. *Proc. Natl. Acad. Sci. USA* 96 (1999) 5598-5603.
- [25 ] A.M. Pittman, A.J. Myers, P. Abou-Sleiman, H.C. Fung, M. Kaleem, L. Marlowe, J. Duckworth, D. Leung, D. Williams, L. Kilford, N. Thomas, C.M. Morris, D. Dickson, N.W. Wood, J. Hardy, A.J. Lees, R. de Silva, Linkage disequilibrium fine mapping and haplotype association analysis of the tau gene in progressive supranuclear palsy and corticobasal degeneration. *J. Med. Genet.* 42 (2005) 837-846.
- [26 ] A.J. Myers, M. Kaleem, L. Marlowe, A.M. Pittman, A.J. Lees, H.C. Fung, J. Duckworth, D. Leung, A. Gibson, C.M. Morris, R. de Silva, J. Hardy, The H1c haplotype at

the MAPT locus is associated with Alzheimer's disease. *Hum. Mol. Genet.* 14 (2005) 2399-2404.

[27 ] M. Hutton, Molecular genetics of chromosome 17 tauopathies. *Ann. NY Acad. Sci.* 920 (2000) 63-73.

[28 ] Harada, K. Oguchi, S. Okabe, J. Kuno, S. Terada, T. Ohshima, R. Sato-Yoshitake, Y. Takei, T. Noda, N. Hirokawa, Altered microtubule organization in small-calibre axons of mice lacking tau protein. *Nature* 369 (1994) 488-491.

[29 ] S. Ikegami, A. Harada, N. Hirokawa, Muscle weakness, hyperactivity, and impairment in fear conditioning in tau-deficient mice. *Neurosci. Lett.* 279 (2000) 123-132.

[30 ] J.R. Lupski, Genome structural variation and sporadic disease traits. *Nat. Genet.* 38 (2006) 974-976.

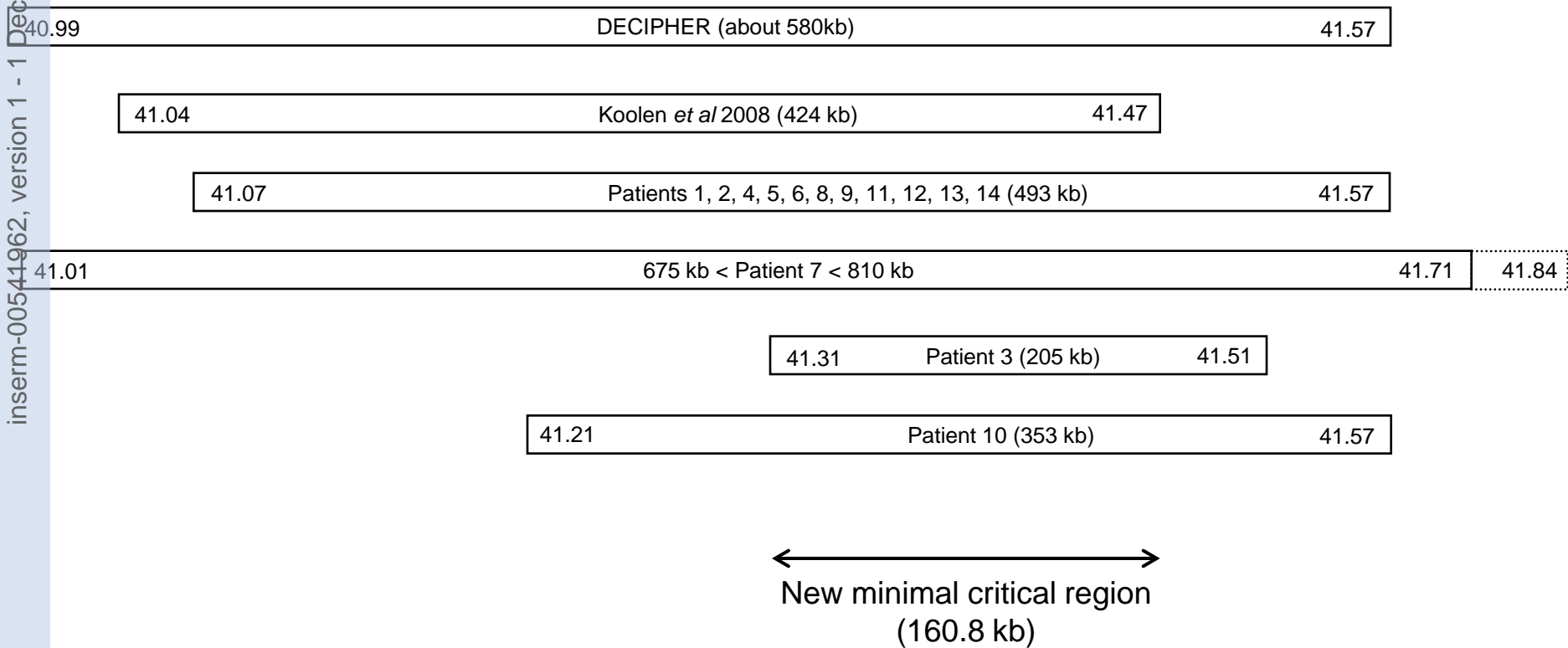
## Figure legends

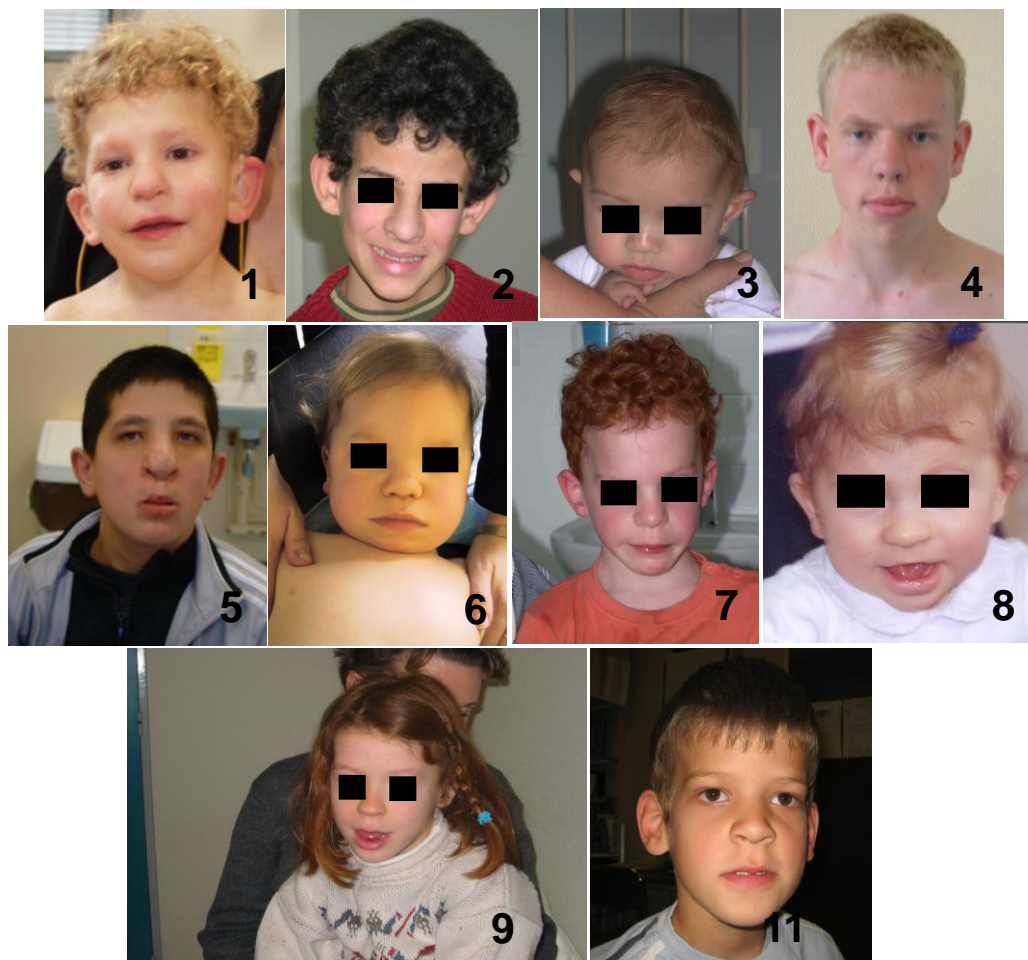**Figure 1.** Schematic diagram of 17q21.31 rearrangements, indicating relative sizes and positions, as currently defined within the DECIPHER Consortium, described by Koolen *et al.* 2008 and observed in 14 patients on the basis of array CGH data. Beneath the 17q21.31 chromosome map, the two right-angled double-headed arrows indicate sites of frequent copy number variation (CNV) in normal controls, often overlapping the proximal and distal ends of classical deletions. Below the various patients with deletions, the double-headed arrow shows the new minimal critical region of 160.8 kb, providing further evidence for the involvement of *MAPT* in 17q21.31 microdeletion syndrome.

**Figure 2.** Facial photographs of ten patients with 17q21.31 deletions: from left to right, patients 1, 2, 3, 4 in the upper panel; patients 5, 6, 7, 8 in the middle panel; patients 9 and 11 in the lower panel.

**Table I.** Clinical characteristics of patients with 17q21.31 deletions

**Table II.** Genotyping for H1/H2 and parent-of-origin results





	Patient 1	Patient 2	Patient 3	Patient 4	Patient 5	Patient 6	Patient 7
Age at time of report	7 years	18 years	1 year	> 18 years	14 years	5 years	5 years
Sex	M	M	F	M	M	M	M
Perinatal							
Birth weight	2710 g at 39 WG (3 <sup>rd</sup> -10 <sup>th</sup> percentile)	2990 g at 40 WG (10 <sup>th</sup> percentile)	2360 g at 40WG (< 3 <sup>rd</sup> percentile)	3400 g at 42 WG (25 <sup>th</sup> percentile)	2270 g at 38 WG (3 <sup>rd</sup> percentile)	2300 g at 37 WG (3 <sup>rd</sup> percentile)	1260 g at 31 WG (10 <sup>th</sup> -25 <sup>th</sup> percentile)
Birth length	47 cm (10 <sup>th</sup> percentile)	45,5 cm (<3 <sup>rd</sup> percentile)	46 cm (< 3 <sup>rd</sup> percentile)	50 cm (25 <sup>th</sup> percentile)	47 cm (10 <sup>th</sup> -25 <sup>th</sup> percentile)	47 cm (10 <sup>th</sup> -25 <sup>th</sup> percentile)	38 cm (10 <sup>th</sup> -25 <sup>th</sup> percentile)
Birth HC	34 cm (50 <sup>th</sup> percentile)	35 cm (50 <sup>th</sup> percentile)	34 cm (25 <sup>th</sup> -50 <sup>th</sup> percentile)	36 cm (50 <sup>th</sup> -75 <sup>th</sup> percentile)	34 cm (25 <sup>th</sup> -50 <sup>th</sup> percentile)	32.5 cm (25 <sup>th</sup> percentile)	28 cm (10 <sup>th</sup> -25 <sup>th</sup> percentile)
Hypotonia	+	+	+			+	+
Developmental delay	+	+	+	+	+		+
		Walked at 21 months					
Language delay	+	+	+				+
Overly friendly disposition	+		+				+
		Behavioral problems					ADHD
Facial features	Large and broad nasal tip, full philtral pillars, large and low-set ears, often open mouth, thin upper lip, hypermetropia, astigmatism	High and broad forehead, large and protruding ears, gingival pads, mild myopia	Bilateral epicanthus, hypertelorism, abnormal ears, tongue protrusion	Synophrys, prognathism, absence of upper incisors, thick lips, large ears, eye nystagmiiform movements and lens puncture	Cleft lip and palate, hypertelorism, bilateral epicanthus, broad nasal root	Hypertelorism, epicanthus, forehead protrusion, strabism, everted lip, hypoplastic columella	Bulbous nasal tip, low-set ears, short philtrum, upslanting palpebral fissures, astigmatism
Skin, nails, hair	Silky skin	Elastic skin		Numerous nevi, abnormal pigmentation	Numerous nevi, abnormal pigmentation		Silky skin
Feeding problems	+	+	+	-			
CNS defects		Recurrent seizures between 3 and 5 years of age	-	MRI: broad lateral ventricles	MRI: thinning of the posterolateral third of the corpus	Seizures at 14 months. MRI: thin corpus	MRI: partial agenesis of the corpus callosum,



		MRI: dysgenesis of corpus callosum			callosum, abnormally shaped hippocampus	callosum, bilateral subependymal heterotopia	mild ventricle broadening
Cranial abnormalities	Microcephaly (- 3 SD)		Scaphocephaly	-		-	Scaphocephaly Metopic craniostenosis
Heart defects	ASD, VSD	VSD, aortic dilatation	ASD, VSD	-		-	-
Kidney and urologic defects	Shawl scrotum	Right hydronephrosis, bilateral cryptorchidism, phimosis	Right multicystic renal dysplasia		Bilateral cryptorchidism	Bilateral cryptorchidism	Hypospadias
Spine abnormalities		-		Scoliosis			-
Musculoskeletal problems	Joint hyperlaxity, hip dysplasia, digital pads, toe deviation	Hyperlaxity, numerous fractures and sprains		-			Mild finger and wrist laxity
Deafness	Bilateral perception deafness	-	-	-	-	-	-
Other	Chronic constipation, bilateral inguinal hernia, chronic ENT infections	Anus fistula Chronic ENT infections					

	Patient 8	Patient 9	Patient 10	Patient 11	Patient 12	Patient 13	Patient 14
Age at time of report	1 year		14 years	7 years	13 years	17 years	8 years
Sex	F	F	F	M	M	M	F
Perinatal Birth weight	2600 g et 39 WG (3 <sup>rd</sup> -10 <sup>th</sup> percentile)	3170 g at 39 WG (25 <sup>th</sup> -50 <sup>th</sup> percentile)	3300 g at 39 WG (50 <sup>th</sup> -75 <sup>th</sup> percentile)	3300g at 40 WG (25 <sup>th</sup> -50 <sup>th</sup> percentile)	2360g at 39.5 WG (<3 <sup>rd</sup> percentile)	2700 g at 38 WG (10 <sup>th</sup> -25 <sup>th</sup> percentile)	2450 g at 38 WG (10 <sup>th</sup> -25 <sup>th</sup> percentile)
Birth length		49 cm (50 <sup>th</sup> percentile)	51 cm (75 <sup>th</sup> -90 <sup>th</sup> percentile)	50 cm (25 <sup>th</sup> -50 <sup>th</sup> percentile)		48 cm (25 <sup>th</sup> percentile)	48 cm (50 <sup>th</sup> -75 <sup>th</sup> percentile)
Birth HC		33 cm (10 <sup>th</sup> -25 <sup>th</sup> percentile)	36 cm (90 <sup>th</sup> percentile)	35 cm (50 <sup>th</sup> percentile)		34 cm (25 <sup>th</sup> -50 <sup>th</sup> percentile)	33 cm (25 <sup>th</sup> -50 <sup>th</sup> percentile)
Hypotonia	+	+	+	+	+	-	+
Developmental delay	+	+ Walked at 24 months	+ Walked at 18 months	+ Walked at 24 months	+ Walked at 24 months	+	+
Language delay	+	+	+	+	+	+	+
Overly friendly disposition	+	+	+	+ ADHD	+	+	+
Facial features	Low everted lip, bulbous nasal tip, low-set ears	Flattened nose, everted lower lip, tongue protrusion, abnormal ears	Long face, shaggy eyebrows, downslanting palpebral fissures, bulbous nasal tip, bilateral cleft lip, long and fleshy ear lobes	“Pear-shaped” nose, long face, low-set and large ears, strabism	Tubular “pear-shaped” nose, long face, low-set ears, strabism, hypermetropia	Tubular “pear-shaped” nose, long face, hypermetropia, astigmatism, small palpebral fissures	Tubular “pear-shaped” nose, long face
Skin, nails, hair	Hypopigmentation		Dry with keratosis				
Feeding problems	+	+	-	-	+	-	+
CNS defects	-	-	-	+ First seizures at 8 months	-	Epilepsy	Seizures at 7 years but normal EEG result
Cranial abnormalities	-	Microcephaly	-	HC at +1.66SD at 8 years	-	Macrocrania	

Heart defects	ASD	-	-	-	-	-	ASD
Kidney and urologic malformations	Vesico-ureteric reflux	-	-	-	Cryptorchidism	Unilateral cryptorchidism	-
Spine abnormalities	-	-	-	-	-	-	-
Musculoskeletal problems	Congenital hip dysplasia		Bilateral hip dysplasia, kneecap dislocation, misimplanted and long toes	Joint laxity	Pectus excavatum		Hyperlaxity, long and slender fingers
Deafness	-	-	-	-	-	-	-
Other		Chronic constipation					

ADHD, attention deficit hyperactivity disorder; ASD, atrial septal defect; CNS, central nervous system; ENT, ear, nose and throat; F, female; M, male; HC, Head circumference; SD, standard deviation; VSD, ventricular septal defect; WG, weeks of gestation

A blank square means that the characteristic was not assessed, a “minus” signs (-) indicates that it was absent.

Patient	Father	Mother	Parent-of-origin
1	H1/H2	<b>H1/H2</b>	Maternal
2	H1/H2	<b>H1/H2</b>	Maternal
4	H2/H2	<b>H1/H2</b>	Maternal
5	<b>H2/H2</b>	H1/H1	Paternal
6	H1/H1	<b>H1/H2</b>	Maternal
7	H1/H1	<b>H1/H2</b>	Maternal
8	<b>H2/H2</b>	H1/H2	Paternal
9	H1/H2	H2/H2	Non informative
10	H1/H2	<b>H1/H2</b>	Maternal
12	H1/H1	<b>H1/H2</b>	Maternal
13	<b>H1/H2</b>	H1/H1	Paternal
14	<b>H1/H2</b>	H1/H2	Paternal