



## Gender influence on defecographic abnormalities in patients with posterior pelvic floor disorders.

Céline Savoye-Collet, Guillaume Savoye, Edith Koning, Anne-Marie Leroi, Jean-Nicolas Dacher

### ► To cite this version:

Céline Savoye-Collet, Guillaume Savoye, Edith Koning, Anne-Marie Leroi, Jean-Nicolas Dacher. Gender influence on defecographic abnormalities in patients with posterior pelvic floor disorders.. World Journal of Gastroenterology, 2010, 16 (4), pp.462-6. inserm-00477411

**HAL Id: inserm-00477411**

**<https://inserm.hal.science/inserm-00477411>**

Submitted on 29 Apr 2010

**HAL** is a multi-disciplinary open access archive for the deposit and dissemination of scientific research documents, whether they are published or not. The documents may come from teaching and research institutions in France or abroad, or from public or private research centers.

L'archive ouverte pluridisciplinaire **HAL**, est destinée au dépôt et à la diffusion de documents scientifiques de niveau recherche, publiés ou non, émanant des établissements d'enseignement et de recherche français ou étrangers, des laboratoires publics ou privés.

## Gender influence on defecographic abnormalities in patients with posterior pelvic floor disorders

Céline Savoye-Collet, Guillaume Savoye, Edith Koning, Anne-Marie Leroi, Jean-Nicolas Dacher

Céline Savoye-Collet, Edith Koning, Jean-Nicolas Dacher, Radiology Department, QUANT-IF LITIS EA 4108, Rouen University Hospital Charles Nicolle, 1 rue de Germont, F-76031 Rouen, France

Guillaume Savoye, Gastroenterology Department, ADEN EA 4311, Rouen University Hospital Charles Nicolle, 1 rue de Germont, F-76031 Rouen, France

Anne-Marie Leroi, Physiology Department, ADEN EA 4311, Rouen University Hospital Charles Nicolle, 1 rue de Germont, F-76031 Rouen, France

**Author contributions:** Savoye-Collet C designed the research, collected and analyzed the data; Savoye-Collet C and Koning E performed the procedures; Savoye-Collet C and Savoye G edited the paper; All authors cooperated in the final version of the manuscript.

**Correspondence to:** Céline Savoye-Collet, MD, Radiology Department, Rouen University Hospital Charles Nicolle, 1 rue de Germont, F-76031 Rouen, France. [savoyecel@hotmail.com](mailto:savoyecel@hotmail.com)  
 Telephone: +33-2-32886496 Fax: +33-2-32888235

Received: August 4, 2009 Revised: October 7, 2009

Accepted: October 15, 2009

Published online: January 28, 2010

### Abstract

**AIM:** To compare defecographic abnormalities in symptomatic men and women and to analyze differences between men and age- and symptom-matched women.

**METHODS:** Sixty-six men (mean age: 55.4 years, range: 20-81 years) who complained of constipation and/or fecal incontinence and/or pelvic pain underwent defecography after intake of a barium meal. Radiographs were analyzed for the diagnosis of rectocele, enterocele, intussusception and perineal descent. They were compared with age- and symptom-matched women ( $n = 198$ ) who underwent defecography during the same period.

**RESULTS:** Normal defecography was observed in 22.7% of men vs 5.5% of women ( $P < 0.001$ ). Defecography in men compared with women showed 4.5%

vs 44.4% ( $P < 0.001$ ) rectocele, and 10.6% vs 29.8% ( $P < 0.001$ ) enterocele, respectively. No difference was observed for the diagnosis of intussusception (57.6% vs 44.9%). Perineal descent at rest was more frequent in women ( $P < 0.005$ ).

**CONCLUSION:** For the same complaint, diagnosis of defecographic abnormalities was different in men than in women: rectocele, enterocele and perineal descent at rest were observed less frequently in men than in women.

© 2010 Baishideng. All rights reserved.

**Key words:** Fecal incontinence; Defecography; Rectocele; Hernia; Pelvic floor; Constipation

**Peer reviewer:** Reiji Sugita, MD, Department of Radiology, Sendai City Medical Center, 5-22-1, Tsurugaya, Miyagino-ku, Sendai 983-0824, Japan

Savoye-Collet C, Savoye G, Koning E, Leroi AM, Dacher JN. Gender influence on defecographic abnormalities in patients with posterior pelvic floor disorders. *World J Gastroenterol* 2010; 16(4): 462-466 Available from: URL: <http://www.wjg-net.com/1007-9327/full/v16/i4/462.htm> DOI: <http://dx.doi.org/10.3748/wjg.v16.i4.462>

### INTRODUCTION

Constipation, fecal incontinence and pelvic pain require meticulous evaluation because therapy can be effective and help patients to lead a fuller life. Radiographic dynamic rectal examination (defecography) is a valuable method to assess evacuation disorders<sup>[1-5]</sup>. This method provides precise information on anorectal and pelvic floor functions<sup>[6-8]</sup>. It can be used to evaluate efficiently defecation disorders after clinical examination for the exploration of constipation, pelvic pain and anal incontinence<sup>[9-13]</sup>.

Posterior pelvic floor disorders are common and well known in women, and some are related to obstetrical consequences. Little is known about gender influence in symptomatic patients investigated by defecography<sup>[14,15]</sup>. Men can also complain of constipation, fecal incontinence and pelvic pain, and these symptoms need the same careful evaluation because they may need specific therapy<sup>[16]</sup>.

The purpose of our study was to compare prevalence of defecographic abnormalities in men and age- and symptom-matched women.

## MATERIALS AND METHODS

### Patients

Over a 6-year period, 66 symptomatic aged 20-81 years (mean  $\pm$  SD: 55.4  $\pm$  14.9 years) addressed for defecography were evaluated consecutively in our institution. All patients were referred by a gastroenterologist or a digestive tract surgeon for the exploration of constipation, pelvic pain or fecal incontinence. Constipation was defined as less than two bowel movements per week. Fecal incontinence was defined by an uncontrolled loss of liquid or solid stools that corresponded to grade C and D of Park's classification<sup>[17]</sup>.

To compare defecographic abnormalities in men with women, a case-matched series was isolated from a prospective database of women ( $n = 700$ ) investigated by defecography in the same period with the same techniques. Three women for one man were isolated. A series of 198 age- and symptom-matched women was studied. A value of 0 (absence) or 1 (presence) was attributed to each of the three types of symptoms (constipation, anal incontinence or pelvic pain) for all the patients in the database. Several age groups (5-years periods) were isolated for both genders. In these groups of similar age, three women with the same combination of symptoms were associated with one man. The choice of the symptom-matched women was done blindly of the results of the defecography from a global database that contained all the symptomatic patients who underwent defecography during this period in our unit. For example, for a 63-year-old man with constipation and pelvic pain (values = 1/0/1), three women (aged 60-65 years) with the same combination (1/0/1) were isolated. The women were aged 20-81 years (mean: 55.1  $\pm$  14 years).

### Defecography

We applied a standardized protocol to perform and evaluate all defecography examinations. All patients received a barium meal 1.5 h before the examination to opacify the pelvic small bowel for the detection of enterocele. A lateral X-ray was first performed for bone and pelvic loop visualization. In women, a thick barium paste was injected into the vagina, to mark out the posterior vaginal wall. Then, 150 mL of thickened and viscous high-density barium contrast medium was injected in the rectum with the patient in the left lateral position.

Films were taken in a standing lateral position during the following maneuvers: at rest, at voluntary and maximal contraction of the sphincter and pelvic floor ("squeeze"), and at straining without defecation ("strain"). The pubococcygeal line was defined and the distance between this line and the anorectal junction was determined for the three positions. Finally, patients sat on an upright commode attached to the footboard of the fluoroscopy table (a modified toilet), and one frame per second films were taken during expulsion and after completion of defecation at maximum straining.

Precise explanations of the entire procedure were given by the radiologist prior to defecography. In young women, defecography was always performed during the first part of the cycle. Image analysis was done by one of the senior radiologists involved in this study (CSC or EK).

Pathological patterns were defined as follows. Pelvic floor descent was assessed from standing lateral views during maneuvers. For the diagnosis of perineal descent at rest, the distance in millimeters between the anorectal junction and the pubococcygeal line was noted. Perineal descent at rest was defined as a distance of  $> 30$  mm. For perineal descent at straining, the difference in millimeters between the anorectal junction position at straining and at rest was noted. Perineal decent at straining was defined as a difference of  $> 20$  mm between the two positions. The number of male and female patients with perineal descent at rest was compared. Anterior rectocele was defined as  $> 30$  mm outpouching of the anterior rectal wall. This outpouching should persist on incomplete evacuation. Intussusception was defined as an invagination of the rectal wall, either intrarectal, intra-anal, or an external prolapse of the whole circumference. Enterocele was defined as herniation of the small bowel between the vaginal posterior wall and the anterior rectal wall.

### Statistical analysis

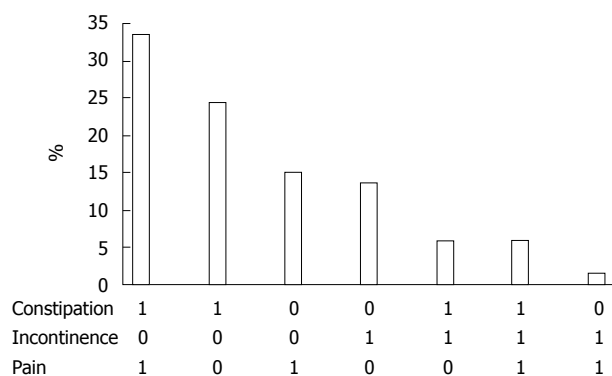
$\chi^2$  tests were used for the comparison of rectocele, enterocele, perineal descent and intussusception.  $P < 0.05$  was regarded as significant.

## RESULTS

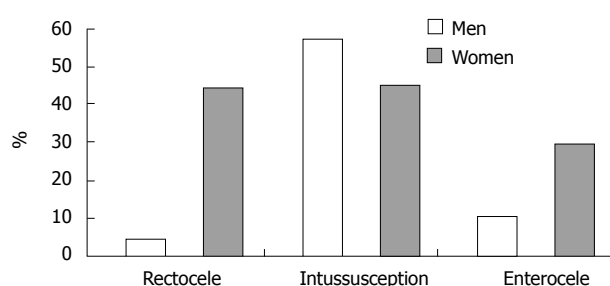
Constipation, fecal incontinence and pelvic pain were present in 69%, 27% and 56% of our male patients, respectively. These symptoms could be isolated (53%) or associated (Figure 1). The more frequent association was constipation and pelvic pain (33%).

Defecography could be satisfactorily performed in all patients and all examinations could be analyzed fully with the above-described criteria. In men, 22.7% of the defecography procedures were normal versus 5.5% in women ( $P < 0.001$ ).

Defecography in men showed intussusception in 38 patients (57.6%), enterocele in seven (10.6%), and rectocele in three (4.5%). Defecography in women showed intussusception in 89 patients (44.9%), enterocele



**Figure 1** Defecography in men: distribution with regard to the combination of symptoms (constipation and/or incontinence and/or pain). 0: Absence; 1: Presence.



**Figure 2** Results of defecography with regard to rectocele, intussusception and enterocoele in men and women. Rectocele:  $P < 0.001$ , Enterocoele:  $P < 0.005$ , Intussusception: NS.

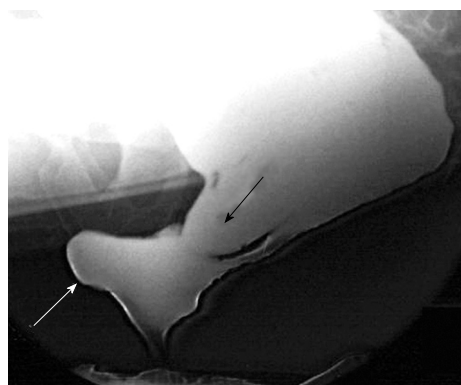in 59 (29.8%), and rectocele in 88 (44.4%). There was a significantly higher proportion of rectocele and enterocoele in matched women (Figures 2 and 3). There was no statistically significant difference for the diagnosis of intussusception.

Distance between the pubococcygeal line and the anorectal junction at the three positions (rest, squeeze and strain) was significantly different between men and women, with a lower position of the perineum in women regardless of position ( $P < 0.001$ ) (Figure 4). There was a greater incidence of perineal descent at rest in women compared with men ( $P < 0.005$ ) (Figure 5). There was no difference between men and women for the diagnosis of perineal descent at straining.

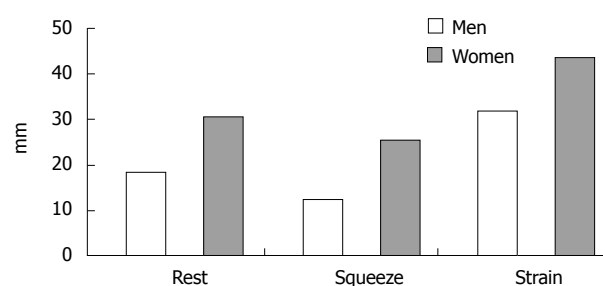
## DISCUSSION

Defecography is used commonly in women, but only a few procedures are carried out in men. In our department, men represented  $< 10\%$  of all defecography procedures. To the best of our knowledge, no specific study of defecography has been carried out to explore the gender difference in the diagnosis of defecographic abnormalities. The pairing of our case-matched study was done for age and symptoms, with one man for three matched women, as is usual in this type of study. It allowed us to establish any sex difference in the prevalence of defecographic abnormalities.

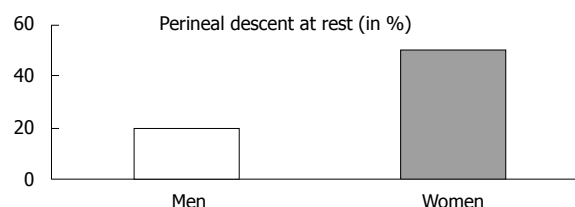
Intussusception is very common in both sexes



**Figure 3** Dynamic imaging during evacuation showed an enterocele (black arrow) associated with a rectocele (white arrow).



**Figure 4** Distance between the pubococcygeal line and the anorectal junction at rest, squeeze and strain in men and women.  $P < 0.001$ .



**Figure 5** Percentage of men and women with perineal descent at rest.  $P < 0.005$ .

(approximately half of patients undergoing defecography)<sup>[7,8]</sup>. We did not observe any sex difference in prevalence. Enterocoele and rectocele were more common in matched women. This could be explained by obstetrical anteriority (vaginal delivery or hysterectomy). The consequences of obstetric damage on the perineum are well known<sup>[18,19]</sup>. Enterocoele is also more frequent after hysterectomy<sup>[20]</sup>. Rectocele is diagnosed 10 times more frequently in women, and appears to be characteristic of the female population. Rectocele has been reported previously as being uncommon in men<sup>[15]</sup>. Chen *et al*<sup>[15]</sup> have reported a prevalence higher than ours (17% *vs* 4.4%), and a frequent association between rectocele and prostatectomy (40%). We did not assess the history of all patients, but this difference could be explained by the higher mean age of the patients in the study of Chen *et al*<sup>[15]</sup> (72.4 years) than in our study (55.4 years), because prostatectomy is more likely in older patients.

The distance between the pubococcygeal line and the

anorectal junction, which determines the position of the perineum, was greater in women for the three positions (rest, squeeze and strain). As a consequence, there was a gender difference for the diagnosis of perineal descent at rest. There was no such difference for perineal descent at straining. This raises the question that the normal level of the perineum could be different in both sexes. However, our study concerned only symptomatic patients and this needs to be investigated in control subjects. No sex-related definition of pelvic floor disorders was established, therefore, our diagnostic criteria were those commonly used, which means those used in women. However, new criteria for the diagnosis of perineal descent at rest in men could probably be defined. The same question can also be raised in elderly patients, for whom diagnostic criteria could also be adapted<sup>[21]</sup>.

Determination of the clinical value of defecographic abnormalities is also difficult and remains a subject of debate<sup>[22-26]</sup>. Defecographic abnormalities have been shown not to be symptom-related<sup>[12]</sup>. This study confirmed this finding, because there were gender differences among symptom-matched patients. Interpretation should be cautious because radiographic changes can be demonstrated in healthy subjects of various ages<sup>[27,28]</sup>. Interobserver agreement is good for rectocele and enterocele<sup>[29]</sup> but appears insufficient for perineal descent<sup>[25]</sup>. Different methods for measuring parameters, especially perineal descent, have been described, with controversy as to which is the most accurate, and with little agreement<sup>[26,30,31]</sup>. New examinations are also possible, such as magnetic resonance defecography, to assess pelvic floor disorders<sup>[32,33]</sup>.

In conclusion, defecography is a potential adjunct to clinical evaluation of men with constipation, fecal incontinence or pelvic pain. With symptoms equal, some defecographic abnormalities are sex-related: rectocele, enterocele and perineal descent at rest were observed less frequently in men.

## COMMENTS

### Background

Posterior pelvic floor disorders are caused by changes in the musculo-aponeurotic support of the pelvic floor. Defecography (radiographic dynamic rectal examination) provides precise information on anorectal and pelvic floor functions for patients with constipation, fecal incontinence and pelvic pain. These symptoms are more frequent in women, and some are related to obstetrical consequences. Little is known about the influence of gender in patients with pelvic floor disorders.

### Research frontiers

Radiological exploration of pelvic floor disorders is important to elucidate the pathophysiology and assist in deciding the therapeutic strategy. It is difficult to attribute a radiological abnormality as the direct cause of the symptoms. A better knowledge of gender difference in the prevalence of defecographic abnormalities appears to be useful.

### Innovations and breakthroughs

To the best of the authors' knowledge, no specific study of defecography has been carried out to explore the gender difference in the diagnosis of defecographic abnormalities. The strength of this study was that it assessed gender in the diagnosis of defecographic abnormalities.

### Applications

For the same complaint, defecographic abnormalities are different in men than

in women: rectocele, enterocele and perineal descent at rest were less frequent in men than in women. Discussion of sex differences in pelvic floor disorders could probably help to assess more precisely these nosological entities. New examinations are also possible, such as magnetic resonance defecography.

### Terminology

There are several defecographic abnormalities. Rectocele is an outpouching of the anterior rectal wall. Enterocele is a herniation of the small bowel between the vagina and rectum. Perineal descent is an abnormal position of the perineum under the pubococcygeal line.

### Peer review

The results of this study are interesting, although the method of this study (defecography) is relatively old and slightly controversial. The results of this study raise issue concerning gender differences in pelvic floor disorders, and may bring a new dimension.

## REFERENCES

- 1 **Burhenne HJ**. Intestinal evacuation study: a new roentgenologic technique. *Radiol Clin* 1964; **33**: 79-84
- 2 **Mahieu P**, Pringot J, Bodart P. Defecography: II. Contribution to the diagnosis of defecation disorders. *Gastro-intest Radiol* 1984; **9**: 253-261
- 3 **Karasick S**, Karasick D, Karasick SR. Functional disorders of the anus and rectum: findings on defecography. *AJR Am J Roentgenol* 1993; **160**: 777-782
- 4 **Liu BH**, Fang SW, Tong WD, Gong SG, Zhang SB. Role of pelvicography and colpocystodefecography in diagnosis of outlet obstructive constipation. *Int J Colorectal Dis* 2005; **20**: 317-320
- 5 **Touchais JY**, Koning E, Savoye-Collet C, Leroi AM, Denis P. [Role of defecography in female posterior pelvic floor abnormalities] *Gynecol Obstet Fertil* 2007; **35**: 1257-1263
- 6 **Kelvin FM**, Maglinte DD, Hornback JA, Benson JT. Pelvic prolapse: assessment with evacuation proctography (defecography) *Radiology* 1992; **184**: 547-551
- 7 **Agachan F**, Pfeifer J, Wexner SD. Defecography and proctography. Results of 744 patients. *Dis Colon Rectum* 1996; **39**: 899-905
- 8 **Mellgren A**, Bremner S, Johansson C, Dolk A, Udén R, Ahlbäck SO, Holmström B. Defecography. Results of investigations in 2,816 patients. *Dis Colon Rectum* 1994; **37**: 1133-1141
- 9 **Rex DK**, Lappas JC. Combined anorectal manometry and defecography in 50 consecutive adults with fecal incontinence. *Dis Colon Rectum* 1992; **35**: 1040-1045
- 10 **Jorge JMN**, Wexner SD. Etiology and management of fecal incontinence. *Dis Colon Rectum* 1993; **36**: 77-97
- 11 **Jean F**, Tanneau Y, Le Blanc-Louvry I, Leroi AM, Denis P, Michot F. Treatment of enterocele by abdominal colporrectosacropexy - efficacy on pelvic pressure. *Colorectal Dis* 2002; **4**: 321-325
- 12 **Savoye-Collet C**, Savoye G, Koning E, Dacher JN. Defecographic disorders in anal incontinent women: relation to symptoms and anal endosonographic patterns. *Scand J Gastroenterol* 2005; **40**: 141-146
- 13 **Savoye-Collet C**, Koning E, Dacher JN. Radiologic evaluation of pelvic floor disorders. *Gastroenterol Clin North Am* 2008; **37**: 553-567, viii
- 14 **Cavallo G**, Salzano A, Grassi R, Zanatta P, Tuccillo M. Rectocele in males: clinical, defecographic, and CT study of singular cases. *Dis Colon Rectum* 1991; **34**: 964-966
- 15 **Chen HH**, Iroatulam A, Alabaz O, Weiss EG, Nogueras JJ, Wexner SD. Associations of defecography and physiologic findings in male patients with rectocele. *Tech Coloproctol* 2001; **5**: 157-161
- 16 **Wang J**, Luo MH, Qi QH, Dong ZL. Prospective study of biofeedback retraining in patients with chronic idiopathic functional constipation. *World J Gastroenterol* 2003; **9**: 2109-2113



- 17 **Parks AJ**. Anorectal incontinence. *J R Soc Med* 1975; **68**: 21-30
- 18 **Sultan AH**, Kamm MA, Hudson CN, Thomas JM, Bartram CI. Anal-sphincter disruption during vaginal delivery. *N Engl J Med* 1993; **329**: 1905-1911
- 19 **Kamm MA**. Obstetric damage and faecal incontinence. *Lancet* 1994; **344**: 730-733
- 20 **Lapalus MG**, Henry L, Barth X, Mellier G, Gautier G, Mion F, Damon H. [Enterocoele: clinical risk factors and association with others pelvic floor disorders (about 544 defecographies)] *Gynecol Obstet Fertil* 2004; **32**: 595-600
- 21 **Savoye-Collet C**, Savoye G, Koning E, Leroi AM, Dacher JN. Defecography in symptomatic older women living at home. *Age Ageing* 2003; **32**: 347-350
- 22 **Felt-Bersma RJ**, Luth WJ, Janssen JJ, Meuwissen SG. Defecography in patients with anorectal disorders. Which findings are clinically relevant? *Dis Colon Rectum* 1990; **33**: 277-284
- 23 **Ott DJ**, Donati DL, Kerr RM, Chen MY. Defecography: results in 55 patients and impact on clinical management. *Abdom Imaging* 1994; **19**: 349-354
- 24 **Hiltunen KM**, Kolehmainen H, Matikainen M. Does defecography help in diagnosis and clinical decision-making in defecation disorders? *Abdom Imaging* 1994; **19**: 355-358
- 25 **Wiermsa TG**, Mulder CJ, Rieders JW. Dynamic rectal examination : its significant clinical value. *Endoscopy* 1997; **29**: 462-471
- 26 **Harvey JC**, Halligan S, Bartram CI, Hollings N, Sahdev A, Kingston K. Evacuation proctography: a prospective study of diagnostic and therapeutic effects. *Radiology* 1999; **211**: 223-227
- 27 **Mahieu P**, Pringot J, Bodart P. Defecography: I. Description of a new procedure and results in normal patients. *Gastro-intest Radiol* 1984; **9**: 247-251
- 28 **Shorvon PJ**, McHugh S, Diamant NE, Somers S, Stevenson GW. Defecography in normal volunteers: results and implications. *Gut* 1989; **30**: 1737-1749
- 29 **Müller-Lissner SA**, Bartolo DC, Christiansen J, Ekberg O, Goei R, Höpfner W, Infantino A, Kuijpers HC, Selvaggi F, Wald A. Interobserver agreement in defecography--an international study. *Z Gastroenterol* 1998; **36**: 273-279
- 30 **Choi JS**, Wexner SD, Nam YS, Mavrantonis C, Salum MR, Yamaguchi T, Weiss EG, Noguera JJ, Yu CF. Intraobserver and interobserver measurements of the anorectal angle and perineal descent in defecography. *Dis Colon Rectum* 2000; **43**: 1121-1126
- 31 **Dvorkin LS**, Gladman MA, Epstein J, Scott SM, Williams NS, Lunniss PJ. Rectal intussusception in symptomatic patients is different from that in asymptomatic volunteers. *Br J Surg* 2005; **92**: 866-872
- 32 **Pannu HK**, Kaufman HS, Cundiff GW, Genadry R, Bluemke DA, Fishman EK. Dynamic MR imaging of pelvic organ prolapse: spectrum of abnormalities. *Radiographics* 2000; **20**: 1567-1582
- 33 **Stoker J**, Bartram CI, Halligan S. Imaging of the posterior pelvic floor. *Eur Radiol* 2002; **12**: 779-788

S- Editor Tian L L- Editor Kerr C E- Editor Ma WH