

# **Plasmacytoid dendritic cells and dermatological disorders: focus on their role in autoimmunity and cancer**

Julie Charles<sup>1 2 3</sup>, Laurence Chaperot<sup>1 2 \*</sup>, Dimitri Salameire<sup>1 2 4</sup>, Jérémy Di Domizio<sup>1 2</sup>, Caroline Aspard<sup>1 2</sup>, Rémy Gressin<sup>5</sup>, Marie-Christine Jacob<sup>6</sup>, Marie-Jeanne Richard<sup>1 2 7</sup>, Jean-Claude Beani<sup>3</sup>, Joel Plumas<sup>1 2</sup>, Marie-Thérèse Leccia<sup>1 2 3</sup>

<sup>1</sup> Institut d'oncologie/développement Albert Bonniot de Grenoble INSERM : U823 , CHU Grenoble , EFS , Université Joseph Fourier - Grenoble I , Institut Albert Bonniot, BP170, 38042 Grenoble Cedex 9,FR

<sup>2</sup> Laboratoire recherche et développement Etablissement Français du Sang (EFS) , 38701 La Tronche,FR

<sup>3</sup> Département Pluridisciplinaire de Médecine, Dermatologie CHU Grenoble , Hôpital Albert Michallon , 38043 Grenoble Cedex,FR

<sup>4</sup> Département d'Anatomie et cytologie pathologiques CHU Grenoble , Pôle de biologie, Grenoble,FR

<sup>5</sup> Département de cancérologie et d'hématologie CHU Grenoble , Hôpital Michallon , FR

<sup>6</sup> Laboratoire d'Immunocytologie EFS , Grenoble,FR

<sup>7</sup> Unité Mixte de Thérapie Cellulaire et Tissulaire CHU Grenoble , EFS , UJF , Grenoble,FR

\* Correspondence should be adressed to: Laurence Chaperot <laurence.chaperot@efs.sante.fr >

## **Abstract**

**Dendritic cells (DC), considered as immunological sentinels of the organism since they are antigen presenting cells, create the link between innate and adaptive immunity. DC include myeloid dendritic cells (MDC) and plasmacytoid dendritic cells (PDC). The presence of PDC, cells capable of producing large quantities of interferon alpha (IFN- $\alpha$ ) in response to pathogenic agents or danger signals, seem to be tightly related to pathological conditions. Thereby, PDC have been observed in inflammatory immunoallergic dermatological disorders, in malignant cutaneous tumours and in cutaneous lesions of infectious origin. They seem to play a crucial role in the initiation of the pathological process of autoimmune diseases such as lupus or psoriasis. Their function within a tumour context is not as well known and is controversial. They could have a tolerogenic role towards tumour cells in the absence of activator but they also have the capacity to become activated in response to Toll-like receptor (TLR) ligands and could therefore be usefull for therapeutic purposes.**

**MESH Keywords** Autoimmune Diseases ; immunology ; Dendritic Cells ; immunology ; secretion ; Humans ; Interferon-alpha ; immunology ; secretion ; Skin Diseases ; immunology ; Skin Neoplasms ; immunology

**Author Keywords** Interferon alpha ; Lupus ; Melanoma ; Plasmacytoid dendritic cell ; Psoriasis ; Toll-like receptor ligand

## **Introduction**

The skin epidermis constitutes the direct interface with the external environment and the first barrier of protection against the penetration into the organism of exogenous pathogenic agents or substances. The underlying dermis, where vascular structures are located, ensures functions of thermoregulation and nutrition. Immune cells are located and moved between the epidermis and the dermis. They are organised in networks and take part in the defence against pathogenic agents. DC are professional antigen presenting cells (APC) capable of capturing and presenting antigens and also initiating and orchestrating the immune response by establishing links between innate and adaptive responses (1 ). In a physiological situation two DC contingents of myeloid origin are present in the skin: epidermal Langerhans cells and dermal DC also known as interstitial DC (2 ). The presence of PDC in healthy skin is controversial and only one study has shown the presence of rare immature PDC (BDCA2<sup>pos</sup>) with no organised distribution pattern within healthy skin (3 ).

The two populations of DC, MDC and PDC, can be distinguished by their ontogeny and their functional capacities. MDC are of myeloid origin whereas PDC could be of lymphoid origin (4 ). The phenotypic characteristics of DC are presented in table 1 .

MDC have functions of sentinels in peripheral tissues where they are resident and able to capture antigens. Regarding cutaneous compartments immature MDC are present in the skin under basal conditions in the dermis and in the epidermis (2 ). MDC capture pathogenic agents, infected cells or degradation products using different methods (pinocytosis, phagocytosis...) through receptors that allow the capture of antigens and integrate the information provided by the pathological environment. They acquire a high level of maturation and migrate towards secondary lymphoid organs through the modulation of the expression of chemokine receptors: the decrease in the expression of CCR6 allows them for example to leave the skin, whereas an increased expression of CCR7 directs them towards lymph nodes. They also express HLA DR (Human Leukocyte Antigen, HLA) and co-stimulation molecules (CD40, CD80, CD83, CD86) that allow them to initiate a response from lymphocytes present in the lymph nodes (5 ). MDC can induce a T helper type 1 (Th1) polarisation on CD4+ naive T lymphocytes leading to predominant secretion of IFN- $\gamma$  by mature lymphocytes. They can also initiate a T helper type 2 (Th2) polarisation, lymphocytes secreting IL-4 and IL-5. A Th1 profile leads to a cell-mediated immune response whereas a

Th2 profile secondarily leads to the expansion and maturation of B lymphocytes into plasma cells and to a humoral response. The recruitment of CD8<sup>pos</sup> naive T lymphocytes leads to their maturation into cytotoxic T lymphocytes that will cause lysis or induce apoptosis of infected cells via the perforin/granzyme and FAS (CD95)/FASLigand (CD95L) death inducing systems.

In a steady state, immature PDC are found in the blood, in T centers of lymphoid organs, in the thymus, in the tonsils and in lung tissue. The major role of PDC is a rapid response against virus aggressions. PDC have the peculiar capacity to produce large amounts of type I IFN in response to viral stimulation (4). The antigen capture potential of PDC is however less developed compared to other APC. Under basal state PDC are absent of the skin on the contrary to MDC, suggesting that the presence of PDC in the skin under pathological conditions is the consequence of active mechanisms of recruitment.

The trafficking of PDC in infectious, inflammatory or tumour context is not as well understood as MDC trafficking. Blood circulating PDC are able to reach inflamed lymph nodes by an hematogenous route across high endothelial venules (HEV). This recruitment mainly involves CD62L, CCR5 and ChemR23 (6). PDC are absent of the afferent lymph which is in contrast with the trafficking pattern of MDC. High levels of PDC are found in inflamed skin, this recruitment could be mediated by ChemR23 (7) and CXCR3 (8). Activated PDC observed in cutaneous lesions are capable of secreting large quantities of interferon  $\alpha$  (IFN- $\alpha$ ) (4). They can also stimulate naive T lymphocytes and induce Th1 or Th2 polarisation depending on the pathological context. Thereby the stimulation by viruses, by Toll-Like Receptors (TLR) 7 or 9 ligands will lead to a Th1 response whereas activation by IL-3 or CD40L will lead to a Th2 response.

Danger signals carried by pathogenic agents (PAMP) are recognised by TLR. MDC express TLR1, 2, 4, 5 and 8. PDC possess TLR 7 and 9. The expression of TLR7 is almost totally restricted to PDC (9). Thereby MDC and PDC do not express the same set of TLR, but their expression is complementary and allows the recognition of a large panel of pathogenic motifs. New therapeutic molecules targeting TLR are currently in development and can prompt DC danger signal recognition and activation.

Yet, there is a strong plasticity in DC functions, depending on their localization, on their maturation state and on the influence of their environment. It is now established that DC can have tolerogenic functions. The CD4<sup>pos</sup> CD25<sup>pos</sup> T regulatory (Tr) cells and the type 1 regulatory T (Tr1) cells are the best characterized subsets of regulatory T cells and play a crucial role in the peripheral tolerance. It has been demonstrated that Tr1 cells can be induced in the periphery by tolerogenic MDC and that mature DC are able to expand functional CD4<sup>pos</sup> CD25<sup>pos</sup> Tr cells (baccetta autoimmunity reviews 491 and adler EJD 2007). Regarding PDC, PDC precursors activated in the presence of IL-3 and CD40-ligand into mature dendritic cells named DC2 are able to induce CD8<sup>pos</sup> Tr cells producing IL10 (gilliet 1149). The generation of tolerogenic MDC or PDC open new therapeutic ways in pathologies such as auto-immune diseases or Graft versus Host Disease (GVHD).

Recently a third subset of effector Th cells that produces IL17 (Th17) has been identified. The protective role of Th17 cells appears to be the clearance of pathogens such as candida Albicans and specific extracellular bacteria that are not adequately handled by Th1 or Th2 cells. Th17 are can also enhance anti-tumor immunity (3 ref nat mecd) But the Th17 cells are able to induce strong tissue inflammation and are implicated in the pathogenesis of auto-immune and inflammatory diseases such as multiple sclerosis, inflammatory bowel disease, rheumatoid arthritis or psoriasis (korn ann review immunol 2009 485). The role of DC in Th17 polarization is not well defined. Upon specific TLR or dectin receptor stimulation, DC are able to produce IL23 and this cytokine together with TGF- $\beta$ , IL1 $\beta$  and IL6 stabilizes differentiating Th17 cells. So MDC expressing TLR2, TLR 4 and C-type lectins seems to be able to skew the T cell response toward Th17 profile. The role of PDC in inducing Th17 in humans is not well characterized for now.

We propose here an overview of dermatological diseases in which PDC are highly implicated and could bring new knowledges in physiopathology of some dermatoses or represent potential targets for new therapeutic approaches.

### **PDC and immunoallergic inflammatory cutaneous diseases**

PDC were initially described in disorders involving an important lymphocytic infiltrate and were associated with the group of cutaneous pseudolymphomas. At the end of the 1980's a new cellular contingent termed plasmacytoid T cells or plasmacytoid monocytes was discovered in cutaneous lymphoid hyperplasias and in **Jessner-Kanoff type lymphocytic infiltrates** (10, 11). Until then these cells had only been identified in reactive lymph nodes. They were called plasmacytoid because their morphology was closed to the one of plasma cells with a developed endoplasmic reticulum. They also had common phenotypic characteristics with T lymphocytes and DC, considered to belong to Skin-associated Lymphoid Tissue (SALT) and their antigen presenting functions was a matter of debate (11). In another study, the presence of plasmacytoid monocytes was established in 58% of biopsies removed from patients suffering from Jessner-Kanoff disease (75 biopsies) (12).

It is now established that these plasmacytoid monocytes or plasmacytoid T cells that were described in the 1980's were actually PDC (13).

Jessner Kanoff disease and **lupus** belong to the same spectrum of dermatosis that can be photo-induced. PDC are found in large quantities by immunohistochemistry in skin biopsies from patients suffering from **chronic discoid lupus** and **lupus erythematosus** (14 ). PDC are preferentially distributed along the dermal-epidermal junction, around hair follicles and vessels. Cells positive for MxA (protein induced by IFN- $\alpha$ ) are disseminated throughout the dermis and epidermis and their number correlates with the PDC density of the infiltrate. These data suggest that activated PDC secrete IFN- $\alpha$  (14 ). PDC were also identified in **lupic panniculitis** lesions, a specific clinical type of lupus also known as lupus erythematosus profundus, in association with an important in situ secretion of IFN- $\alpha$  (15 ). The activation of PDC appears to occur via TLR 7 and 9 that recognise specific DNA and RNA sequences. In patients with lupus, there is a defect in the degradation of apoptotic cells leading to the accumulation of RNA and DNA fragments especially CpG enriched hypomethylated DNA fragments. These nucleic acid molecules generated by apoptotic cells can accumulate in the skin after exposure to ultraviolet rays (16 ). In some patients, especially patients suffering from **systemic lupus** , anti-double stranded DNA antibodies and antibodies directed against nuclear antigens are produced. These antibodies lead to the formation of circulating immune complexes containing DNA. These immune complexes are able to activate the TLR9. It is now established that this activation occurs via the High Mobility Group Box protein type 1 (HMGB1), secreted by necrotic cells and inflammatory cells that binds to nuclear DNA present in the immune complex. HMGB1 will then interact with RAGE (receptor for advanced glycation end-products) which induces the activation of PDC via the TLR9-MyD88 pathway (17 ). Recently, PDC have also been identified in **lupus tumidus** (spontaneous and photo-induced lesions) giving new arguments for a PDC recruitment after UV injury and supporting the concept of a PDC driven pathology in cutaneous lupus (18 ).

**Psoriasis** is another inflammatory dermatosis in which hyperproliferation of keratinocytes is observed in response to an environmental aggression on a background of genetic predisposition. Understanding this disease comes down to determining how inflammatory cells of innate and adaptive immunity are capable of inducing the proliferation of keratinocytes and disorders of epidermal differentiation. The lymphocytic hypothesis is currently thought to be the most likely: autoreactive and constantly activated T lymphocytes produce cytokines that have pro-mitotic effects on keratinocytes (19 ).

PDC have been identified in increased numbers in psoriasis skin lesions but are also present in the healthy skin of these same patients ( 20 ). Within the lesions they are located in the dermis and have an activated phenotype. In parallel, the number of circulating PDC is reduced in these patients, which is in favour of a cutaneous recruitment. IFN- $\alpha$  produced by activated PDC is secreted during the early phase of the development of a psoriasis lesion and is transient. It induces a strong activation and expansion of pathogenic T lymphocytes. PDC and IFN- $\alpha$  are actors of innate immunity and appear to play a dominant role in the pathophysiology of psoriasis (20 ). Blocking the secretion of IFN- $\alpha$  using an anti-BDCA2 monoclonal antibody inhibits the development of psoriasis lesions (experimental model of human psoriasis skin xenografts into mice) (20 ).

Recently, the anti-microbial peptide LL37 has been identified as a key factor in the development and propagation of psoriasis lesions ( 21 ). LL37 is highly expressed in psoriasis lesions and binds the self-DNA to form aggregated and condensed structures, that are potent activators of PDC. These complexes are delivered to the early endocytic compartment of PDC to trigger TLR9 and thereby IFN- $\alpha$  production (22 ). The earliest event seems to be the conversion of Pro-chemerin into chemerin in psoriatic pre-lesionnal skin leading to the recruitment of ChemR23 expressing PDC. This Chemerin/ChemR23 axis is a new important player in the pathogenesis of psoriasis (23 ).

Moreover, it has been described that the accidental application of a TLR-7 agonist, Imiquinod on psoriasis plaques could lead to its exacerbation and extension into guttate psoriasis (24 ). Lesions that had appeared at a distance from the application area excluded a simple Koebner phenomenon that could be secondary to the irritation caused by Imiquimod and PDC had been identified in psoriasis plaques. It would therefore be possible that PDC activated via the TLR-7 produce IFN- $\alpha$  in large quantities that could trigger psoriasis lesions.

The circulating contingent of PDC in patients suffering from **atopic dermatitis** is higher compared to control subjects resulting in a reduced MDC/PDC ratio. An inverse correlation was established between the ratio MDC/PDC and the clinical score of the disease (25 ). The PDC infiltrate in atopic eczema lesions is less pronounced than in other inflammatory dermatoses such as psoriasis, contact eczema or lupus (26 ). The rare PDC present in the skin are located in close proximity to vessels expressing a subtype of adrenergic receptors, the peripheral neural adrenergic receptors (PNAs). The PNAs are the physiological ligands of L-selectin (CD62L) which is strongly expressed by PDC(25 ). PDC seem capable of promoting a Th2 immune response but also a Th1 response in synergy with MDC. This type of response profile was observed during the chronic phase of the atopic disease, enhancing the auto-maintenance of the disease. Moreover, this weak recruitment of PDC in atopic eczema inflammatory lesions could explain the high sensitivity of the patients to viral infections, such as Human Herpes Virus (HSV)1 and HSV2 herpes viruses, pox-virus infections, favored by a local deficiency in type I IFN (27 ).

On the contrary, PDC have been found in large quantities in **contact eczema** lesions (26 ).

**Lichen planus** is an inflammatory dermatosis with a yet undetermined etiology. Following the hypothesis of a viral origin, the genomes of different viruses were searched for in cutaneous biopsies. Cells infected by HHV-7 (Human-Herpes Virus 7) were identified

significantly more frequently in lichen planus lesions than in healthy skin or in other inflammatory dermatoses (28 ). A large number of PDC was also observed in dermal infiltrates in close proximity to the epidermal basement membrane. Within lesions, the DNA of HHV-7 was predominantly present in PDC expressing BDCA-2 and replicates within these cells. Clinical remission following treatment was associated with a decrease in viral DNA and in the number of PDC in situ (29 ). Lichen planus could be associated with a reactivation of HHV-7, which prevalence is of roughly 90% within the general population, not following a cytopathogenic pattern, but as an intense inflammatory reaction initiated by PDC (29 ).

### **PDC and infectious disorders**

PDC are in the front line in the antiviral immune response. Circulating and cutaneous PDC were analysed in a patient suffering from **chicken pox** , therefore infected with a **Varicella Zoster Virus (VZV)** (30 ). PDC were identified in the epidermis and dermis and strongly expressed CXCR3. The circulating PDC contingent however was reduced. These data suggested that PDC probably left the peripheral blood circulation and were mobilised via CXCR3/CXCR3-ligand interactions on the site of the infection. They were activated and secreted IFN- $\alpha$ , as shown by the high number of MxA positive cells present in the dermis and epidermis.

PDC have also a crucial role in **HSV1 and HSV2** infection. We have previously discussed the lack of PDC in atopic dermatitis skin as a factor for HSV surinfection. PDC participate in the immune control of recurrent HSV infection by their resistance to HSV infection and their capacity to induce a specific autologous T lymphocyte proliferation (31 ).

PDC have also been identified in virally induced cancers, especially in cervical carcinomas induced by the **Human Papilloma Virus (HPV)** (32 ). However, the role of PDC in the context of solid tumours remains unclear.

### **PDC in the context of malignant cutaneous disorders**

The interactions of DC subsets with tumour cells and tumour micro-environment are complex and the function of DC is finally determined by a balance of several molecular interactions that regulate recognition, uptake, processing and presentation of tumour antigens (33 ).

PDC have been identified within primary melanomas using immunohistochemical methods in a series including **primary melanomas** of different invasion stages, ranging from in situ melanoma to melanoma with Breslow index of 28mm (34 ). PDC expressing CD123 were located around the tumour within a cellular infiltrate containing lymphocytes and MDC or in close proximity to blood vessels. More rarely, they are close to tumour cell clusters or directly in contact with melanoma cells. PDC have also been shown in **cutaneous melanoma metastases** . PDC are present in 79% of the malignant melanomas studied (42 primary tumours and 11 cutaneous metastases) whereas they were absent from samples of healthy skin and nevi that served as controls. Moreover, the analysis of 4 sentinel lymph nodes (1 lymph node with micrometastasis) revealed the presence of small clusters of PDC in these lymph nodes. In primary tumours and lymph nodes, the production of IFN- $\alpha$  was studied using the IFN alpha – inducible MxA protein. Results showed a weak production of IFN- $\alpha$  that could be linked to functional abnormalities and to a low level of maturation of PDC.

Another study showed the presence of PDC in primary melanoma at the periphery of tumour cells (5 tumours studied) (35 ). The number of PDC was higher in invasive and metastatic melanoma than in in-situ tumours. In vitro, the functional study of PDC showed that they are capable of initiating a Th1 response with proliferation of CD8<sup>pos</sup> T cells specifically directed against melanoma cells. The CD62L expression of these T cells allowed them to reach inflammatory skin. The supernatants of activated PDC also induced a strong expression of MHC I as well as CD95 on melanoma cells allowing their recognition and lysis by CD8<sup>pos</sup> T cells. In vivo , however PDC had a weak level of activation. They were CD83<sup>neg</sup> and produced very little amount of IFN- $\alpha$ . PDC were present in the tumour but at a sub-optimal level of activation that did not allow them to exhibit all their functional capacities.

In our laboratory, we were able to show the presence of PDC in different primary melanomas by immuno-histochemical staining of paraffin embedded tumour with the BDCA2 antibody (fig 1 ).

PDC could also play a role in the phenomenon of **regression** that is histologically defined by the total or focal disappearance of malignant melanocytes in the dermis and/or epidermis. Regression occurs in roughly 40% of primary melanomas (36 ) and can be considered as a localised phenomenon of autoimmunity as the T cell response that is observed is directed against tumour antigens that are considered as self-antigens. By analogy with autoimmune disorders such as cutaneous lupus, the potential role of IFN- $\alpha$  has been studied in the regression. An immunohistochemical study on 14 melanoma showing regression compared to 6 dysplastic nevi, 4 halo nevi and 5 samples of healthy skin was performed (37 ). In primary melanoma showing signs of early or intermediate regression, a significantly larger CD8<sup>pos</sup> T cell infiltrate was observed. The type-I IFN-s inducible protein, MxA was strongly expressed within melanoma showing signs of early or intermediate regression and in halo nevi. The mechanism of CD8<sup>pos</sup> T cell recruitment appeared to be mediated by the interferon-inducible protein 10 (IP10), the type I IFN inducible protein, as CD8<sup>pos</sup> T cells express CXCR3, the IP-10 receptor. IFN- $\alpha$  producing cells present in the medium were probably PDC as they were revealed using the anti-BDCA-2 antibody. Therefore the initiation

of the immune response that triggered tumour regression could be linked to the presence of PDC infiltrating the tumor that secrete IFN- $\alpha$ , inducing the expression of IP-10 and the recruitment of cytotoxic T cells expressing CXCR3.

The role of PDC in melanoma can also be studied by looking at the effects of TLR ligands corresponding to the TLR expressed by PDC. Imiquimod, a synthetic agonist of TLR-7 that is specifically expressed by PDC, was tested in a murine model. One hundred and fifteen tumours induced by the intradermal injection of melanoma cells were studied (38). Eighty nine tumours were treated with topical Imiquimod, with one application per day for 30 days, and 26 tumours were treated with the excipient. In Imiquimod-treated lesions, partial or complete regression was observed in 26% of cases, stabilisation was observed in 51% of cases and tumour evolution in 23% of cases. Characterisation of the inflammatory infiltrate following the application of Imiquimod showed a large number of PDC within the infiltrate. Therefore, the authors suggested that the anti-tumour effects of Imiquimod could be mediated by a massive recruitment of PDC, expressing TLR-7 and capable of producing IFN- $\alpha$  in situ.

In humans, no large study evaluated the effects of Imiquimod in the treatment of melanoma or associated cutaneous metastases. Few isolated cases showing the efficacy of Imiquimod on cutaneous melanomas in palliative therapy have been reported (39–41). Only one study was performed on the use of Imiquimod as a first intention therapy for the treatment of 30 lentigo maligna that were not easily accessible through surgery (42). Efficacy was shown in 93% of cases without any relapse at one year of follow-up. It is difficult to draw conclusions from this study, as the sample number was very reduced as the time of follow-up. A phase II multicentric study used a TLR9 agonist, PF-3512676, in the treatment of stage IV melanoma. (M1a to M1c AJCC (43)). Twenty patients were treated with weekly subcutaneous injections of 6mg of PF-3512676 over a period of 24 weeks. The disease progressed under treatment in 14 patients. Stabilisation was observed in 3 patients, and 2 patients partially responded (one of them benefited from a 140 weeks prolonged partial response). There were no severe side effects associated with this treatment. Follow-up of the phenotypic and functional modifications of PDC in the peripheral blood after 8 weeks of treatment showed an increase in the expression of HLA-DR and CD86 activation markers on PDC. A sustained induction of type I IFN expression was also found. These data demonstrate the possibility to act pharmacologically on PDC to activate them in vivo in order to fight against the tumour. The treatment with a TLR9 agonist was also proposed as an adjuvant treatment prior to extensive surgery of the primary melanoma and exeresis of sentinel lymph nodes (44). In sentinel lymph nodes of treated patients, an activation of PDC, an increase in the production of pro-inflammatory cytokines and a decrease in the contingent of regulatory T cells have been observed (45).

PDC are also present in **basal cell carcinomas** and have been studied as pharmacological targets of Imiquimod. PDC appeared to be recruited and activated in situ by Imiquimod, leading to the secretion of IFN- $\alpha$  within the tumour tissue (46). The use of Imiquimod has been validated in the United-States and in Europe for the treatment of superficial basal cell carcinoma (47). It has recently been shown that PDC were massively recruited in superficial basal cell carcinoma and acquired the expression of TRAIL during the application of topical Imiquimod. The expression of TRAIL Receptor 1 has been shown on the surface of basal cell carcinoma cells and a large number of tumour cells undergoing apoptosis were present in tumours treated with Imiquimod, suggesting that the activation of PDC by Imiquimod led to the apoptosis of tumour cells mediated by the TRAIL pathway (48).

PDC have been identified in **epidermoid carcinomas of the head and neck** (49). PDC were distributed within the tumour tissue and presented functional alterations especially with regard to their production of IFN- $\alpha$ . Decreased expression of certain TLR was noted, especially TLR9, leading to the absence of secretion of IFN- $\alpha$  in situ, in response to CPG-oligodeoxynucleotide (ODN), the TLR9 ligand. The response to CPG-ODN was preserved in the draining lymph node. These findings suggested that the microenvironment of the tumour could play a role in the functional alterations observed in PDC.

Studies showed that DC populations in peripheral blood were decreased in patients suffering from the **Mediterranean type Kaposi disease**, an angiosarcoma associated with the Human Herpes Virus 8 (HHV-8). PDC represented 0.23% of the PBMC count in 66 patients compared to 0.32% of PBMC in controls, MDC represent 0.47% of the PBMC count in patients against 0.65% in controls. The phenotypic profile of DC was not modified. Quantitative alterations of the DC contingent were correlated with the stage of the disease but also with the clinical evolution of the disease and were independent of the levels of blood viral DNA detected in the blood of the patients. Modifications in the circulating MDC contingent could be associated with the effects of the viral IL-6 coded by HHV-8 that shares analogies with human IL-6 and inhibits the differentiation of MDC from their CD34+ precursors (50).

### **Hematological disorders with cutaneous expression involving PDC**

PDC could play a crucial role in the occurrence of **graft versus host disease** (GVHD) following the allograft of hematopoietic stem cells as PDC have multiple functions and could play an active role in the phenomenon of tolerance. GVHD occurs when the donor's mature T cells recognise specific antigens of the recipient, which leads to the destruction of the recipient's cells. One study showed that chronic GVHD in humans was associated with a high level of PDC in the graft and in the recipients blood (51). Data from a murine model suggested that PDC from the recipient prevented the occurrence of acute GVHD and enhanced the acceptance of the graft (52).

**PDC leukemia** is an hematological disorder that has only recently been identified as a separate entity (53,54). This leukaemia was initially described as CD4<sup>pos</sup> CD56<sup>pos</sup> malignancy with skin manifestation but the high expression of CD123 marker was a strong argument for a plasmacytoid dendritic cell proliferation (Penven et al EJD2003). The main clinical characteristics of PDC leukemia are an aggressive evolutive profile and frequent skin involvements (fig 2). The phenotype of leukemic PDC is Lin<sup>neg</sup>, CD4<sup>pos</sup>, CD56<sup>pos</sup>, CD11c<sup>pos</sup>, CD123<sup>pos</sup>, HLA-DR<sup>pos</sup>, and CD45Ra<sup>pos</sup>. The phenotypic and functional studies of these cells in several patients have shown the expression of a functional CCR6 on the surface of leukemic PDC with migration towards MIP3 $\alpha$ , its ligand in vitro. CCR6 could therefore allow leukemic PDC to leave the peripheral blood stream and to penetrate the skin leading to the formation of tumour nodules. The phenotypic and functional characteristics of leukemic PDC are otherwise comparable to that of normal PDC (55,56). An unique cell line has been derived from the cells of a patient suffering from PDC leukemia, the GEN cell line (Brevet 02-15927) that is an useful tool for the study of PDC ex vivo (fig 3).

## Conclusion

PDC are professional antigen presenting cells and play a central role in the initiation and regulation of immune responses. PDC seem to be absent in the skin under homeostatic conditions whereas there are massively recruited into the skin under pathological conditions such as inflammatory, infectious or malignant disorders. There is a strong plasticity in their functions depending on the pathological context in which they are present (fig 4) While their role is clearly beneficial for the host in the context of defense against infectious agents, PDC seems to be in a undesired state of activation in patients with inflammatory auto-immune diseases such as psoriasis or lupus. PDC are activated by endogenous pathogenic motifs, their aberrant production of type I interferon leading to inflammation and development of skin lesions. Studies of PDC constitute a crucial progress in the comprehension of the pathogenesis of skin pathologies such as psoriasis and lupus that could lead to new therapeutic approaches targeting IFN- $\alpha$  production by PDC. In a carcinogenic context, PDC seem to play an important role in shaping the host response to tumour. PDC interact with tumour cells and tumour microenvironment and a better understanding of these interactions will have major implications for the comprehension of phenomenon of immunity or tolerance toward tumours. In breast cancer the presence of PDC in the tumor is associate with a poor prognosis (treilleux et al) and in ovarian cancer PDC are recruited to the tumor site and produce IL-10 a regulatory cytokine (zou nat med 2001). Their prognostic signification is not known in skin cancers for now. These supposed detrimental functions of PDC in tumoral context may be reversible in context of melanoma. Molecules that are able to activate PDC and increase their antigen presentation capacities are currently under development. For example, CpG-ODN can enhance the immunogenicity of a Melan-A peptide based vaccine and the tumor antigen specific T cell responses in melanoma patients (speiser2005). Thus, therapeutic agents targeting PDC represent today new innovative approaches in onco-dermatology.

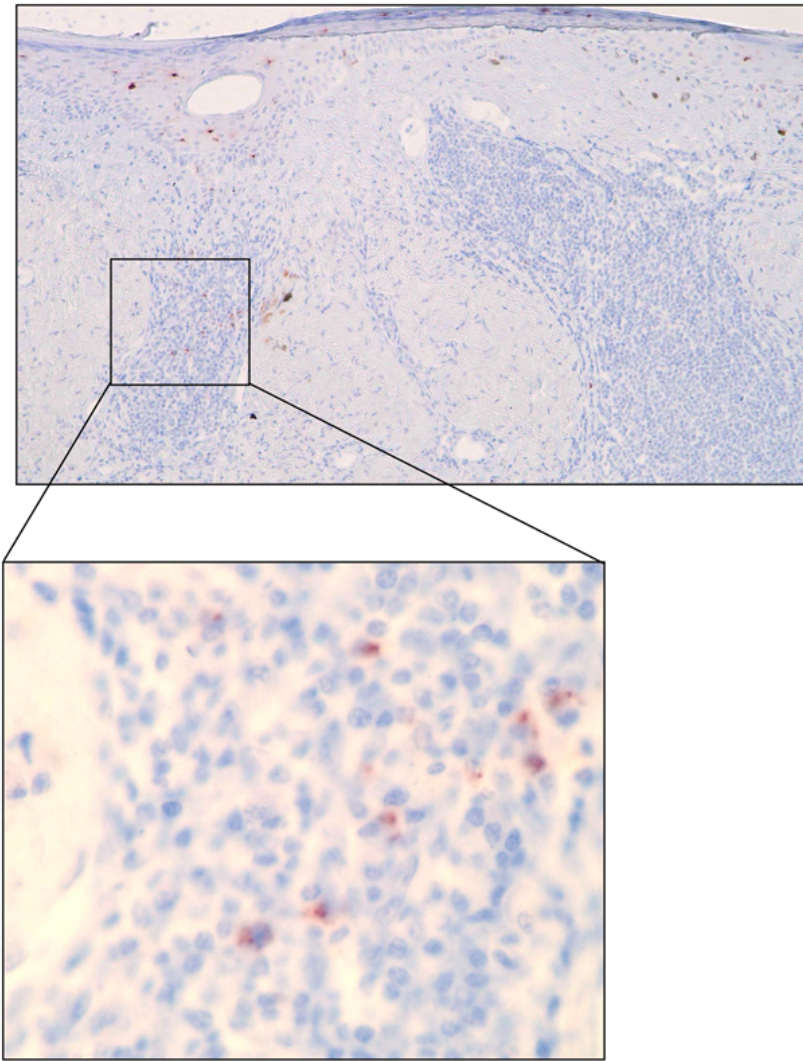
## References:

1. Banchereau J, Briere F, Caux C. Immunobiology of dendritic cells. *Annu Rev Immunol*. 2000; 18: 767 - 811
2. Valladeau J, Saeland S. Cutaneous dendritic cells. *Semin Immunol*. 2005;
3. Ebner S, Ehammer Z, Holzmann S. Expression of C-type lectin receptors by subsets of dendritic cells in human skin. *Int Immunol*. 2004; 16: 877 - 887
4. Colonna M, Trinchieri G, Liu YJ. Plasmacytoid dendritic cells in immunity. *Nat Immunol*. 2004; 5: 1219 - 1226
5. Delves PJ, Roitt IM. The immune system. First of two parts. *N Engl J Med*. 2000; 343: 37 - 49
6. Randolph GJ, Ochando J, Partida-Sanchez S. Migration of dendritic cell subsets and their precursors. *Annu Rev Immunol*. 2008; 26: 293 - 316
7. Vermi W, Riboldi E, Wittamer V. Role of ChemR23 in directing the migration of myeloid and plasmacytoid dendritic cells to lymphoid organs and inflamed skin. *J Exp Med*. 2005; 201: 509 - 515
8. Kohrgruber N, Groger M, Meraner P. Plasmacytoid dendritic cell recruitment by immobilized CXCR3 ligands. *J Immunol*. 2004; 173: 6592 - 6602
9. Takeda K, Kaisho T, Akira S. Toll-like receptors. *Annu Rev Immunol*. 2003; 21: 335 - 376
10. Eckert F, Schmid U. Identification of plasmacytoid T cells in lymphoid hyperplasia of the skin. *Arch Dermatol*. 1989; 125: 1518 - 1524
11. Facchetti F, De Wolf-Peeters C, Van den Oord JJ, Desmet VJ. Plasmacytoid T cells in a case of lymphocytic infiltration of skin. A component of the skin-associated lymphoid tissue?. *J Pathol*. 1988; 155: 295 - 300
12. Toonstra J, van der Putte SC. Plasmacytoid monocytes in Jessner's lymphocytic infiltration of the skin. A valuable clue for the diagnosis. *Am J Dermatopathol*. 1991; 13: 321 - 328
13. Jahnsen FL, Farkas L, Lund-Johansen F, Brandtzaeg P. Involvement of plasmacytoid dendritic cells in human diseases. *Hum Immunol*. 2002; 63: 1201 - 1205
14. Farkas L, Beiske K, Lund-Johansen F, Brandtzaeg P, Jahnsen FL. Plasmacytoid dendritic cells (natural interferon- $\alpha$ /beta-producing cells) accumulate in cutaneous lupus erythematosus lesions. *Am J Pathol*. 2001; 159: 237 - 243
15. Wenzel J, Tuting T. Identification of type I interferon-associated inflammation in the pathogenesis of cutaneous lupus erythematosus opens up options for novel therapeutic approaches. *Exp Dermatol*. 2007; 16: 454 - 463
16. Wenzel J, Proelss J, Wiechert A, Zahn S, Bieber T, Tuting T. CXCR3-mediated recruitment of cytotoxic lymphocytes in lupus erythematosus profundus. *J Am Acad Dermatol*. 2007; 56: 648 - 650
17. Tian J, Avalos AM, Mao SY. Toll-like receptor 9-dependent activation by DNA-containing immune complexes is mediated by HMGB1 and RAGE. *Nat Immunol*. 2007; 8: 487 - 496
18. Obermoser G, Schwingshackl P, Weber F. Recruitment of plasmacytoid dendritic cells in ultraviolet irradiation-induced lupus erythematosus tumidus. *Br J Dermatol*. 2009; 160: 197 - 200
19. Nickoloff BJ, Nestle FO. Recent insights into the immunopathogenesis of psoriasis provide new therapeutic opportunities. *J Clin Invest*. 2004; 113: 1664 - 1675
20. Nestle FO, Conrad C, Tun-Kyi A. Plasmacytoid dendritic cells initiate psoriasis through interferon- $\alpha$  production. *J Exp Med*. 2005; 202: 135 - 143
21. Lande R, Giacomini E, Serafini B. Characterization and recruitment of plasmacytoid dendritic cells in synovial fluid and tissue of patients with chronic inflammatory arthritis. *J Immunol*. 2004; 173: 2815 - 2824
22. Lande R, Gregorio J, Facchinetti V. Plasmacytoid dendritic cells sense self-DNA coupled with antimicrobial peptide. *Nature*. 2007; 449: 564 - 569

- 23 . Albanesi C , Scarponi C , Pallotta S . Chemerin expression marks early psoriatic skin lesions and correlates with plasmacytoid dendritic cell recruitment . *J Exp Med* . 2009 ; 206 : 249 - 258
- 24 . Gilliet M , Conrad C , Geiges M . Psoriasis triggered by toll-like receptor 7 agonist imiquimod in the presence of dermal plasmacytoid dendritic cell precursors . *Arch Dermatol* . 2004 ; 140 : 1490 - 1495
- 25 . Hashizume H , Horibe T , Yagi H , Seo N , Takigawa M . Compartmental imbalance and aberrant immune function of blood CD123+ (plasmacytoid) and CD11c+ (myeloid) dendritic cells in atopic dermatitis . *J Immunol* . 2005 ; 174 : 2396 - 2403
- 26 . Wollenberg A , Wagner M , Gunther S . Plasmacytoid dendritic cells: a new cutaneous dendritic cell subset with distinct role in inflammatory skin diseases . *J Invest Dermatol* . 2002 ; 119 : 1096 - 1102
- 27 . Novak N , Bieber T . The role of dendritic cell subtypes in the pathophysiology of atopic dermatitis . *J Am Acad Dermatol* . 2005 ; 53 : S171 - 176
- 28 . De Vries HJ , van Marle J , Teunissen MB . Lichen planus is associated with human herpesvirus type 7 replication and infiltration of plasmacytoid dendritic cells . *Br J Dermatol* . 2006 ; 154 : 361 - 364
- 29 . de Vries HJ , Teunissen MB , Zorgdrager F , Picavet D , Cornelissen M . Lichen planus remission is associated with a decrease of human herpes virus type 7 protein expression in plasmacytoid dendritic cells . *Arch Dermatol Res* . 2007 ; 299 : 213 - 219
- 30 . Gerlini G , Mariotti G , Bianchi B , Pimpinelli N . Massive recruitment of type I interferon producing plasmacytoid dendritic cells in varicella skin lesions . *J Invest Dermatol* . 2006 ; 126 : 507 - 509
- 31 . Donaghy H , Bosnjak L , Harman AN . Role for plasmacytoid dendritic cells in the immune control of recurrent human herpes simplex virus infection . *J Virol* . 2009 ; 83 : 1952 - 1961
- 32 . Bontkes HJ , Ruizendaal JJ , Kramer D , Meijer CJ , Hooijberg E . Plasmacytoid dendritic cells are present in cervical carcinoma and become activated by human papillomavirus type 16 virus-like particles . *Gynecol Oncol* . 2005 ; 96 : 897 - 901
- 33 . Dhodapkar MV , Dhodapkar KM , Palucka AK . Interactions of tumour cells with dendritic cells: balancing immunity and tolerance . *Cell Death Differ* . 2008 ; 15 : 39 - 50
- 34 . Vermi W , Bonecchi R , Facchetti F . Recruitment of immature plasmacytoid dendritic cells (plasmacytoid monocytes) and myeloid dendritic cells in primary cutaneous melanomas . *J Pathol* . 2003 ; 200 : 255 - 268
- 35 . Salio M , Cella M , Vermi W . Plasmacytoid dendritic cells prime IFN-gamma-secreting melanoma-specific CD8 lymphocytes and are found in primary melanoma lesions . *Eur J Immunol* . 2003 ; 33 : 1052 - 1062
- 36 . Bailly C , Vergier B . Diagnostic des tumeurs mélaniques cutanées . Enseignement post universitaire . International Academy of pathology French Division ; 2005-2006 ;
- 37 . Wenzel J , Bekisch B , Uerlich M , Haller O , Bieber T , Tuting T . Type I interferon-associated recruitment of cytotoxic lymphocytes: a common mechanism in regressive melanocytic lesions . *Am J Clin Pathol* . 2005 ; 124 : 37 - 48
- 38 . Palamara F , Meindl S , Holcman M , Luhrs P , Stingl G , Sibilia M . Identification and characterization of pDC-like cells in normal mouse skin and melanomas treated with imiquimod . *J Immunol* . 2004 ; 173 : 3051 - 3061
- 39 . Steinmann A , Funk JO , Schuler G , von den Driesch P . Topical imiquimod treatment of a cutaneous melanoma metastasis . *J Am Acad Dermatol* . 2000 ; 43 : 555 - 556
- 40 . Wolf IH , Smolle J , Binder B , Cerroni L , Richtig E , Kerl H . Topical imiquimod in the treatment of metastatic melanoma to skin . *Arch Dermatol* . 2003 ; 139 : 273 - 276
- 41 . Zeitouni NC , Dawson K , Cheney RT . Treatment of cutaneous metastatic melanoma with imiquimod 5% cream and the pulsed-dye laser . *Br J Dermatol* . 2005 ; 152 : 376 - 377
- 42 . Naylor MF , Crowson N , Kuwahara R . Treatment of lentigo maligna with topical imiquimod . *Br J Dermatol* . 2003 ; 149 : (Suppl 66) 66 - 70
- 43 . Balch CM , Buzaid AC , Soong SJ . Final version of the American Joint Committee on Cancer staging system for cutaneous melanoma . *J Clin Oncol* . 2001 ; 19 : 3635 - 3648
- 44 . Molenkamp BG , van Leeuwen PA , Meijer S . Intradermal CpG-B activates both plasmacytoid and myeloid dendritic cells in the sentinel lymph node of melanoma patients . *Clin Cancer Res* . 2007 ; 13 : 2961 - 2969
- 45 . Molenkamp BG , Sluiter BJ , van Leeuwen PA . Local administration of PF-3512676 CpG-B instigates tumour-specific CD8+ T-cell reactivity in melanoma patients . *Clin Cancer Res* . 2008 ; 14 : 4532 - 4542
- 46 . Urošević M , Maier T , Benninghoff B , Slade H , Burg G , Dummer R . Mechanisms underlying imiquimod-induced regression of basal cell carcinoma in vivo . *Arch Dermatol* . 2003 ; 139 : 1325 - 1332
- 47 . Geisse J , Caro I , Lindholm J , Golitz L , Stampone P , Owens M . Imiquimod 5% cream for the treatment of superficial basal cell carcinoma: results from two phase III, randomized, vehicle-controlled studies . *J Am Acad Dermatol* . 2004 ; 50 : 722 - 733
- 48 . Strydom G , Bangert C , Tauber M , Strohal R , Kopp T , Stingl G . Tumouricidal activity of TLR7/8-activated inflammatory dendritic cells . *J Exp Med* . 2007 ; 204 : 1441 - 1451
- 49 . Hartmann E , Wollenberg B , Rothenfusser S . Identification and functional analysis of tumour-infiltrating plasmacytoid dendritic cells in head and neck cancer . *Cancer Res* . 2003 ; 63 : 6478 - 6487
- 50 . Della Bella S , Nicola S , Brambilla L . Quantitative and functional defects of dendritic cells in classic Kaposi's sarcoma . *Clin Immunol* . 2006 ; 119 : 317 - 329
- 51 . Arpinati M , Chirumbolo G , Urbini B , Perrone G , Rondelli D , Anasetti C . Role of plasmacytoid dendritic cells in immunity and tolerance after allogeneic hematopoietic stem cell transplantation . *Transpl Immunol* . 2003 ; 11 : 345 - 356
- 52 . Fugier-Vivier IJ , Rezzoug F , Huang Y . Plasmacytoid precursor dendritic cells facilitate allogeneic hematopoietic stem cell engraftment . *J Exp Med* . 2005 ; 201 : 373 - 383
- 53 . Chaperot L , Bendriss N , Manches O . Identification of a leukemic counterpart of the plasmacytoid dendritic cells . *Blood* . 2001 ; 97 : 3210 - 3217
- 54 . Jacob MC , Chaperot L , Mossuz P . CD4+ CD56+ lineage negative malignancies: a new entity developed from malignant early plasmacytoid dendritic cells . *Haematologica* . 2003 ; 88 : 941 - 955
- 55 . Bendriss-Vermare N , Chaperot L , Peoc'h M . In situ leukemic plasmacytoid dendritic cells pattern of chemokine receptors expression and in vitro migratory response . *Leukemia* . 2004 ; 18 : 1491 - 1498
- 56 . Chaperot L , Perrot I , Jacob MC . Leukemic plasmacytoid dendritic cells share phenotypic and functional features with their normal counterparts . *Eur J Immunol* . 2004 ; 34 : 418 - 426

**Figure 1**

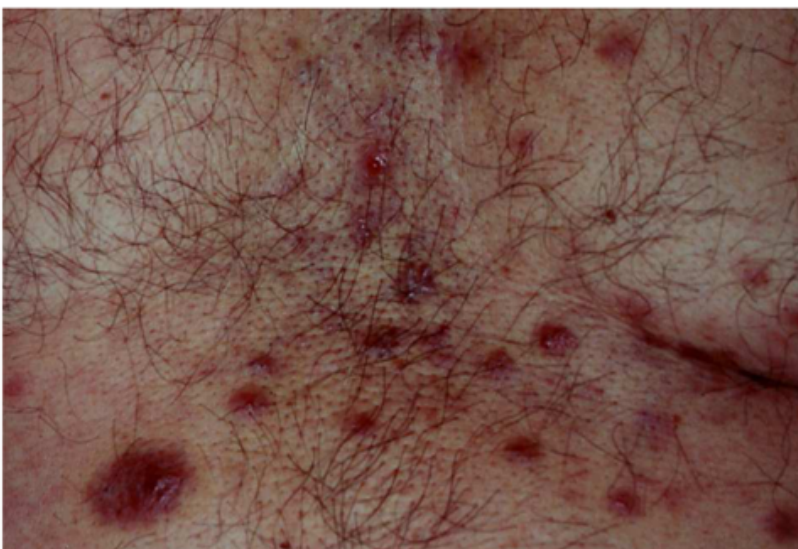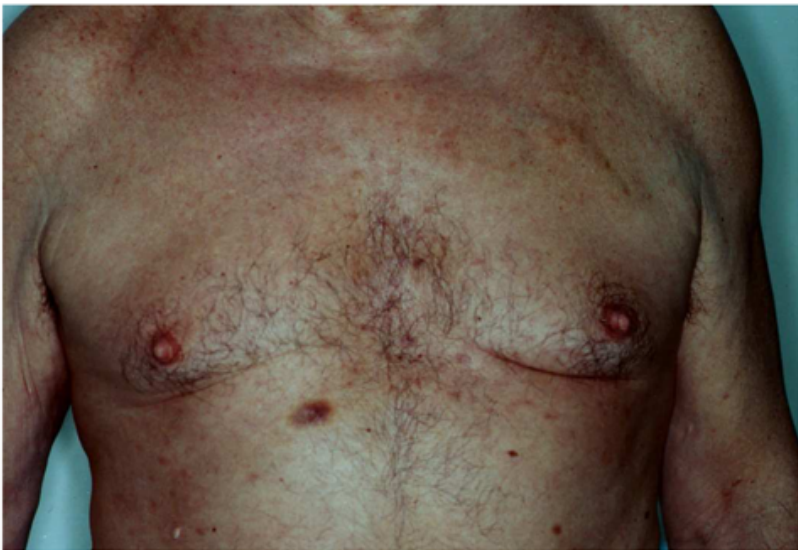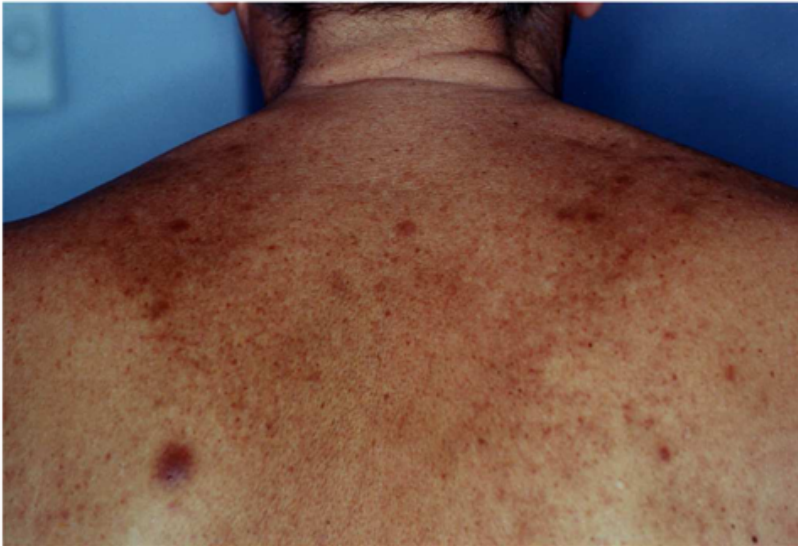Immuno-histochemical BDCA2 (Clone 104C12 Dendritics, Dardilly France) staining of a inflammatory regression area of a primary melanoma. Original magnification x40 and x400 for inset, diaminobenzidine (DAB) revelation.





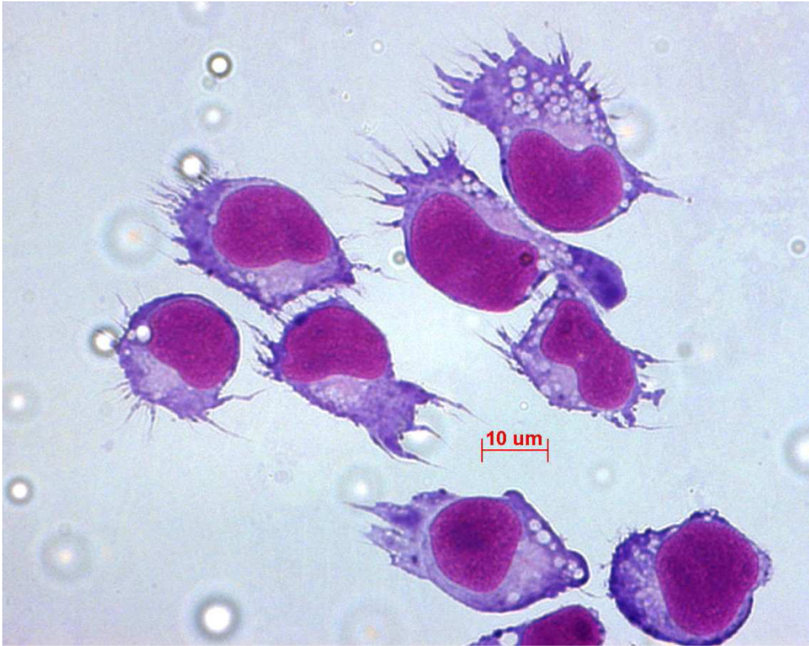**Figure 2**

Patient suffering from PDC leukemia. Cutaneous nodules of the trunk.



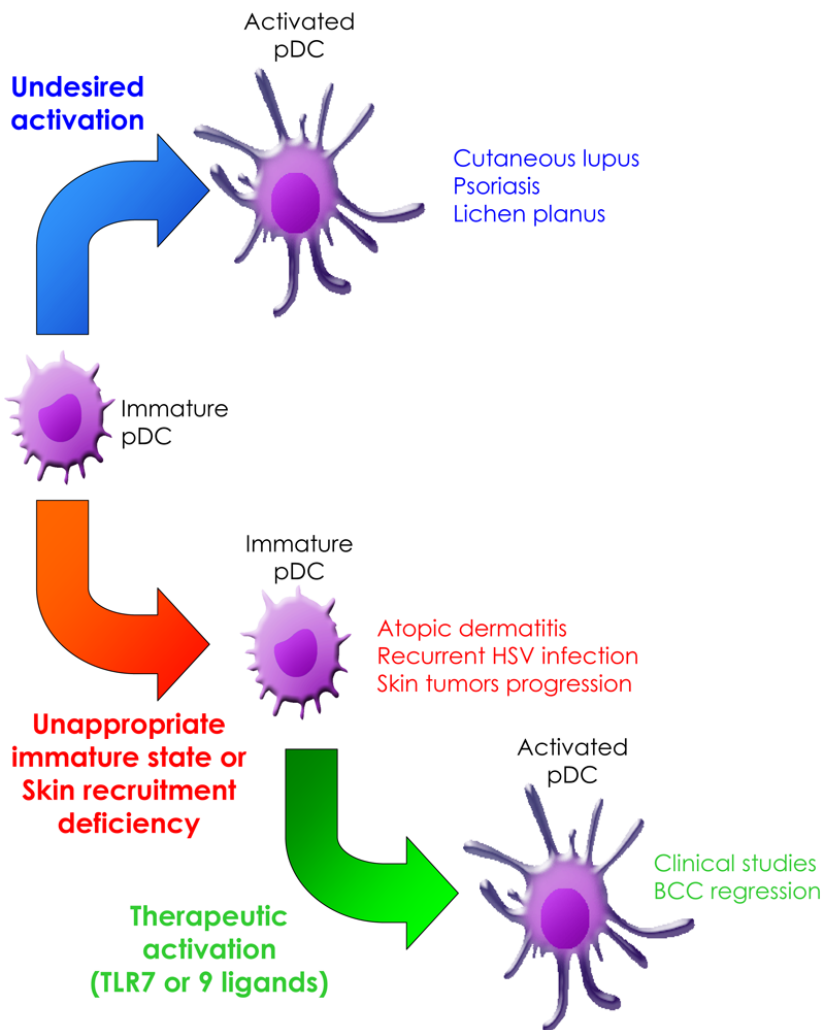
**Figure 3**

PDC of the GEN cell line after in vitro activation by influenza virus illustrating the typical morphology of virus activated PDC.



**Figure 4**

The role of PDC in various disease entities



**Table 1**

	<b>PDC</b>	<b>MDC</b>
Common characteristics of PDC and MDC	Negativity: <b>CD3</b> (T lymphocyte marker), <b>CD19</b> (B lymphocyte marker), <b>CD14</b> (monocyte marker), <b>CD56</b> (Natural Killer marker)	
Specific expression	Positivity: <b>CD4</b> , <b>HLA-DR</b> <b>BDCA2</b> (lectin family), <b>BDCA4</b> (neuropilin), <b>CD123</b> ( $\alpha$ chain of the IL3 receptor)	<b>CD11c</b> <b>CD116</b> (GM-CSF receptor or Granulocyte and Monocyte Colony Stimulating Factor). <b>CD13</b> (myeloid marker)