



American Journal of
Medical Genetics
Part A

Genotype-phenotype correlation in four 15q24 deleted patients identified by array-CGH.

Journal:	<i>American Journal of Medical Genetics: Part A</i>
Manuscript ID:	09-0316.R1
Wiley - Manuscript type:	Clinical Report
Date Submitted by the Author:	
Complete List of Authors:	<p>Andrieux, Joris; Hopital Jeanne de Flandre, CHRU LILLE et UFR II, Laboratoire de Génétique médicale</p> <p>Dubourg, Christèle; CHU de Rennes, Laboratoire de Génétique Moléculaire</p> <p>Attié-Bittach, Tania; Hôpital Necker-Enfants Malades, Département de Génétique</p> <p>Rio, Marlène; Hôpital Necker-Enfants Malades, Département de Génétique</p> <p>DELABY, Elsa; CHRU de Lille, Laboratoire de Génétique médicale</p> <p>Mathieu, Michèle; CHU d'Amiens, Service de Génétique Clinique</p> <p>Journel, Hubert; CH, genetics</p> <p>Copin, Henri; CHU d'Amiens, Laboratoire de Cytogénétique</p> <p>Blondeel, Eléonore; CHU d'Amiens, Laboratoire de Cytogénétique</p> <p>Doco-Fenzy, martine; CHU-HMB, genetics</p> <p>Delobel, Bruno; GHICL, Centre de Génétique chromosomique</p> <p>Odent, Sylvie; CHU Rennes, Génétique clinique</p> <p>MANOUVRIER-HANU, Sylvie; Service de génétique Clinique, University Hospital of Lille</p> <p>Holder-Espinasse, Muriel; Hopital Jeanne de Flandre, Medical Genetics</p>
Keywords:	15q24 deletion, genotype-phenotype correlation, array-CGH



Genotype-phenotype correlation in four 15q24 deleted patients identified by array-CGH

Joris ANDRIEUX¹, Christèle DUBOURG², Tania ATTIE-BITACH³, Marlène RIO³, Elsa DELABY¹, Michèle MATHIEU⁴, Hubert JOURNEL⁵, Henri COPIN⁶, Eléonore BLONDEEL⁶, Martine DOCO-FENZY⁷, Bruno DELOBEL⁸, Sylvie ODENT², Sylvie MANOUVRIER-HANU⁹, Muriel HOLDER-ESPINASSE⁹

1. Laboratoire de Génétique Médicale, Hôpital Jeanne de Flandre, CHRU, Lille, France
2. Laboratoire de Génétique Moléculaire, CHU, Rennes, France
3. Département de Génétique, Hôpital Necker-Enfants Malades, Paris, France
4. Service de Pédiatrie-Génétique, Hôpital Nord, CHU, Amiens, France
5. Génétique Médicale, Hôpital Chubert, CHBA, Vannes, France
6. Laboratoire de Cytogénétique, Hôpital Nord, CHU, Amiens, France
7. Service de Génétique, Hôpital Maison-Blanche, CHU, Reims, France
8. Centre de Génétique Chromosomique, Université Catholique, GHICL, Lille, France
9. Service de Génétique Clinique, Hôpital Jeanne de Flandre, CHRU, Lille, France

Correspondence to:

Joris Andrieux

Laboratoire de Génétique Médicale

Hôpital Jeanne de Flandre

59037 Lille Cedex

France

Tel: 0033320446121

Fax: 0033320446804

j-andrieux@chru-lille.fr

Abstract

Microdeletion 15q24 is an emerging syndrome recently described, mainly due to increased use of array-CGH. Clinical features associate mild to moderate developmental delay, typical facial characteristics (high forehead and frontal hairline, broad eyebrows, down-slanting palpebral features, long philtrum), hands (particularly proximal implanted thumbs) and genital anomalies (micropenis, hypospadias).

We report here four *de novo* cases having 2.5-6.1 Mb deletions involving 15q24: one 15q23q24.2 (patient 1) and three 15q24.1q24.2 deletions (patients 2, 3 and 4). We correlate phenotype to genotype according to molecular boundaries of these deletions. Since bilateral iris coloboma and severe ano-rectal malformation were only present in patient 1, we could link these anomalies to haploinsufficiency of 15q23 genes. Neither hypospadias nor micropenis were present in patient 3 bearing the smallest deletion, therefore we could define 500 kb 15q24.1 region linked to these anomalies.

Keywords: 15q24 deletion, genotype-phenotype correlation, array-CGH

Introduction

Microdeletion of 15q24 is a recent emerging syndrome mainly identified due to widespread use of array-CGH widespread use. Although there is an important phenotypic variability, patients may share some common findings, and these deletions could potentially represent a clinically identifiable syndrome (Sharp and others 2007). Clinical features therefore associate mild to moderate developmental delay, distinctive facial characteristics (high forehead and frontal hairline, broad eyebrows, down-slanting palpebral features, long philtrum), hand anomalies (particularly proximal placement of thumbs), and genital malformations in males (micropenis, hypospadias) (Cushman and others 2005; Sharp and others 2007) (Klopocki and others 2008). We report detailed studies of four patients with 15q24 deletions, having common features and compare these findings with 9 previously reported cases in the literature (Cushman and others 2005; Klopocki and others 2008; Masurel-Paulet and others 2009; Sharp and others 2007; Van Esch and others 2009).

Patients and Methods

Patient 1 is the first child of healthy non consanguineous parents, born after a previous early miscarriage. During pregnancy, intra uterine growth retardation (IUGR) was diagnosed at 26 weeks' gestation (WG). Later on, ventricular septal defect was identified on the third trimester ultrasound, together with single umbilical artery. Chromosome analysis and 22q11.2 FISH performed on amniotic fluid were normal. He was born at 35 WG by caesarean section performed for maternal preeclampsia, with a birth weight of 1.900 kg (10-25th centile), a length of 43 cm (10-25th centile), and a head circumference of 30 cm (10-25th centile). At birth, several malformations were identified including an imperforate anus, a bilateral iris coloboma, bilateral single

1
2
3
4 palmar creases, bilateral II-III toe syndactyly, hypoplastic 5th toes with absent 5th toe
5
6
7 nails, and a micropenis with a coronal hypospadias and a left cryptorchidism. The
8
9 cardiac malformation was confirmed. He was first referred to the genetic clinic at 4
10
11 months, having severe hypotonia and post natal growth retardation with a weight of -
12
13 4SD, a height of -3DS and a HC of -3SD. Striking dysmorphic features were identified
14
15 comprising of dysplastic asymmetric ears, large and high forehead, hypoplastic nasal
16
17 bridge, small nose with anteverted nares, up-slanting palpebral fissures, bilateral
18
19 epicanthus and a high palate (Fig. 1a). His skin appeared very dry. Later on, he
20
21 underwent surgery for left inguinal hernia where nystagmus was noted.
22
23
24

25
26 Developmental delay occurred secondarily. Head control was acquired at 19 months. At
27
28 2 years, he was sitting by himself and his growth parameters were in the normal range
29
30 with height -1SD, weight -1SD and HC -1SD. Unfortunately, he died at home by the
31
32 age of 25 months due to unknown cause. Parents declined post-mortem examination.
33

34
35 Several investigations were performed that includes, high resolution chromosome
36
37 banding which was normal, along with renal scan, skeletal x-rays, electromyogram and
38
39 nerve conduction velocities. Visual evoked potentials and 7-dehydrocholesterol were
40
41 also normal except brain MRI that revealed cerebral atrophy and enlarged ventricles.
42
43

44
45 **Patient 2** is the third child of healthy non consanguineous parents. He was born after a
46
47 normal pregnancy, at 38 WG with normal growth parameters (weight 3.170 kg, height
48
49 53 cm and HC 33 cm). Hypospadias was noted at birth in association with hypotonia
50
51 and short proximal implanted thumbs. Dysmorphic features comprising of high and
52
53 large forehead with small mouth were observed (Fig. 1b). Developmental delay
54
55 occurred later on, and walking independantly was achieved at 29 months. When referred
56
57 to the genetic clinic at 3 years, growth parameters were normal. However, joint laxity
58
59
60

was noted, but thumbs and facial features were still abnormal. High resolution chromosome banding was normal, along with renal and heart ultrasounds. However, skeletal x-rays revealed bilateral short first metacarpals, eye examination identified bilateral papilloedema and thick corpus callosum was noted on brain MRI.

Patient 3 is the second child born to healthy non consanguineous parents. During pregnancy, Fallot tetralogy was suspected and chromosomes including 22q11.2 by FISH analysis were observed to be normal on amniotic fluid. He was born at 39 WG, with normal growth parameters (weight 3.450 kg, height 49.5 cm and HC 35 cm). At birth, the cardiac anomaly was confirmed and he underwent several surgical interventions. Developmental delay was secondarily noted with head control achieved at 9 months, sitting at 15 months and walking at 3 years. Speech was also delayed (first words at 3 years). When referred to the genetic clinic at the age of 3 years, dysmorphic features were noted with asymmetric dysplastic ears, thin upper lip and widely-spaced teeth (Fig. 1c). His skin was dry. Eye examination revealed strabismus and hypermetropia. A bilateral sensorineural deafness was identified. High resolution chromosome banding was normal. Brain MRI revealed hypoplastic olfactory bulbs. Semi-circular canals were normal. *CHD7* molecular analysis was normal that ruled out CHARGE syndrome.

Patient 4 is the first child of healthy non consanguineous parents. During pregnancy, intra uterine growth retardation was noted. She was born at 37 WG with a weight of 1.850 kg, height of 45.5 cm and HC of 31 cm. At birth, dysmorphic facial features were noted with large and high forehead, flat midface, thin lips, small mouth and posteriorly rotated ears. Developmental delay was noted, with sitting at 11 months, walking at 2 ½ years and first words at 3 years. When reviewed in the genetic clinic at the age of 7

years, growth parameters were normal. Dysmorphic features were still present (Fig. 1d) with adducted thumbs and genu valgum. Eye examination revealed hypermetropia. High resolution chromosome banding was normal together with metabolic investigations, brain MRI and molecular analyses that ruled out Prader-Willi syndrome and Steinert disease.

Array-CGH analysis

Genomic DNA was extracted from the four patients' peripheral blood lymphocytes using the QIAamp DNA Blood Midi kit (Qiagen, Valencia, CA) according to the manufacturer's instructions. DNA concentration was determined with NanoDrop ND-1000 spectrophotometer and software (NanoDrop Technologies, Berlin, Germany). Detection of gene copy number was performed by array-Comparative Genomic Hybridization (array-CGH) experiments following standard and manufacturer's recommendations using 44,000 oligo probes approximately spaced at 40-100 kb intervals across the genome (Human Genome CGH microarray 44B kit, Agilent™). Male or female genomic DNA (Promega™) was used as reference in sex-match hybridizations which were analyzed with the CGH-analytics software v3.4 by applying Z-score segmentation algorithm with a window size of 10 points to identify chromosome aberrations. Analysis was performed with filter settings: 3-point filter and 0.2 of variation.

BACs and PACs DNAs were extracted by Macherey-Nagel kit (Nucleobond, 74579, Hoerd, France) and labelled with Cy3-dUTP (Amersham Bioscience, PA53022, GEhealthcare, Europe GmbH, Munich, Germany) by nick-translation (Nick Translation System, 18160-010, Invitrogen, San Diego, CA, USA). The Cy3-labelled DNA probe was precipitated and hybridized using standard procedures. Twenty metaphases were

analyzed under fluorescence DMRB microscope (Leica) equipped with Metasystem Isis software (Altussheim, Germany). The following academic BAC clone probes were used: on chromosome 15: RP11-375D9 (67.2 Mb), RP11-64K10 (68.7 Mb), RP11-141J4 (72.8 Mb), RP11-78M2 (74.5 Mb) (Sanger institute, UK).

Results

Array-CGH 44K Agilent™ showed 2.5-6.1 Mb deletions involving 15q24 (Fig. 2): one 15q23q24.2 (patient 1) and three 15q24.1q24.2 deletions (Table I).

FISH studies confirmed the 15q23q24.2 aberration elicited by array-CGH, since the RP11-64K10 and RP11-141J4 clones were deleted. The deletion was absent on parental DNA and appeared to be *de novo* in patient 1: 46,XY,ish del(15)(q23q24.2)(RP11-375D9+, RP11-64K10-, RP11-141J4-, RP11-78M2+)[25]dn. For the deleted 15q24.1q24.2 in patients 2, 3 and 4: RP11-141J4 clone was deleted and absence of deletion in the parents confirmed *de novo* origin.

Discussion

There are several reports of 15q deletions involving q24. However, to the best of our knowledge, only 7 published cases have been identified by array-CGH (Klopocki and others 2008; Masurel-Paulet and others 2009; Sharp and others 2007; Van Esch and others 2009). Taking together with our results we could define a 1.1 Mb region on 15q24.1q24.2 in which 23 genes are located. Among them, several are interesting in delineating the 15q24 deletion phenotype (table 2).

Patient 1 is bearing the largest deletion and showed the most severe phenotype. Additional clinical characteristics may thus be correlated to the 3Mb additional 15q23 deletion between 67.8 and 70.8 Mb.

Some of the common facial characteristics previously described in 15q24 deletion syndrome were observed in our patients, mainly high forehead (3/4) and dysplastic ears (3/4) (Cushman and others 2005; Klopocki and others 2008; Masurel-Paulet and others 2009; Van Esch and others 2009). Musculo-skeletal anomalies such as limb anomalies, joint laxity and scoliosis have also been frequently observed in 15q24 deleted patients. Malformations of the extremities were present in 3/4 patients with proximal implanted thumbs in patients 2 and 4 and bilateral single palmar creases and II-III toe syndactyly in patient 1.

Genital abnormalities in males are frequent in 15q24 deletion (Klopocki and others 2008). Hypospadias was present in two of the male patients (1 and 2) and absent in patient 3 bearing the smallest deletion. Thus we hypothesized that genital anomalies may be linked to the 15q24.2 genes deleted in patients 1 and 2 but not in patient 3, i.e. between chr15:73,316,640 and chr15:73,807,021 bp. Ten genes are located within these 490 kb and among them *SIN3A* and *ODF3L1* are significantly expressed in human testis and may potentially be involved. *CYP11A1* is strongly expressed in adrenal gland and haploinsufficiency of this gene may also contribute to the genital abnormalities seen in 15q24 deleted patients (Klopocki and others 2008). Although *CCDC33* is not deleted in patient 3, its strong expression in testis could be linked with genital anomalies in patients 1 and 2. Absence of genital anomalies in patient 3 may therefore be explained by incomplete penetrance, variable expressivity or other genes involvement.

Since eye abnormalities have been previously reported in the literature and also identified in our patients, we focused our attention on *STRA6* which is involved in syndromic autosomal recessive microphthalmia type 9 (MCOPS9). Bilateral iris coloboma was present in patient 1. Ophthalmologic examination of two patients with

15q22q25 and 15q21q24 deletions who died at the age of 2 years with respiratory problems showed hypopigmentation and coloboma of the iris in one of them (Formiga and others 1988). Among the 15q23 genes deleted in patient 1, *UACA* is expressed in the eye anterior segment (Ohkura and others 2004) as well as *PARP6* (Hassa and Hottiger 2008).

Patients 1, 2 and 3 showed different brain anomalies on MRI including hypoplastic olfactory bulbs in patient 3. *CPLX3* is strongly expressed in the brain and *SEMA7A* also. Semaphorins are involved in axon guidance during neuronal development and particularly in olfactory bulbs, hippocampus, pontine nucleus and thalamocortical axon (Maruyama and others 2008; Miyazaki and others 1999).

HCN4 is strongly expressed in the heart and loss of function of *HCN4* can be associated with sinus nodal dysfunction such as QT prolongation and polymorphic ventricular tachycardia which may lead to sudden unexpected death (Ueda and others 2004). Therefore, cardiac follow-up may be useful in 15q24 deleted patients. ECG had been performed in all 4 patients and was normal.

Array-CGH allowed in these 4 cases presenting with 15q24 microdeletion to compare their clinical features with previously reported cases, although it is still difficult to delineate specific diagnostic criteria for this rare microdeletion syndrome. We also suggest several candidate genes involvement in the neurological, genital and ophthalmological aspects of the phenotype.

Acknowledgments

The authors gratefully thank the parents for their cooperation.

Figure legends

Figure 1. Facial characteristics of the 4 patients. A: Patient 1. B: Patient 2. C: Patient 3. D: Patient 4. Note high and large forehead on patients 1, 2 and 4.

Figure 2. Schematic representation of 15q24 rearrangements published cases characterized by array-CGH with their respective breakpoints and recurrent breakpoints BP1, BP2 and BP3 (Sharp and others 2007). Our four cases are also represented and segmental duplications featured. Recurrent breakpoint 4 (BP4) is also represented (Masurel-Paulet and others 2009). Three of our patients' deletions have BP4 as proximal breakpoint.

Table 1. Phenotypic comparison between cases from (Cushman and others 2005; Klopocki and others 2008; Masurel-Paulet and others 2009; Sharp and others 2007; Van Esch and others 2009) and our 4 patients. HC: head circumference. ENT: Ear-Nose-Throat.

Table 2. Genes potentially involved in the 15q24 phenotype.

Electronic database

UCSC Genome Browser on Human March 2006 Assembly - hg18:
<http://genome.ucsc.edu/cgi-bin/hgGateway?org=human>.

EMBL-EBI microarray database: <http://www.ebi.ac.uk/microarray-as/atlas/>

REFERENCES

Cushman LJ, Torres-Martinez W, Cherry AM, Manning MA, Abdul-Rahman O, Anderson CE, Punnett HH, Thurston VC, Sweeney D, Vance GH. 2005. A report of three patients with an interstitial deletion of chromosome 15q24. *Am J Med Genet Part A* 137A:65-71.

Formiga LD, Poenaru L, Couronne F, Flori E, Eibel JL, Deminatti MM, Savary JB, Lai JL, Gilgenkrantz S, Pierson M. 1988. Interstitial deletion of chromosome 15: two cases. *Hum Genet* 80:401-404.

Hassa PO, Hottiger MO. 2008. The diverse biological roles of mammalian PARPS, a small but powerful family of poly-ADP-ribose polymerases. *Front Biosci* 13:3046-3082.

Klopocki E, Graul-Neumann LM, Grieben U, Tonnies H, Ropers HH, Horn D, Mundlos S, Ullmann R. 2008. A further case of the recurrent 15q24 microdeletion syndrome, detected by array CGH. *Eur J Pediatr* 167:903-908.

Maruyama T, Matsuura M, Suzuki K, Yamamoto N. 2008. Cooperative activity of multiple upper layer proteins for thalamocortical axon growth. *Dev Neurobiol* 68:317-331.

Masurel-Paulet A, Callier P, Thauvin-Robinet C, Chouchane M, Mejean N, Marle N, Mosca AL, Salem DB, Giroud M, Guibaud L and others. 2009. Multiple cysts of

the corpus callosum and psychomotor delay in a patient with a 3.1 Mb 15q24.1q24.2 interstitial deletion identified by array-CGH. *Am J Med Genet Part A* 149A:1504-1510.

Miyazaki N, Furuyama T, Sakai T, Fujioka S, Mori T, Ohoka Y, Takeda N, Kubo T, Inagaki S. 1999. Developmental localization of semaphorin H messenger RNA acting as a collapsing factor on sensory axons in the mouse brain. *Neuroscience* 93:401-408.

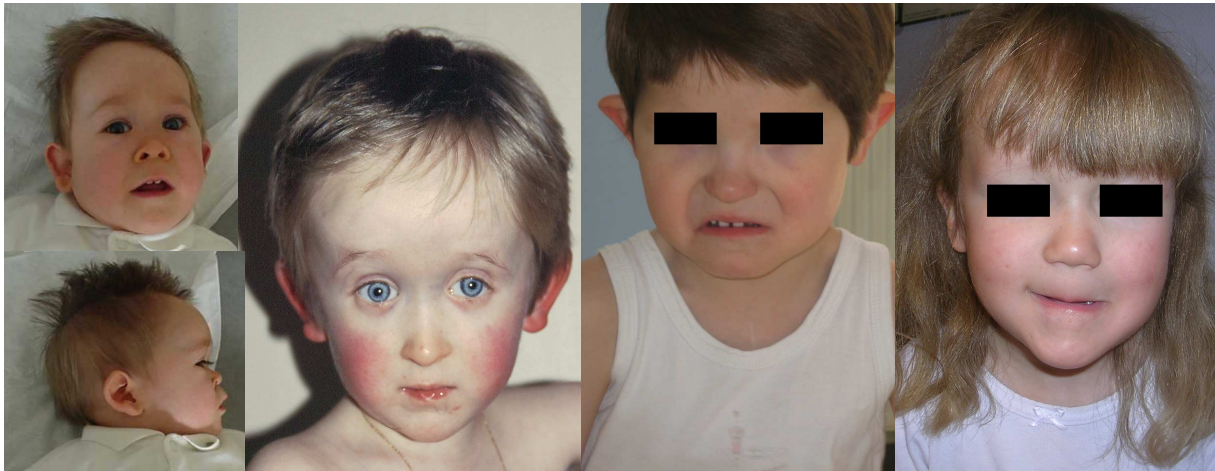Ohkura T, Taniguchi S, Yamada K, Nishio N, Okamura T, Yoshida A, Kamijou K, Fukata S, Kuma K, Inoue Y and others. 2004. Detection of the novel autoantibody (anti-UACA antibody) in patients with Graves' disease. *Biochem Biophys Res Commun* 321:432-440.

Sharp AJ, Selzer RR, Veltman JA, Gimelli S, Gimelli G, Striano P, Coppola A, Regan R, Price SM, Knoers NV and others. 2007. Characterization of a recurrent 15q24 microdeletion syndrome. *Hum Mol Genet* 16:567-572.

Ueda K, Nakamura K, Hayashi T, Inagaki N, Takahashi M, Arimura T, Morita H, Higashiuesato Y, Hirano Y, Yasunami M and others. 2004. Functional characterization of a trafficking-defective HCN4 mutation, D553N, associated with cardiac arrhythmia. *J Biol Chem* 279:27194-27198.

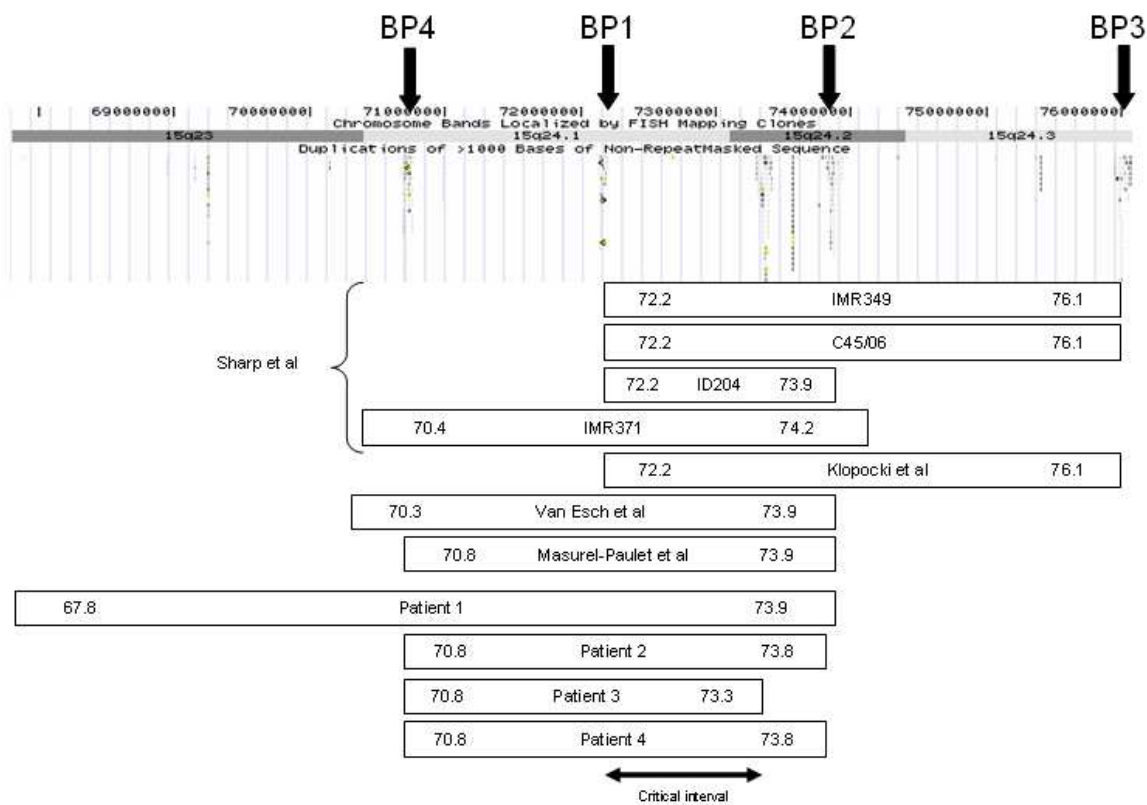
Van Esch H, Backx L, Pijkels E, Fryns JP. 2009. Congenital diaphragmatic hernia is part of the new 15q24 microdeletion syndrome. *Eur J Med Genet* 52:153-156.

Figure 1.



or
Peer
Review

Figure 2



	Patient 1 15q23q24.2 deletion	Patient 2 15q24.1q24.2 deletion	Patient 3 15q24.1q24.2 deletion	Patient 4 15q24.1q24.2 deletion	(Cushman and others 2005) 3 cases (Sharp and others 2007) 4 cases (Klopocki and others 2008) 1 case (Van Esch and others 2009) 1 case (Masurel-Paulet and others 2009) 1 case
Array-CGH hg18	67,807,119-73,907,050	70,764,625-73,807,021	70,764,684-73,316,640	70,764,625-73,806,962	available from (Klopocki and others 2008), (Sharp and others 2007), (Van Esch and others 2009) and (Masurel-Paulet and others 2009)
Birth parameters	33WG weight: 1900g height: 43 cm HC: 30 cm	38 WG weight: 3170g height: 53 cm HC: 33 cm	39 WG weight: 3450g height: 49,5 cm HC: 35 cm	37 WG weight: 1850g height: 45,5cm HC: 31cm	
Sex, age at diagnosis	M, 2 years	M, 3 years	M, 7 years	F, 5 years	9 M, 1 F 13 months to 33 years
Facial characteristics	large and high forehead hypoplastic nasal bridge small nose with anteverted nares up-slanting palpebral fissures bilateral epicanthus high palate	large and high forehead small mouth	thin upper lip widely-spaced teeth	large and high forehead thin lips flat midface down-slanting palpebral fissures	high forehead (7/7) broad medial eyebrows (6/7) hypertelorism (6/7) epicanthal folds (4/8) down-slanting palpebral fissures (6/7) long and smooth philtrum (7/7) full lower lip (5/6) broad nasal base (3/5) micrognathia (3/8)
Eye abnormalities	bilateral iris coloboma nystagmus	papilloedema	strabismus hypermetropia	hypermetropia	strabismus (5/7) nystagmus (1/5)
Ear abnormalities	dysplastic asymmetric ears	no	dysplastic asymmetric ears	posteriorly rotated ears	5/8
Limb abnormalities	bilateral single palmar creases bilateral II-III toe syndactyly hypoplastic 5 th toes	short and proximal placed thumbs	no	adducted thumbs genu valgum	thumbs anomalies (4/8) other fingers anomalies (6/8)
Musculo-skeletal abnormalities	no	joint laxity	no	no	joint laxity (4/8) scoliosis (2/7)
Genital abnormalities	micropenis/coronal hypospadias left ectopic testis	hypospadias	no	no	hypospadias, micropenis and/or small scrotum (8/9)
Developmental delay	head control at 19 months sitting at 2 years	walking at 29 months	sitting at 15 months walking at 3 years first words at 3 years	sitting at 11 months walking at 2 years first words at 3 years	mild to moderate mental retardation (10/10)
Microcephaly	no	no	no	no	3/10
Neurological findings	cerebral atrophy enlarged ventricles	thick corpus callosum	hypoplastic olfactory bulbs	no	wide basal cisterna (1/5) dysplastic corpus callosum hypoplasia of the adenohypophysis and ectopic neurohypophysis (1/5) cysts in the corpus callosum (1/5)
Cardiovascular abnormalities	ventricular septal defect	no	Fallot tetralogy	no	pulmonary stenosis (1/4)
Recurrent infections		no	no	ENT	ENT (3/4)
Deafness/hearing loss		no	bilateral sensorineural deafness		deafness/hearing loss (2/5)
Skin	dry	normal	dry	normal	
Other	left inguinal hernia imperforate anus				inguinal hernia (3/9) growth hormone deficiency (2/3) delayed puberty (2/2)

Table 1

Gene	Expression	Function	Localization	Animal model
SIN3A (transcriptional co-repressor Sin3A)	Testis	Transcriptional regulatory protein, histone deacetylase interacting	15q24.2	No known KO
ODF3L1 (outer dense fiber of sperm tails 3-like 1)	Testis	Transport of keratins to microtubule-containing structures such as the manchette and axoneme during mammalian spermiogenesis	15q24.2	No known KO
CYP11A1 (cytochrome P450, family 11, subfamily A, polypeptide 1)	Adrenal glands	Localizes to the mitochondrial inner membrane and catalyzes the conversion of cholesterol to pregnenolone	15q24.1	No known KO
CCDC33 (coiled-coil domain containing 33)	Testis	C2 calcium-dependent membrane targeting, down-regulated in cryptorchidism	15q24.1	No known KO
STRA6 (stimulated by retinoic acid gene 6 homolog)	Eye	Receptor for retinol/retinol binding protein complexes. Removes the retinol from the complex and transports it across the cell membrane	15q24.1	No known KO Defects in this gene cause syndromic microphthalmia type 9 (MCOPS9).
UACA (uveal autoantigen with coiled-coil domains and ankyrin repeats)	Eye	Recruits and transports the apoptosome complex during stress-induced apoptosis	15q23	No known KO
PARP6 (poly (ADP-ribose) polymerase family, member 6)	Testis, eye	NAD ⁺ ADP-ribosyltransferase activity	15q23	No known KO
CPLX3 (complexin 3)	Brain, eye	Positive regulator of neurotransmitter release in mouse hippocampal neurons, syntaxin binding	15q24.1	No known KO
SEMA7A (semaphorin 7A)	Brain	Mediate neuronal functions	15q24.1	No known KO Defects in this gene can result in loss of bone mineral density
HCN4 (hyperpolarization activated cyclic nucleotide-gated potassium channel 4)	Heart	Necessary for the cardiac pacemaking process	15q24.1	No known KO Mutations in this gene have been linked to sick sinus syndrome 2

Table 2