



Ciliary defects and genetics of primary ciliary dyskinesia.

Estelle Escudier, Philippe Duquesnoy, Jean-François Papon, Serge Amselem

► To cite this version:

Estelle Escudier, Philippe Duquesnoy, Jean-François Papon, Serge Amselem. Ciliary defects and genetics of primary ciliary dyskinesia.. Paediatric Respiratory Reviews, 2009, 10 (2), pp.51-4. 10.1016/j.prrv.2009.02.001 . inserm-00406504

HAL Id: inserm-00406504

<https://inserm.hal.science/inserm-00406504>

Submitted on 22 Jul 2009

HAL is a multi-disciplinary open access archive for the deposit and dissemination of scientific research documents, whether they are published or not. The documents may come from teaching and research institutions in France or abroad, or from public or private research centers.

L'archive ouverte pluridisciplinaire **HAL**, est destinée au dépôt et à la diffusion de documents scientifiques de niveau recherche, publiés ou non, émanant des établissements d'enseignement et de recherche français ou étrangers, des laboratoires publics ou privés.

Ciliary defects and genetics of primary ciliary dyskinesia

Estelle Escudier¹, MD PhD : estelle.escudier@trs.aphp.fr

Philippe Duquesnoy¹, BA: philippe.duquesnoy@trs.aphp.fr

Jean François Papon^{1, 2}, MD: jean-francois.papon@hmn.aphp.fr

Serge Amselem¹, MD PhD: serge.amsellem@trs.aphp.fr

Address:

1. AP-HP, Service de Génétique et d'Embryologie médicales and Inserm U.933

Hôpital Armand-Trousseau

26, avenue du Docteur Arnold-Netter

75571 Paris Cedex 13, France

Phone: + 33 1 44 73 52 39

Fax: + 33 1 44 73 52 19

2. AP-HP, Service d'ORL et de chirurgie cervico-faciale, Groupe hospitalier Henri-Mondor et Hôpital intercommunal and Inserm U.955 Créteil, F-94010, France

Phone: + 33 1 49 81 22 25

Fax: + 33 1 49 81 24 23

Acknowledgments:

This work was supported by grants from the Legs Poix from the Chancellerie des Universités, the Assistance Publique-Hôpitaux de Paris (PHRC AOM06053, P060245) and the Agence Nationale pour la Recherche (ANR-05-MRAR-022-01).

Abstract

Cilia are evolutionarily conserved structures that play key roles in diverse cell types. Motile cilia are involved in the most prominent ciliopathy called primary ciliary dyskinesia (PCD) that combines respiratory symptoms, male infertility, and, in half cases, *situs inversus*. The diagnosis of PCD relies on the identification of ciliary abnormalities that mainly concern outer and/or inner dynein arms (ODA, IDA). PCD is a genetic condition, usually inherited as an autosomal recessive trait. To date, six genes have been clearly implicated in PCD. Two “major” genes, *DNAI1* and *DNAH5*, underlie PCD in nearly half of the patients with ODA defects, whereas *RPGR*, *DNAH11* and *TXNDC3* are implicated in rare families with specific phenotypes (retinitis pigmentosa, abnormal beating of structurally normal cilia, and *situs ambiguous*, respectively). The relative contribution of *DNAI2*, is currently assessed. In all the other patients with ODA or other ultrastructural defects, the causative genes remain to be identify.

Key words : primary ciliary dyskinesia (PCD), cilia, genetics, Kartagener syndrome, dynein, situs inversus, mutations

Introduction

The history of primary ciliary dyskinesia (PCD) began with the 20th century when A. Siewert noticed the surprising association of bronchiectasis and *situs inversus*¹. In 1933, this association was formalised by M. Kartagener who described the triad of sinusitis, bronchiectasis, and *situs inversus*. Some forty years later, B. Afzelius identified in the axoneme of respiratory cilia and sperm flagella of patients with Kartagener syndrome the underlying ultrastructural defect corresponding to an absence of dynein arms². By the end of the 20th century, *DNAIL*, the human ortholog of the *Chlamydomonas reinhardtii* gene *IC78*, was identified as the first gene involved in PCD³, thereby opening up a new field of research to decipher the pathophysiology of this complex disorder.

Ciliary structure

Cilia are evolutionarily conserved complex structures that protrude from the apical surface of most eukaryotic cells⁴. These organelles, which are structurally related to the flagella of spermatozoa, can be classified according to the arrangement of their microtubule cytoskeleton core, called axoneme. The axoneme consists either of nine doublets only («9+0» pattern) or of nine outer-doublet microtubules surrounding a central pair of single microtubules («9+2» pattern). The «9+0» *primary cilia* are immotile, except in the embryonic node where they are involved in left-right asymmetry. In mammals, primary cilia are present on most cells where they have mechanosensory properties, acting as antennae, sensing the external environment, while sensory cilia play key roles in vision and olfaction. The «9+2» *motile cilia* are always motile, are involved in the transport of extracellular fluids; for example, ciliated epithelium can be found in the respiratory tract, the brain ependyma, the female oviduct and the male vas deferens. Most importantly, respiratory cilia propel mucus along the respiratory tract and represent, therefore, the first line of airway defences⁵.

The axonemal proteins have been shown to be extremely conserved throughout evolution from lower eukaryotes, like the unicellular green algae *Chlamydomonas*, to mammals⁶. The axoneme of motile cilia (Fig.1) consists of α and β tubulin heterodimers arranged in protofilaments to form microtubules. Each peripheral doublet is composed of an A microtubule (13 protofilaments) and a B

microtubule (11 protofilaments) surrounding a central complex (CC) consisting of two single microtubules (C1 and C2) inside a central sheath. Nexin links and radial spokes are multiprotein complexes that interconnect the adjacent peripheral doublets to each other and to the central microtubules, respectively. The inner dynein arms (IDA) and the outer dynein arms (ODA), bound to each A peripheral microtubules with certain periodicity, are the transducers of mechanical forces necessary for ciliary motion via a number of complex cell events including phosphorylation/dephosphorylation of key proteins⁴. Detailed structural and biochemical studies of dynein arms have been performed in various species including sea urchin and *Chlamydomonas reinhardtii*. These studies have revealed that dynein arms are large multisubunit molecular motors formed by the assembly of heavy, intermediate and light chains (HC of 400-500 kDa, IC of 45-110 kDa and LC of 8-55 kDa, respectively). The ODA is composed of three or two HCs (α , β , γ), depending on species (only β and γ in humans), two ICs and 8 LCs. Dynein HCs provide, through ATPase activity, the energy necessary for ciliary beating. The IDAs are more complex with at least seven different isoforms: one with two HCs and each of the six other isoforms contains a different HC; each isoform includes different ICs and LCs⁷. Assembly and maintenance of cilia and flagella are dependent on intraflagellar transport (IFT). IFT is an intracellular motility system, by which large protein complexes called IFT particles are transported bidirectionally between the cell membrane and the outer doublet microtubules of cilia and flagella. IFT, which was first described in *Chlamydomonas*, has subsequently been found to be essential for the assembly of motile and sensory cilia in many organisms including mice⁸.

Ciliary defects

Cilia play key physiological and developmental roles in diverse cell types and organisms. In mammals, defects in primary cilia cause a wide range of disorders such as cystic diseases and/or sensorial disorders, while motile cilia are involved in the most prominent ciliopathy called primary ciliary dyskinesia (PCD). PCD (MIM 242650) is a rare respiratory disease due to impaired mucociliary clearance resulting from functional and ultrastructural abnormalities of respiratory cilia^{9, 10}. It represents a heterogeneous group of genetic disorders, usually beginning in early childhood.

Approximately half of the patients with PCD display a *situs inversus*, thereby defining the Kartagener syndrome (MIM 244400). This complex phenotype, i.e. chronic airway infections, *situs inversus* and male infertility, is now clearly explained by a single event involving the axonemal structure found in motile respiratory, embryonic nodal cilia, and flagella of spermatozoa, respectively.

The diagnosis of PCD is therefore based on the identification of functional and structural abnormalities of cilia (Fig.2). In most patients with PCD, all the cilia share the same ultrastructural defect, as expected for a congenital disease. However, depending on the patients, cilia have been shown to carry various axonemal abnormalities. The first ultrastructural defect that has been reported in patients with PCD was the absence of dynein arms that are essential for ciliary motion¹¹. The main ciliary defect concerns dynein arms in more than 80% of cases, and involves more frequently ODA than IDA^{12, 13}. Other axonemal abnormalities concern the central complex or the radial spokes (axonemal disorganization). In our 20-year experience, as in literature, the spectrum of ultrastructural defects in PCD is as follows: 24 to 43% of isolated ODA defects, 24 to 45% of defects involving both dynein arms, 14 to 29% of isolated IDA defects, and 4 to 18% of CC defects¹²⁻¹⁶. Ciliary motility seems to be related to the type of ciliary defects: most of the cilia are immotile when both dynein arms or outer dynein arms are affected^{13, 14, 17-19}, while the ciliary beating pattern seems abnormal with reduced amplitude in case of inner dynein arm defects¹⁹. In case of anomalies of the central complex, the ciliary beating pattern is abnormal^{12, 17, 20}. In 10-20% of patients, no ultrastructural defects can be found through conventional electron microscopy, although cilia are immotile^{3, 5, 14, 21, 22}. In these patients, the diagnosis of PCD is based on the presence of typical clinical features (including *situs inversus*) with the absence of ciliary motion. In these cases, a low level of nasal nitric oxide might be very helpful to assert the diagnosis of PCD. It has been proposed that the defect could concern some enzymes associated with various axonemal structures²³. In fact, Kartagener syndrome with normal cilia is not an exceptional condition²⁴⁻²⁶. As a consequence, and because of random lateralization, it is tempting to speculate that the same proportion of “true” patients with PCD, but with normal cilia and without *situs inversus*, should exist.

PCD inheritance

In most instance, the transmission pattern of PCD is consistant autosomal recessive inheritance of the disease¹¹, although rare families showing autosomal dominant or X-linked modes of inheritance have also been reported²⁷⁻²⁹. The incidence of PCD ranges from 1/15,000 to 1/60,000 alive births¹¹, while that of Kartagener syndrome is estimated to range between 1/30,000 and 1/20,000 live births. However, the frequency of the disease is markedly underestimated, especially when *situs inversus* is absent and/or when ultrastructure is normal.

As predicted from the high complexity of ciliary structure and function, there is ample room for genetic heterogeneity in PCD. Each of the several hundreds of proteins that constitute a cilia could potentially cause the disease. Such complexity makes approaches based on genetic linkage difficult to apply; except in case of large and/or consanguineous families, a situation which is exceptional. Alternative approaches rely on the fact that (i) the structure of the ciliary axoneme is highly conserved across species and (ii) the protein components of a protozoan axoneme, such as those found in *Chlamydomonas reinhardtii*, and those of mammalian cilia are highly homologous at the sequence level⁶. Strikingly, several immotile strains of *Chlamydomonas* carry axonemal ultrastructural defects that are reminiscent of those reported in patients with PCD; this observation led to the development of a candidate-gene approach based on *Chlamydomonas* mutants. It enabled the characterization of the first gene involved in PCD, called *DNAI1* that encodes a dynein intermediate chain of the ODA³.

PCD genes (Table I)

DNAI1, which is located in the p21-p23 region of chromosome 9, comprises 20 exons spanning about 62 kb of genomic DNA. It encodes a 699-amino-acid protein orthologous to the *Chlamydomonas* ODA protein IC78. Mutations in *DNAI1* have been found in several PCD patients including patients with Kartagener syndrome^{3, 30-32}. Although allelic heterogeneity was noted in the very first studies, it was secondarily shown that the IVS1+2_3insT mutation, which accounts for about half the mutated alleles, results in fact from a founder effect³². As so far, mutations in *DNAI1*

have always been found in association with ODA defects and account for about 14% of those patients³².

Thanks to a genetic linkage analysis performed in one large consanguineous multiplex family, mutations have been identified in a second gene encoding a dynein heavy chain, ***DNAH5***^{33 34}. *DNAH5*, located on chromosome 5, codes for a protein orthologous of the *Chlamydomonas* γ -axonemal heavy chain of the ODA. The human *DNAH5* gene, which spans 250 kb, comprises 80 exons. So far, *DNAH5* mutations have been found only in patients with partial or total loss of ODA associated or not with left-right asymmetry anomalies^{34, 35}. The *DNAH5* mutation detection rate was shown to reach 49% in a subset of PCD families with documented ODA defects³⁵.

A third candidate gene (***DNAH11***) has first been involved in a patient with a complex phenotype associating cystic fibrosis, *situs inversus* and a paternal uniparental isodisomy of chromosome 7, a chromosome that carries both the *CFTR* and *DNAH11* genes³⁶. *DNAH11*, which encodes also a dynein heavy chain, comprises 82 exons, spanning more than 353 kb of the p21 region of chromosome 7. The patient was shown to be homozygous for the F508del mutation of the *CFTR* gene, and for the R2852X nonsense mutation in *DNAH11*. Notably, a missense mutation had been identified in the *Dnah11* gene of the *iv/iv* (*inversus viscerum*) mouse characterized by immotile cilia of the embryonic node and random organ lateralization³⁷. Secondly, compound heterozygous *DNAH11* mutations were identified in a large family in which five individuals have PCD and one has Kartagener syndrome. Respiratory cilia from affected individuals showed a normal axonemal ultrastructure but an abnormal ciliary beating pattern with a reduced bending capacity and a hyperkinetic beat. Mutations in *DNAH11*, therefore, do not result in axonemal ultrastructural defect detectable by electron microscopy, but are believed to affect motor function²⁶.

PCD may also be caused by mutations in *RPGR* (retinitis pigmentosa guanosine triphosphatase regulator), the most common gene involved in X-linked retinitis pigmentosa or *TXNDC3* that codes for a protein belonging to the thioredoxin superfamily. The ***RPGR* gene**, located on the p21.1 region of the chromosome X is essential for photoreceptor maintenance and viability; it is also expressed in respiratory ciliated cells³⁸. In rare instances, typical symptoms of PCD have been reported in males

with retinitis pigmentosa^{28, 39, 40}. More recently, a 57-bp intragenic deletion of this gene has been identified in one family in which two boys present a complex phenotype combining PCD with retinitis pigmentosa. Ciliary investigations showed immotile cilia and various ultrastructural abnormalities with partial dynein arm defects²⁹. This finding, which underlines the importance of *RPGR* in the development of axonemal structures in photoreceptors and in respiratory cilia, represents the first clear demonstration of an X-linked transmission of the PCD phenotype. *TXNDC3*, which encodes a thioredoxine-nucleoside diphosphate kinase, is expressed in testis and respiratory epithelial cells. This gene was considered as a candidate for PCD because it represents the human ortholog of the sea urchin *IC1* gene that encodes a component of sperm ODA⁴¹; it was therefore tested in a series patients with PCD and ODA abnormalities. In a young girl with PCD and *situs ambiguus* was identified a nonsense mutation combined, in *trans*, with an intronic SNP controlling the respective amounts of two physiological *TXNDC3* isoforms generated by alternative splicing⁴² and shown to display different binding properties to microtubules.

Just recently, several loss-of-function mutations have been identified in the *DNAI2* gene of patients with ODA defect⁴³, therefore confirming that *DNAI2* which is located on the q25 region of chromosome 17, was indeed a good candidate gene for PCD⁴⁴.

A number of other candidate genes for PCD (such as *DNAH9*, *HP28*, *DPCD*, *SPAG16*, *HFH-4*)⁴⁵ have been selected for mutation screening in PCD patients, but, so far, no mutations have been reported. In addition, approaches based on positional cloning have pointed to several possible PCD loci (e.g. 1q23.1-q32.1, 7p14.2-12.2, 15q13.1-15.1, 15q24-25, 16p12.1-12.2, 19q13.3-qter regions)⁴⁶⁻⁵¹; the causative genes are still to be identified.

Conclusion

The molecular basis of PCD is just beginning to be elucidated. To date, despite substantial efforts made for many years by several groups and the recent availability of huge sequence information, only six genes (*DNAI1*, *DNAH5*, *DNAH11*, *RPGR*, *TXNDC3* and *DNAI2*) have been clearly implicated in PCD. Two of them, *DNAI1* and *DNAH5*, which underly the disease in about 25% of the patients with

PCD, represent major genes, while three others (*RPGR*, *DNAH11*, *TXNDC3*), are “minor” genes, implicated in only few families. The relative contribution of *DNAI2* to the pathology remains to be determined. Although *DNAI1* and *DNAH5* mutations underlie PCD in nearly half of patients with ODA defects, for all the other patients with ODA defects or with other ultrastructural phenotypes, the genes responsible for their ciliary defect are still to be identified. This is an important task for a better management of the disease (e.g. development of new diagnostic methods and of more efficient treatments). This research should also provide new insights into the molecular mechanisms involved in the assembly and function of cilia, as well as in the determination of laterality.

References

1. Siewert. Ueber einen fall von bronchiectasie bei einem patienten mit situs inversus viscerum. Berliner klinische wochenschrift 1904; 41: 139-41.
2. Kartagener, M. Zur pathogenese der bronchiectasien. Bronchiectasien bie situs inversus viscerum. Beitr Klin Tuberk 1933; 83: 489-501.
3. Pennarun, G, Escudier, E, Chapelin, C et al. Loss-of-function mutations in a human gene related to Chlamydomonas reinhardtii dynein IC78 result in primary ciliary dyskinesia. Am J Hum Genet 1999; 65: 1508-19.
4. Haimo, L TRosenbaum, J L. Cilia, flagella, and microtubules. J Cell Biol 1981; 1991: 125s-30s.
5. Satir, PChristensen, S T. Overview of structure and function of mammalian cilia. Annu Rev Physiol 2007; 17: 377-400.
6. Hook, PVallee, R B. The dynein family at a glance. J Cell Sci 2006; 119: 4369-71.
7. Porter, M E. Axonemal dyneins: assembly, organization, and regulation. Curr Opin Cell Biol 1996; 8: 10-7.
8. Rosenbaum, J LWitman, G B. Intraflagellar transport. Nat Rev Mol Cell Biol 2002; 3: 813-25.
9. Afzelius, B A. A human syndrome caused by immotile cilia. Science 1976; 193: 317-9.
10. Rossman, C M, Forrest, J B, Ruffin, R ENewhouse, M T. Immotile cilia syndrome in persons with and without Kartagener's syndrome. Am Rev Respir Dis 1980; 121: 1011-6.
11. Afzelius, B A. The immotile-cilia syndrome: a microtubule-associated defect. CRC Crit Rev Biochem 1985; 19: 63-87.

12. Chilvers, M A, Rutman, AO'Callaghan, C. Ciliary beat pattern is associated with specific ultrastructural defects in primary ciliary dyskinesia. *J Allergy Clin Immunol* 2003; 112: 518-24.
13. Noone, P G, Leigh, M W, Sannuti, A et al. Primary ciliary dyskinesia: diagnostic and phenotypic features. *Am J Respir Crit Care Med* 2004; 169: 459-67.
14. De Jongh, R URutland, J. Ciliary defects in healthy subjects, bronchiectasis, and primary ciliary dyskinesia. *Am J Respir Crit Care Med* 1995; 151: 1559-67.
15. Jorissen, M, Willems, T, Van der Schueren, B, Verbeken, EDe Boeck, K. Ultrastructural expression of primary ciliary dyskinesia after ciliogenesis in culture. *Acta Otorhinolaryngol Belg* 2000; 54: 343-56.
16. Tamalet, A, Clement, A, Roudot-Thoraval, F et al. Abnormal central complex is a marker of severity in the presence of partial ciliary defect. *Pediatrics* 2001; 108: E86.
17. Rossman, C M, Forrest, J B, Lee, R M, Newhouse, A FNewhouse, M T. The dyskinetic cilia syndrome; abnormal ciliary motility in association with abnormal ciliary ultrastructure. *Chest* 1981; 80: 860-5.
18. Pedersen, MMygind, N. Rhinitis, sinusitis and otitis media in Kartagener's syndrome (primary ciliary dyskinesia). *Clin Otolaryngol* 1982; 7: 373-80.
19. Chilvers, M A, Rutman, AO'Callaghan, C. Functional analysis of cilia and ciliated epithelial ultrastructure in healthy children and young adults. *Thorax* 2003; 58: 333-8.
20. Escalier, D, Jouannet, PDavid, G. Abnormalities of the ciliary axonemal complex in children: an ultrastructural cinetic study in a series of 34 cases. *Biol Cell* 1982; 44: 271-82.
21. Chao, J, Turner, J ASturgess, J M. Genetic heterogeneity of dynein-deficiency in cilia from patients with respiratory disease. *Am Rev Respir Dis* 1982; 126: 302-5.

22. Fliegauf, M, Olbrich, H, Horvath, J et al. Mislocalization of DNAH5 and DNAH9 in respiratory cells from patients with primary ciliary dyskinesia. *Am J Respir Crit Care Med* 2005; 171: 1343-9.
23. Porter, M E Sale, W S. The 9 + 2 axoneme anchors multiple inner arm dyneins and a network of kinases and phosphatases that control motility. *J Cell Biol* 2000; 151: F37-42.
24. Greenstone, M, Rutman, A, Pavia, D, Lawrence, D Cole, P J. Normal axonemal structure and function in Kartagener's syndrome: an explicable paradox. *Thorax* 1985; 40: 956-7.
25. Escudier, E, Escalier, D, Homasson, J P, Pinchon, M C Bernaudin, J F. Unexpectedly normal cilia and spermatozoa in an infertile man with Kartagener's syndrome. *Eur J Respir Dis* 1987; 70: 180-6.
26. Schwabe, G C, Hoffmann, K, Loges, N T et al. Primary ciliary dyskinesia associated with normal axoneme ultrastructure is caused by DNAH11 mutations. *Hum Mutat* 2008; 29: 289-298.
27. Narayan, D, Krishnan, S N, Upender, M et al. Unusual inheritance of primary ciliary dyskinesia (Kartagener's syndrome). *J Med Genet* 1994; 31: 493-6.
28. Krawczynski, M R Witt, M. PCD and RP: X-linked inheritance of both disorders? *Pediatr Pulmonol* 2004; 38: 88-9.
29. Moore, A, Escudier, E, Roger, G et al. RPGR is mutated in patients with a complex X linked phenotype combining primary ciliary dyskinesia and retinitis pigmentosa. *J Med Genet* 2006; 43: 326-333.
30. Guichard, C, Harricane, M, Lafitte, J et al. Axonemal dynein intermediate-chain gene (DNAH1) mutations result in situs inversus and primary ciliary dyskinesia (Kartagener syndrome). *Am J Hum Genet* 2001; 68: 1030-1035.

31. Zariwala, M, Noone, P, Sannuti, A et al. Germline mutations in an intermediate chain dynein cause primary ciliary dyskinesia. *Am J Respir Cell Mol Biol* 2001; 25: 577-583.
32. Zariwala, M A, Leigh, M W, Ceppa, F et al. Mutations of DNAI1 in primary ciliary dyskinesia: evidence of founder effect in a common mutation. *Am J Respir Crit Care Med* 2006; 174: 858-66.
33. Omran, H, Haffner, K, Volkel, A et al. Homozygosity mapping of a gene locus for primary ciliary dyskinesia on chromosome 5p and identification of the heavy dynein chain DNAH5 as a candidate gene. *Am J Respir Cell Mol Biol* 2000; 23: 696-702.
34. Olbrich, H, Haffner, K, Kispert, A et al. Mutations in DNAH5 cause primary ciliary dyskinesia and randomization of left-right asymmetry. *Nat Genet* 2002; 30: 143-4.
35. Hornef, N, Olbrich, H, Horvath, J et al. DNAH5 mutations are a common cause of primary ciliary dyskinesia with outer dynein arm defects. *Am J Respir Crit Care Med* 2006; 174: 120-6.
36. Bartoloni, L, Blouin, J L, Pan, Y et al. Mutations in the DNAH11 (axonemal heavy chain dynein type 11) gene cause one form of situs inversus totalis and most likely primary ciliary dyskinesia. *Proc Natl Acad Sci U S A* 2002; 99: 10282-6.
37. Supp, D M, Witte, D P, Potter, S S Brueckner, M. Mutation of an axonemal dynein affects left-right asymmetry in inversus viscerum mice. *Nature* 1997; 389: 963-6.
38. Hong, D H, Pawlyk, B, Sokolov, M et al. RPGR isoforms in photoreceptor connecting cilia and the transitional zone of motile cilia. *Invest Ophthalmol Vis Sci* 2003; 44: 2413-21.
39. Iannaccone, A, Breuer, D K, Wang, X F et al. Clinical and immunohistochemical evidence for an X linked retinitis pigmentosa syndrome with recurrent infections and hearing loss in association with an RPGR mutation 2003; 40: 509-15.

40. Zito, I, Downes, S M, Patel, R J et al. RPGR mutation associated with retinitis pigmentosa, impaired hearing, and sinorespiratory infections. *J Med Genet* 2003; 40: 609-615.
41. Ogawa, K, Takai, H, Ogiwara, A et al. Is outer arm dynein intermediate chain 1 multifunctional? *Mol Biol Cell* 1996; 7: 1895-907.
42. Duriez, B, Duquesnoy, P, Escudier, E et al. A common variant in combination with a nonsense mutation in a member of the thioredoxin family causes primary ciliary dyskinesia. *Proc Natl Acad Sci USA* 2007; 104: 3336-3341.
43. Loges, N T, Olbrich, H, Fenske, L et al. DNAI2 mutations cause primary ciliary dyskinesia with defects in the outer dynein arm. *Am J Hum Genet* (Epub ahead of print) 2008;
44. Pennarun, G, Chapelin, C, Escudier, E et al. The human dynein intermediate chain 2 gene (DNAI2): cloning, mapping, expression pattern, and evaluation as a candidate for primary ciliary dyskinesia. *Hum Genet* 2000; 107: 642-9.
45. Zariwala, M, Knowles, M, Omran, H. Genetic defects in ciliary structure and function. *Annu Rev Physiol* 2007; 69: 423-50.
46. Blouin, J, Meeks, M, Radhakrishna, U et al. Primary ciliary dyskinesia: a genome-wide linkage analysis reveals extensive locus heterogeneity. *Eur J Hum Genet* 2000; 8: 109-118.
47. Meeks, M, Walne, A, Spiden, S et al. A locus for primary ciliary dyskinesia maps to chromosome 19q. *J Med Genet* 2000; 37: 241-4.
48. Jeganathan, D, Chodhari, R, Meeks, M et al. Loci for primary ciliary dyskinesia map to chromosome 16p12.1-12.2 and 15q13.1-15.1 in Faroe Islands and Israeli Druze genetic isolates. *J Med Genet* 2004; 41: 233-40.

49. Geremek, M, Zietkiewicz, E, Diehl, S R, Alizadeh, B Z, Wijmenga, C Witt, M. Linkage analysis localises a Kartagener syndrome gene to a 3.5 cM region on chromosome 15q24-25. *J Med Genet* 2006; 43: e1.

50. Gutierrez-Roelens, I, Sluysmans, T, Jorissen, M, Amyere, M, Viskula, M. Localization of candidate regions for a novel gene for Kartagener syndrome. *Eur J Hum Genet* 2006; 14: 809-15.

51. Geremek, M, Schoenmaker, F, Zietkiewicz, E et al. Sequence analysis of 21 genes located in the Kartagener syndrome linkage region on chromosome 15q. *Eur J Hum Genet* 2008; 16: 688-95.

Table 1: Clinical and ultrastructural phenotype according to the genes involved in PCD

Genes	Extra-respiratory phenotypic features	Ultrastructural defect	References
<i>DNAI1</i>	\pm <i>situs inversus</i>	lack of ODA	3, 30-32
<i>DNAH5</i>	\pm <i>situs inversus</i>	lack of ODA	34, 35
<i>DNAH11</i>	\pm <i>situs inversus</i>	normal axoneme	36, 26
<i>RPGR</i>	retinitis pigmentosa	complex dynein arm defect	29
<i>TXNDC3</i>	<i>situs ambiguous</i>	partial lack of ODA	42
<i>DNAI2</i>	\pm <i>situs inversus</i>	lack of ODA	43

Figure 1: Schematic representation of a transversal section of the axoneme of motile cilia

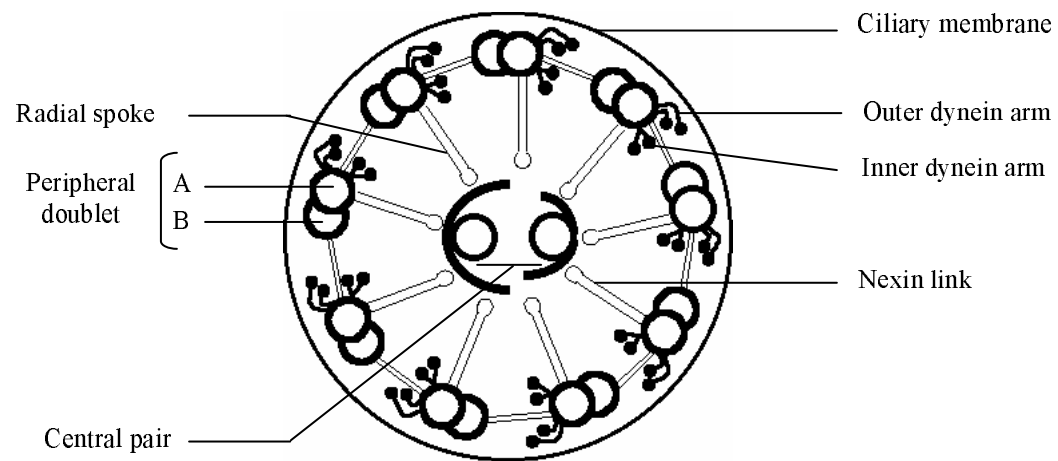


Figure 2: Normal axonemal ultrastructure of respiratory cilia and main defects found in patients with PCD

- A. Cross section of a normal cilium showing the “9+2” microtubule doublet configuration with presence of both dynein arms, as shown by TEM (bar=0.1 μ m)
- B. Absence of outer dynein arms
- C. Absence of both dynein arms
- D. Absence of inner dynein arms combined with axonemal disorganization
- E. Absence of central complex

