



HAL
open science

MEF2C haploinsufficiency caused by either microdeletion of the 5q14.3 region or mutation is responsible for severe mental retardation with stereotypic movements, epilepsy and/or cerebral malformations.

Nathalie Le Meur, Muriel Holder-Espinasse, Sylvie Jaillard, Alice Goldenberg, Sylvie Joriot, Patrizia Amati-Bonneau, Agnès Guichet, Magalie Barth, Aude Charollais, Hubert Journal, et al.

► **To cite this version:**

Nathalie Le Meur, Muriel Holder-Espinasse, Sylvie Jaillard, Alice Goldenberg, Sylvie Joriot, et al.. MEF2C haploinsufficiency caused by either microdeletion of the 5q14.3 region or mutation is responsible for severe mental retardation with stereotypic movements, epilepsy and/or cerebral malformations.: MEF2C haploinsufficiency. Journal of Medical Genetics, 2010, 47 (1), pp.22-9. 10.1136/jmg.2009.069732 . inserm-00406331

HAL Id: inserm-00406331

<https://inserm.hal.science/inserm-00406331>

Submitted on 24 Aug 2009

HAL is a multi-disciplinary open access archive for the deposit and dissemination of scientific research documents, whether they are published or not. The documents may come from teaching and research institutions in France or abroad, or from public or private research centers.

L'archive ouverte pluridisciplinaire **HAL**, est destinée au dépôt et à la diffusion de documents scientifiques de niveau recherche, publiés ou non, émanant des établissements d'enseignement et de recherche français ou étrangers, des laboratoires publics ou privés.

MEF2C haploinsufficiency caused by either microdeletion of the 5q14.3 region or mutation is responsible for severe mental retardation with stereotypic movements, epilepsy and/or cerebral malformations

Nathalie Le Meur ^{2 1 *}, Muriel Holder-Espinasse ³, Sylvie Jaillard ^{5 4}, Alice Goldenberg ¹, Sylvie Joriot ⁶, Patrizia Amati-Bonneau ^{7 8}, Agnès Guichet ⁸, Magalie Barth ⁸, Aude Charollais ⁹, Hubert Journal ¹⁰, Stéphane Auvin ¹¹, Cécile Boucher ¹, Jean-Pierre Kerckaert ¹², Véronique David ^{4 13}, Sylvie Manouvrier-Hanu ³, Pascale Saugier-Weber ^{14 1}, Thierry Frébourg ^{1 14}, Christèle Dubourg ^{13 4}, Joris Andrieux ¹⁵, Dominique Bonneau ^{7 8}

¹ Service de Génétique CHU Rouen , FR

² Laboratoire de Cytogénétique EFS Normandie , Bois-Guillaume,FR

³ Service de Génétique clinique CHU Lille , Hôpital Jeanne de Flandre , 2 avenue Oscar Lambret, 59000 Lille,FR

⁴ IGDR, Institut de Génétique et Développement de Rennes CNRS : UMR6061 , Université de Rennes I , IFR140 , Faculté de Médecine - CS 34317 2 Av du Professeur Léon Bernard 35043 RENNES CEDEX,FR

⁵ Laboratoire de cytogénétique et biologie cellulaire CHU Rennes , Hôpital Pontchaillou , FR

⁶ Service de Neuropédiatrie CHU Lille , Hôpital Roger Salengro , Lille,FR

⁷ Mitochondrie : Régulations et Pathologie INSERM : U694 , Université d'Angers , CHU 4, Rue Larrey 49033 Angers Cedex,FR

⁸ Service de génétique CHU Angers , Angers,FR

⁹ Service de Médecine Néonatale CHU Rouen , FR

¹⁰ Génétique Médicale Centre Hospitalier Bretagne Atlantique , Hôpital Chubert , Vannes,FR

¹¹ Service de Neurologie Pédiatrique AP-HP , Hôpital Robert Debré , Université Paris-Diderot - Paris VII , FR

¹² Plateforme de Génomique Fonctionnelle Université du Droit et de la Santé - Lille II , FR

¹³ Laboratoire de génétique moléculaire et hormonologie CHU Rennes , Hôpital Pontchaillou , 2 rue Henri Le Guilloux 35033 Rennes Cedex 9,FR

¹⁴ Génétique médicale et fonctionnelle du cancer et des maladies neuropsychiatriques INSERM : U614 , Université de Rouen , UFR de Médecine et de Pharmacie 22, Boulevard Gambetta 76183 ROUEN CEDEX,FR

¹⁵ Laboratoire de Génétique Médicale CHU Lille , Hôpital Jeanne de Flandre , 59037 Lille Cedex,FR

* Correspondence should be addressed to: Nathalie Le Meur <nathalie.lemeur@efs.sante.fr >

Abstract

Over the last few years, array-CGH has remarkably improved the ability to detect cryptic unbalanced rearrangements in patients presenting with syndromic mental retardation. Using whole genome oligonucleotide array-CGH, we detected 5q14.3 microdeletions ranging from 216 kb to 8.8 Mb in 5 unrelated patients showing phenotypic similarities, namely severe mental retardation with absent speech, hypotonia and stereotypic movements. Most of the patients presented also with facial dysmorphic features, epilepsy and/or cerebral malformations. The minimal common deleted region of these 5q14 microdeletions encompassed only MEF2C, known to act in brain as a neurogenesis effector which regulates excitatory synapse number. In a patient presenting a similar phenotype, we subsequently identified a MEF2C nonsense mutation. Taken together, these results strongly suggest that haploinsufficiency of MEF2C is responsible for severe mental retardation with stereotypic movements, seizures and/or cerebral malformations.

MESH Keywords Cerebrum ; abnormalities ; metabolism ; Child ; Child, Preschool ; Chromosome Deletion ; Chromosomes, Human, Pair 5 ; genetics ; Epilepsy ; genetics ; Haploidy ; Humans ; Infant ; MADS Domain Proteins ; genetics ; Mental Retardation ; genetics ; Myogenic Regulatory Factors ; genetics ; Stereotypic Movement Disorder ; genetics

Author Keywords 5q14.3 microdeletion ; mental retardation ; array-CGH ; MEF2C ; seizures

INTRODUCTION

The clinical implementation of whole genome array comparative genomic hybridization (array-CGH) has revolutionised the diagnosis of patients with mental retardation, congenital anomalies or neuropsychiatric disorders. With high-density microarrays, presence of chromosome imbalances is detected in up to 17% of idiopathic developmental delay-mental retardation.¹ On the basis of array-CGH data, new microdeletion and microduplication syndromes have been described such as the 17q21.31 microdeletion involving the MAPT gene and resulting in syndromic mental retardation with typical facial features,² the 15q13.3 microdeletion associated with mental retardation and seizures³ and the 1q21.1 microdeletion, between BP2-BP3 regions, involving the PIAS3 gene in TAR syndrome.⁴ Array-CGH also

lead to the identification of several genes involved in monogenic disorders, such as CHD7 in CHARGE and TCF4 in Pitt-Hopkins syndrome.^{5–7}

Recently, Cardoso et al⁸ reported 3 cases of 5q14.3-q15 deletions presenting with severe mental retardation, hypotonia, seizures, minor dysmorphic features and periventricular heterotopia and an additional case has been reported in the Decipher database (<https://decipher.sanger.ac.uk/application/>). Here, we report the detection of five distinct 5q14 deletions in 5 unrelated patients presenting with severe mental retardation, absent speech and stereotypic movements and one duplication of the 5q14 region in a patient with mental retardation. These deletions, which are different to those reported by Cardoso et al⁸, allowed us to define a minimal critical region encompassing only the MEF2C gene and led us to sequence this gene in patients with similar phenotypes. We provide arguments indicating that this severe mental retardation results from MEF2C haploinsufficiency.

PATIENTS AND METHODS

Patients

All 7 patients included in this study have been examined by a clinical geneticist in the context of etiologic investigations in children affected with developmental delay. Array-CGH analysis was performed since mental retardation was associated with at least two of the following criteria, i.e. dysmorphic facial features, family history of mental retardation, growth anomaly or congenital malformation. For the 7 patients, high resolution chromosome analysis and extensive biochemical metabolic screening (lactic acid, pyruvic acid, ammoniac, plasmatic amino acids and urine organic acids analyses, purine metabolism, blood and urinary creatine and guanido-acetic acid) were normal. For each patient, blood samples for genetic analyses were collected after having obtained written informed consent of the parents. Clinical presentations of the patients are summarized in Table 1.

Case 1

BV is the third child of healthy unrelated parents. She was born at 36 week's gestation (WG) with normal growth parameters. At 3 days of age, she experienced a single episode of cyanosis with eye revulsion. Frequent crying, sleep disturbance, hypotonia and poor visual contact were noted at 3 months. From the age of 4 months, myoclonic jerks of the upper limbs were noted and followed, several weeks later, by brief episodes of eye revulsion concomitant with the jerks. Epilepsy was diagnosed at the age of 7 months and characterized by the association of several bilateral isolated spasms and frequent synchronous myoclonus with abnormal and slow background EEG pattern. Clinical examination at 4 years 9 months showed normal growth and head circumference. Developmental delay was severe. She sat unaided and was able to crawl manipulate toys. Eye contact was present though transient. Speech was absent. She had stereotypic repetitive movements, rocking her head and rubbing her chin with her hands. Subtelomeric rearrangements were excluded by QMPSF (Quantitative Multiplex PCR of Short Fluorescent Fragments). Analysis of the CDKL5 gene revealed no alteration.

Case 2

CA is the second child of healthy unrelated parents. At birth, at 40 WG, weight and length were normal but head circumference was along the -3 standard deviation (SD). Since the first day of life, she developed tonico-clonic seizures. EEG revealed frequent bursts with no basic rhythm and a very unstructured pattern. At 9 months of age, severe hypotonia and poor eye contact were noted. Awakening stages were short. Despite treatment, the seizures occurred every day.

Case 3

ED is the second child of healthy unrelated parents. Delivery was provoked at 41 WG because of abnormal foetal cardiac rhythm. At birth, weight and length were on +3 SD but head circumference was small (-2.5 SD). At the age of 2 months, severe hypotonia and absent eye contact were noted. Cortical blindness was subsequently diagnosed. EEG showed a slow basic rhythm with infraclinical temporoparietal paroxystic discharges. At 18 months of age, weight gain was insufficient (-2 SD) leading to a gastrostomy tube placement. He presented severe hypotonia, transient eye contact and sleep disturbance.

Case 4

WD is the second child of healthy unrelated parents. Delivery occurred at 38 WG and birth growth parameters were within the normal range. Failure to thrive and severe hypotonia were observed and led to several neurological investigations at the age of 4 months. Eye contact was difficult to obtain during the first year of life. He never experienced seizures. EEG was normal. He sat unaided at age 18 months and crawled at age 2 years. When referred to the genetic clinic at 3 years of age, he was able to stand, cruise along the furniture and manipulate toys. Speech was absent. Eye contact was transient. He presented with repetitive hand flapping and clapping movements. Diagnosis of Angelman syndrome was considered to be unlikely on the basis of a normal SNRPN methylation pattern.

Case 5

LD is the second child of healthy parents who were first cousins. She was born at 40WG, with growth parameters below $-2SD$. Hypotonia and developmental delay were observed during the first months of life. At 3 years of age, she experienced tonico-clonic febrile seizures which were well controlled by valproate. At 7 years, she was unable to walk and had not acquired any language skill. She had repetitive hand washing and hand-to-mouth movements as well as frequent bouts of hyperventilation. Subtelomeric rearrangements were excluded by FISH. Screening of the MECP2 gene revealed no deleterious mutation.

Case 6

TM is the third child of healthy unrelated parents. Growth parameters at birth on term were in the normal range. He was first referred at the age of 2 years 6 months for a mild global developmental delay. He was able to walk unaided since the age of 2 years. Cerebral MRI and EEG were normal. Clinical examination at 6 years of age revealed a microcephaly ($-3 SD$) with normal height and weight. He presented mental retardation: IQ was evaluated between 50 and 60 (WISC IV). Speech was severely delayed but understandable; he was not able to pronounce short sentences. Eye contact, behaviour, and social skills were normal. Special education was required. Subtelomeric rearrangements and the most frequent microdeletion syndromes were excluded using the MLPA (Multiplex Ligation-dependent Probe Amplification) method.

Case 7

DG is the first girl born to healthy non-consanguineous parents with an unremarkable family history. She was born on term after an uneventful pregnancy. At birth, growth parameters were normal. The neonatal period was normal apart from difficulties in breastfeeding. She appeared to develop normally until the age of 5 months. From the age of 5 months, she started to regress and to lose previously acquired skills. She was unable to use her hands purposefully and failed to acquire vocalization with intonation. She walked unaided at age 3 years. She presented behavioral disorders, including decreased eye contact, lack of emotional reciprocity, lack of interest in her surroundings and hand and hand-mouth stereotypic movements. She also had severe feeding difficulties that started at age 5 months and were still present at 7 years of age. Generalized tonico-clonic seizures, well controlled on sodium valproate, started at age 9 months. At 7 years of age, she was severely mentally impaired and presented with poor eye contact and no speech. Neurological examination showed an unstable, wide-based gait, without any objective cerebellar signs. Sequencing of the MECP2 and CDKL5 genes revealed no mutation.

Standard and molecular karyotyping

Karyotyping of RHG-banded chromosomes from lymphocytes at 550-band resolution was performed according to standard procedures. High molecular weight genomic DNA was extracted from patient's peripheral blood lymphocytes using the QIAamp DNA Blood Midi kit (Qiagen, Valencia, CA, USA) according to the manufacturer's instructions. DNA concentration was determined with NanoDrop ND-1000 spectrophotometer and software (NanoDrop Technologies, Berlin, Germany). Detection of gene copy number was performed by array-CGH following standard and manufacturer's recommendations (Agilent, Agilent Technologies, Santa Clara, CA, USA) using 44 000 oligo probes approximately spaced at 35–40 kb intervals across the genome (Human Genome CGH microarray 44B kit, Agilent) or 244 000 oligo probes approximately spaced at 10 kb intervals across the genome (Human Genome CGH microarray 244B kit, Agilent). Commercial (Promega, Madison, WI, USA) or non commercial female and male genomic DNA were used as references. Hybridization results were extracted with Feature extraction software and analyzed with the DNA-analytics software by applying a Z-score or ADM 2 segmentation algorithm to identify chromosome aberrations. Copy-number gains and losses were determined by threshold of 0.3 and -0.3 , respectively. Aberrant signals obtained with three or more neighbouring oligonucleotides were considered indicative of genomic aberrations and further evaluated by FISH, MP-LC, qPCR and/or QMPSF, unless they coincided with a published DNA copy-number variant, as listed in the Database of Genomic Variants (<http://projects.tcag.ca/variation/?source=hg18>, version June 2008).

FISH analysis

Aberrations were validated by Fluorescence in situ hybridization (FISH) experiments (see supplementary data). FISH was performed with RP11-1006G2 (case 1), with RP11-1147F22 (case 2 and case 3), with CTD-2328P23, RP11-1147F22 and RP11-110I3 (case 5) and with CTD-2328P23 (case 6).

QMPSF (Quantitative Multiplex PCR of Short Fluorescent Fragments)

MEF2C exon 2 was PCR-amplified using the dye-labeled primers MEF2C-F (5'-CGTTAGATAGTGGGAAGTGGGAACTGAGCTGTGCAAGT-3') and MEF2C-R (5'-GATAGGGTTACGTTTCATCCATAATCCTCGTAATC-3'). Exon 13 of HMBS located on chromosome 11 and exon 4 of MECP2 located on chromosome Xq28, were co-amplified as controls, using the dye-labeled primers HMBS-F (5'-CGTTAGATAGACGGCTCAGATAGCATACAAG-3'); and HMBS-R (5'-GATAGGGTTAATGCCTACCAACTGTGGGTCA-3'); MECP2-F (5'-CGTTAGATAGTTTCGCTCTAAAGTGGAGTTGAT-3') and MECP2-R (5'-GATAGGGTTAGGGCTTCTTAGGTGGTTTCTG-3'), respectively. Detailed description of the QMPSF analyses is available in supplementary data.

Multiplex PCR/Liquid Chromatography (MP-LC)

MEF2C intron 2 was PCR-amplified using the following primers: MEF2C-MPLC-F (5'-TAATCCAGGAGCCACAGGTC-3') and MEF2C-MPLC-R (5'-GAGAAAGAGCATTTAGGAGGG-3'). An additional fragment, corresponding to the HMBS gene located on chromosome 11, was co-amplified as control (primers are available on request). Detailed description of the MP-LC analyses is available in supplementary data.

Quantitative PCR

Quantitative PCR (qPCR) of MEF2C was performed using SYBR green (see supplementary data). The RPPH1 gene, was used for normalisation. MEF2C exon 1 was amplified with the primer MEF2C-E1-F (5'-TGTCAGGGTTTGGACAACAA-3') and MEF2C-E1-R (5'-TGGCAATTGAAACTCACCA-3') and MEF2C exon 2 was amplified with MEF2C-E2-F (5'-CACATTTGAAGGTGCCAAAG-3') and MEF2C-E2-R (5'-CAATCATTTCCTCCGTTTC-3').

Sequencing analysis of the MEF2C gene

The 10 coding exons of the MEF2C gene, including the exon-intron junctions, were PCR-amplified (primers are available on request) from 100 ng of genomic DNA in 50 µl containing 1.5 mM MgCb, 75 mM Tris-HCl (pH 9 at 25°C), 20 mM (NH₄)₂SO₄, 0.01% Tween 20, 50 pmol of each primer, 200 µM of each dNTP and 2 units of Hot GoldStar (Eurogentec, Seraing, Belgium). PCR conditions include one cycle for 4 min at 94°C followed by 30 cycles at 94°C for 30 s, 58°C for 30 s, 72°C for 1 min, and one last cycle at 72°C for 5 min. The purified PCR products were then sequenced using a Ceq2000/8000 DNA sequencer (CEQ DTCS-Quick Start Kit, Beckman Coulter, Fullerton, CA, USA).

RESULTS

In the course of systematic molecular karyotyping of patients with syndromic mental retardation, we identified five 5q14 deletions and one 5q14 duplication. All patients with 5q14 deletion (cases 1 to 5, Table 1) presented with early and severe developmental delay and hypotonia. Speech was absent in all cases. None of the children was able to walk unaided. Stereotypic movements were present in 3/5 patients and absent in the two youngest children. Different types of epilepsy were observed in 3/5 of our patients, from well controlled generalized seizures to early refractory tonicoclonic or myoclonic epilepsy. Miscellaneous dysmorphic facial features were present in all cases (fig. 1), but some common features were noticed i.e. high and wide forehead, pronounced eyebrows, anteverted nostrils, short and prominent philtrum, down turned corners of the mouth and small chin. In 3/5 cases, palpebral fissures were up-slanted.

All patients with 5q14 deletion displayed MRI abnormalities (table 1), including either corpus callosum agenesis (2/5) or increased corpus callosum thickness and shortness (1/5), abnormal gyration (1/5), fronto-parietal atrophy and enlarged pericerebral spaces (1/5), enlarged lateral ventricle (2/5) or enlarged fourth ventricle (2/5). As shown in figures 2 and 3 , the 5q14 deletions measured approximately 2.68 Mb (case 1), 3.5 Mb (case 2), 8.8 Mb (case 3), 1.57 Mb (case 4) and 216 Kb (case 5). In case 6, we detected a 5q14 duplication which size was estimated to 4.6 Mb. These 5q14 rearrangements were all confirmed by a second independent method, i.e. QMPSF (case 1), MP-LC (case 5 and 6), qPCR (case 4) and/or FISH analysis (case 1, 2, 3, 5 and 6) and segregation analyses revealed that they all had occurred de novo (fig. 4). The smallest rearrangement detected in case 5, presenting a Rett-like phenotype with developmental delay, poor eye contact, epilepsy, stereotypic hand-mouth movements, episodes of hyperventilation and apnea, corresponded to a 216 Kb deletion which encompassed a single gene, MEF2C, restricting therefore the minimal common deleted region to this gene.

In cases 1, 2, 3 and 5, the deletion removed entirely the MEF2C gene. In case 4, q-PCR showed a partial deletion of MEF2C removing the first exon, the breakpoint being located within intron 1. These observations led us to perform sequencing analysis of the MEF2C gene in 5 additional patients affected with severe mental retardation, in whom the diagnosis of the Rett phenotype had been suggested and for whom the array CGH array was normal. As shown in fig. 4C , in one patient (case 7), we identified a point mutation within exon 7 (NM_002397.2:c.683C>G) predicted to result in a premature stop codon (p.Ser228X). Sequencing analysis performed in the parents revealed that the mutation had occurred de novo.

DISCUSSION

We here report on five 5q14 submicroscopic deletions, one 5q14 duplication and one nonsense MEF2C mutation in 7 unrelated children, all presenting with mental retardation.

The clinical significance of the 5q14.3 duplication remains uncertain and, despite its de novo occurrence, it may represent a benign variant. Such non-pathogenic duplications have been described, contrasting with the deleterious deletion mirror event.⁸ Alternatively, the 5q14.3 duplication may be responsible for a mild phenotype distinct from that resulting from the deletions. Indeed, 7q11.23, 16p 13.11 and 17p11.2 duplications result into relatively mild phenotype compared to deletions.^{9–11} Study of additional patients will be required to determine the pathogenic effect of the 5q14.3 duplication.

In the five cases with 5q14.3 microdeletion, the developmental delay was severe, associating hypotonia, poor eye contact and stereotypic hand movements (3/5). Moreover, in cases 4 and 5, classical Rett syndrome had initially been suspected because of repetitive clapping hand-mouth movements. However, these two latter patients did not display any period of normal development or a progressive loss of motor or communicative skills. Epilepsy was present in 3 cases. In one case, refractory myoclonic epilepsy with atypical spasms beginning before 6 months of age, led us to consider initially the hypothesis of an early-onset seizures variant of Rett syndrome due to CDKL5 mutation. Nevertheless, the presence of dysmorphic facial features in all five cases was strongly suggestive of a chromosomal aberration.

Only few interstitial 5q14 deletions detected by standard chromosomal analysis had previously been reported^{12–18} and were shown to be associated with severe to moderate mental retardation, growth retardation, deep hypotonia, facial dysmorphism and malformations. The facial features included prominent forehead, epicanthal folds, brachycephaly, hypertelorism, flat nasal bridge, anteverted nostrils, abnormal ears and short neck. Malformations were miscellaneous and included renal abnormalities, cleft palate, club feet, heart defect, and dislocated hips. Among these cases, a clinical phenotype could hardly be delineated and epilepsy had not previously been reported. Boundaries of the deletions in the different published cases are hardly comparable because of the low resolution level of chromosome analyses.

The three 5q14.3-q15 deletion cases, recently reported by Cardoso et al ⁸, and an additional case reported in the Decipher database partially overlap with the 5q14.3 deletions that we report here. The critical regions, defined by the latter cases, are different. The common clinical features presented both by these 4 previously described patients and the 5 cases described here include mental retardation, seizures and dysmorphic facial features. Nevertheless, in contrast to the patients described by Cardoso et al ⁸, none of our cases presented periventricular heterotopia. However, in our patients, a developmental defect of the neuronal migration with ectopic neurons cannot not be formally excluded as a cause of the severe and early epilepsy associated with mental retardation.

In our patients, the 5q14 deletion sizes ranged from 216 Kb to 8.8 Mb. The absence of low copy repeat (LCR) sequences flanking the breakpoints as well as the absence of recurrent breakpoints suggested that these rearrangements did not result from non-allelic homologous recombination and involve another mechanism such as non homologous end joining of DNA breaks. The detection of a 216 Kb deletion, removing only the MEF2C gene, is a first argument supporting that haploinsufficiency of this gene contributes to the 5q14 microdeletion syndrome. MEF2C deletion is not a common CNV (<http://projects.tcag.ca/variation/?source=hg18>) and the de novo origin of the 5 deletions reported in this study is in agreement with their causal role in the patient phenotypes. Although we cannot formally exclude that haploinsufficiency of other 5q14 genes contribute to the phenotype of patients harbouring larger deletions, the fact that the 5 patients reported in this study and presenting different deletion sizes showed striking phenotypic similarities (Table 1) strongly suggests that the phenotype is mainly due to MEF2C deletion. Finally, the identification of an inactivation point mutation within MEF2C gene in case 7 constitutes a key argument demonstrating that haploinsufficiency of this gene results in mental retardation. The causal role of MEF2C alteration in the phenotype observed is in agreement with the biological function of the MEF2C protein and the murine models of MEF2C inactivation. Indeed, Myocyte Enhancer Factor 2 (MEF2) transcription factors act, in the brain, as effectors of neurogenesis which regulate excitatory synapse number,¹⁹ dendrite morphogenesis and differentiation of post synaptic structures²⁰. The role of MEF2 proteins in synaptic plasticity is consistent with a role in learning and memory. MEF2C is the predominant isoform in the developing cerebroticortex and is highly expressed in frontal cortex, entorhinal cortex, cerebellum, dentate gyrus and amygdala.^{21–22} Conditional *Mef2c*-null mice were generated as the knockout of the *Mef2c* gene is embryonic lethal.^{23,24} Late embryonic deletion of *Mef2c* in the forebrain causes hippocampus-dependent learning and memory impairment associated to a dramatic increase in the number of excitatory synapses.²⁴ The role of *Mef2c* in synaptic plasticity in mice, limiting the excessive increase in the number of excitatory, is consistent with its possible implication in seizures in human. In mutant mice with earlier embryonic deletion, abnormal aggregation and compaction of neurons migrating into the lower layers of the neocortex during development were observed.²³ As a consequence, the cortical plate in postnatal/adult neocortex in these conditional *Mef2c*-null mice displays disorganization and the neurons exhibit immature electrophysiological properties characteristic of an immature neuronal network. These murine phenotypes provide convincing arguments for the implication of MEF2C haploinsufficiency as the cause of mental retardation observed in all cases and epilepsy in 4 of our cases. Furthermore, the role of MEF2C in neuronal migration is of particular interest regarding to the periventricular heterotopia described by Cardoso et al ⁸. Although MEF2C was deleted in only one of their three cases, a position effect on MEF2C of the two other deletions cannot be excluded. This hypothesis is emphasized by the report, in a patient sharing a striking similar phenotype, of a de novo balanced translocation between chromosomes 5 and 8, the breakpoint being located just nearby the MEF2C gene²⁵. Moreover, *Mef2c*-null mice display behavioural phenotypes with abnormal anxiety, decreased cognitive function, and marked paw wringing/clasping stereotypy, resulting in a Rett-like phenotype as observed in mutant *Mecp2* mouse models.^{23,24} Additionally, according to the Transfac Matrix Database, the *Mecp2* gene contains multiple putative MEF2 binding sites. Another gene, DIA1 (deleted in autism-1 or C3orf58), containing putative MEF2 binding sites, has recently been implicated in autism and epilepsy.²⁷ Indeed, a homozygous deletion of DIA1 was found in a case presenting with striking resemblances with MEF2C deleted patients, i.e. early seizures, poor eye contact, absent speech and stereotypic movements. Additional findings are needed to assess the role of MEF2C, DIA1 and MECP2 in a common biological pathway essential for a normal neurological development.

In conclusion, our results indicate that MEF2C haploinsufficiency caused either by 5q14.3 microdeletion or by mutation is responsible for a severe mental retardation with stereotypic movements, epilepsy and/or cerebral malformations.

Acknowledgements:

We are grateful to the patients and their families who participated to this study.

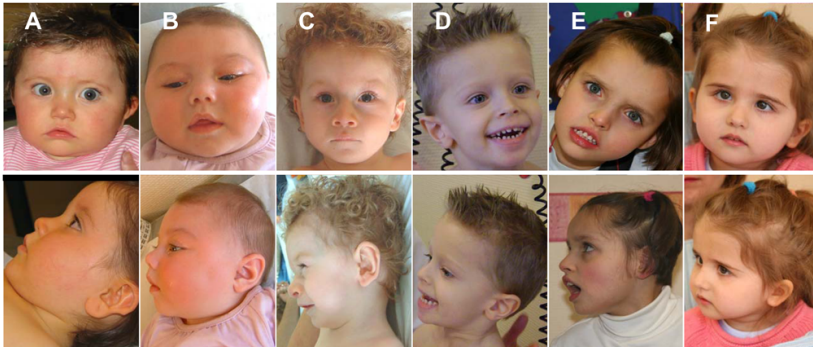
References:

1. Stankiewicz P, Beaudet AL. Use of array CGH in the evaluation of dysmorphology, malformations, developmental delay, and idiopathic mental retardation. *Curr Opin Genet Dev*. 2007; 17: 182 - 192
2. Koolen DA, Vissers LE, Pfundt R, de Leeuw N, Knight SJ, Regan R, Kooy RF, Reyniers E, Romano C, Fichera M, Schinzel A, Baumer A, Anderlid BM, Schoumans J, Knoers NV, van Kessel AG, Sijdermans EA, Veltman JA, Brunner HG, de Vries BB. A new chromosome 17q21.31 microdeletion syndrome associated with a common inversion polymorphism. *Nat Genet*. 2006; 38: 999 - 1001
3. Sharp AJ, Mefford HC, Li K, Baker C, Skinner C, Stevenson RE, Schroer RJ, Novara F, De Gregori M, Ciccone R, Broomer A, Casuga I, Wang Y, Xiao C, Barbacioru C, Gimelli G, Bernardina BD, Torniero C, Giorda R, Regan R, Murday V, Mansour S, Fichera M, Castiglia L, Failla P, Ventura M, Jiang Z, Cooper GM, Knight SJ, Romano C, Zuffardi O, Chen C, Schwartz CE, Eichler EE. A recurrent 15q13.3 microdeletion syndrome associated with mental retardation and seizures. *Nat Genet*. 2008; 40: 322 - 328
4. Klopocki E, Schulze H, Strauss G, Ott CE, Hall J, Trotier F, Fleischhauer S, Greenhalgh L, Newbury-Ecob RA, Neumann LM, Habenicht R, König R, Seemanova E, Megarbane A, Ropers HH, Ullmann R, Horn D, Mundlos S. Complex inheritance pattern resembling autosomal recessive inheritance involving a microdeletion in thrombocytopenia-absent radius syndrome. *Am J Hum Genet*. 2007; 80: 232 - 240
5. Vissers LE, van Ravenswaaij CM, Admiraal R, Hurst JA, de Vries BB, Janssen IM, van der Vliet WA, Huys EH, de Jong PJ, Hamel BC, Schoenmakers EF, Brunner HG, Veltman JA, van Kessel AG. Mutations in a new member of the chromodomain gene family cause CHARGE syndrome. *Nat Genet*. 2004; 36: 955 - 957
6. Zweier C, Peippo MM, Hoyer J, Sousa S, Bottani A, Clayton-Smith J, Reardon W, Saraiva J, Cabral A, Gohring I, Devriendt K, de Ravel T, Bijlsma EK, Hennekam RC, Orrico A, Cohen M, Dreweke A, Reis A, Nurnberg P, Rauch A. Haploinsufficiency of TCF4 causes syndromal mental retardation with intermittent hyperventilation (Pitt-Hopkins syndrome). *Am J Hum Genet*. 2007; 80: 994 - 1001
7. Andrieux J, Lepretre F, Cuisset JM, Goldenberg A, Delobel B, Manouvrier-Hanu S, Holder-Espinasse M. Deletion 18q21.2q21.32 involving TCF4 in a boy diagnosed by CGH-array. *Eur J Med Genet*. 2008; 51: 172 - 177
8. Cardoso C, Boys A, Parrini E, Mignon-Ravix C, McMahon JM, Khantane S, Bertini E, Pallesi E, Missirian C, Zuffardi O, Novara F, Villard L, Giglio S, Chabrol B, Slater HR, Moncla A, Scheffer IE, Guerrini R. Periventricular heterotopia, mental retardation, and epilepsy associated with 5q14.3-q15 deletion. *Neurology*. 2009; 72: 784 - 792
9. Hannes FD, Sharp AJ, Mefford HC, de Ravel T, Ruivenkamp CA, Breuning MH, Fryns JP, Devriendt K, Van Buggenhout G, Vogels A, Stewart HH, Hennekam RC, Cooper GM, Regan R, Knight SJ, Eichler EE, Vermeesch JR. Recurrent reciprocal deletions and duplications of 16p13.11: The deletion is a risk factor for MR/MCA while the duplication may be a rare benign variant. *J Med Genet*. 2009; 46: 223 - 232
10. Somerville MJ, Mervis CB, Young EJ, Seo EJ, del Campo M, Bamforth S, Peregrine E, Loo W, Lillie M, Pérez-Jurado LA, Morris CA, Scherer SW, Osborne LR. Severe expressive-language delay related to duplication of the Williams-Beuren locus. *N Engl J Med*. 2005; 353: 1694 - 1701
11. Potocki L, Bi W, Treadwell-Deering D, Carvalho CM, Eifert A, Friedman EM, Glaze D, Krull K, Lee JA, Lewis RA, Mendoza-Londono R, Robbins-Furman P, Shaw C, Shi X, Weissenberger G, Withers M, Yatsenko SA, Zackai EH, Stankiewicz P, Lupski JR. Characterization of Potocki-Lupski syndrome (dup(17)(p11.2p11.2)) and delineation of a dosage-sensitive critical interval that can convey an autism phenotype. *Am J Hum Genet*. 2007; 80: 633 - 649
12. Stoll C, Levy J, Roth MP. Interstitial deletion of the long arm of chromosome 5 in a deformed boy: 46,XY,del(5)(q13q15). *J Med Genet*. 1980; 17: 486 - 487
13. Silengo MC, Luzzatti L, Centerwall WR, Costello JM, Parlow M. Interstitial deletion of the long arm of chromosome no. 5 in two unrelated children with congenital anomalies and mental retardation. *Clin Genet*. 1981; 19: 174 - 180
14. Ohdo S, Madokoro H, Hayakawa K. Interstitial deletion of the long arm of chromosome 5: 46,XX,del(5)(q13q22). *J Med Genet*. 1982; 19: 479 -
15. Rodewald A, Zankl M, Sitzmann FC, Zang KD. Interstitial de novo deletion of the long arm of chromosome 5: mapping of 5q bands associated with particular malformations. *Clin Genet*. 1982; 22: 226 - 230
16. Harprecht-Beato W, Kaiser P, Steuber E, Reinhard W. Interstitial deletion in the long arm of chromosome No. 5. *Clin Genet*. 1983; 23: 167 - 171
17. Krishna J, Myers TL, Bourgeois MJ, Tonk V. Interstitial deletion of long arm of chromosome no. 5 with growth hormone deficiency--an emerging syndrome?. *Clin Genet*. 1997; 51: 48 - 51
18. Malan V, Martinovic J, Sanlaville D, Caillat S, Waill MC, Ganne ML, Tantau J, Attie-Bitach T, Vekemans M, Morichon-Delvallez N. Molecular characterisation of a prenatally diagnosed 5q15q21.3 deletion and review of the literature. *Prenat Diagn*. 2006; 26: 231 - 238
19. Flavell SW, Cowan CW, Kim TK, Greer PL, Lin Y, Paradis S, Griffith EC, Hu LS, Chen C, Greenberg ME. Activity-dependent regulation of MEF2 transcription factors suppresses excitatory synapse number. *Science*. 2006; 311: 1008 - 1012
20. Shalizi A, Gaudillière B, Yuan Z, Stegmüller J, Shirogane T, Ge Q, Tan Y, Schulman B, Harper JW, Bonni A. A calcium-regulated MEF2 sumoylation switch controls postsynaptic differentiation. *Science*. 2006; 311: 1012 - 1017
21. Leifer D, Golden J, Kowall NW. Myocyte-specific enhancer binding factor 2C expression in human brain development. *Neuroscience*. 1994; 63: 1067 - 1079
22. Lyons GE, Micales BK, Schwarz J, Martin JF, Olson EN. Expression of mef2 genes in the mouse central nervous system suggests a role in neuronal maturation. *J Neurosci*. 1995; 15: 5727 - 5738
23. Li H, Radford JC, Ragusa MJ, Shea KL, McKercher SR, Zaremba JD, Soussou W, Nie Z, Kang YJ, Nakanishi N, Okamoto S, Roberts AJ, Schwarz JJ, Lipton SA. Transcription factor MEF2C influences neural stem/progenitor cell differentiation and maturation in vivo. *Proc Natl Acad Sci U S A*. 2008; 105: 9397 - 9402
24. Barbosa AC, Kim MS, Ertunc M, Adachi M, Nelson ED, McAnally J, Richardson JA, Kavalali ET, Monteggia LM, Bassel-Duby R, Olson EN. MEF2C, a transcription factor that facilitates learning and memory by negative regulation of synapse numbers and function. *Proc Natl Acad Sci U S A*. 2008; 105: 9391 - 9396
25. Floris C, Rassu S, Boccone L, Gasperini D, Cao A, Crisponi L. Two patients with balanced translocations and autistic disorder: CSMD3 as a candidate gene for autism found in their common 8q23 breakpoint area. *Eur J Hum Genet*. 2008; 16: 696 - 704
26. Stearns NA, Schaevitz LR, Bowling H, Nag N, Berger UV, Berger-Sweeney J. Behavioral and anatomical abnormalities in Mecp2 mutant mice: a model for Rett syndrome. *Neuroscience*. 2007; 146: 907 - 921
27. Morrow EM, Yoo SY, Flavell SW, Kim TK, Lin Y, Hill RS, Mukaddes NM, Balkhy S, Gascon G, Hashmi A, Al-Saad S, Ware J, Joseph RM, Greenblatt R, Gleason D, Ertelt JA, Apse KA, Bodell A, Partlow JN, Barry B, Yao H, Markianos K, Ferland RJ, Greenberg ME, Walsh CA. Identifying autism loci and genes by tracing recent shared ancestry. *Science*. 2008; 321: 218 - 223
28. Saugier-Verber P, Goldenberg A, Drouin-Garraud V, De La Rochebrochard C, Layet V, Drouot N, Le Meur N, Gilbert-Dussardier B, Joly-Hélas G, Moïrot H, Rossi A, Tosi M, Frébourg T. Simple detection of genomic microdeletions and microduplications using QMPSF in patients with idiopathic mental retardation. *Eur J Hum Genet*. 2006; 14: 1009 - 1017
29. Bendavid C, Dubourg C, Pasquier L, Gicquel I, Le Gallou S, Mottier S, Durou MR, Henry C, Odent S, David V. MLPA screening reveals novel subtelomeric rearrangements in holoprosencephaly. *Hum Mutat*. 2007; 28: 1189 - 1197

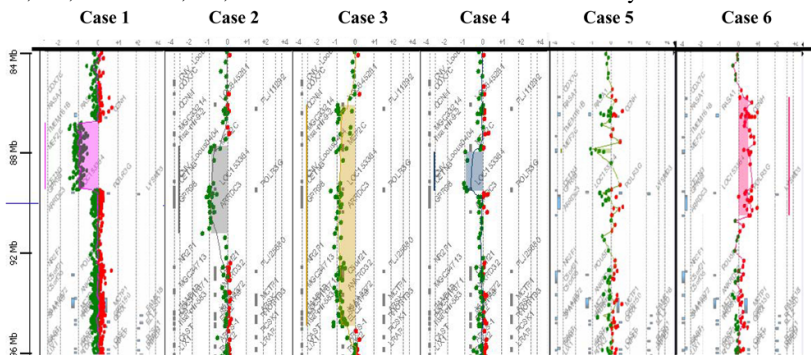
- 30 . Dehainault C , Laugé A , Caux-Moncoutier V , Pagès-Berhouet S , Doz F , Desjardins L , Couturier J , Gauthier-Villars M , Stoppa-Lyonnet D , Houdayer C . Multiplex PCR/liquid chromatography assay for detection of gene rearrangements: application to RB1 gene . *Nucleic Acids Res* . 2004 ; 32 : e139 -

Figure 1

Frontal and profile views of the 5 patients carrying 5q14 microdeletion or MEF2C mutation. Note high and wide forehead, thick eyebrows, short nose with anteverted nostrils, short and prominent philtrum, down turned corners of the mouth and small chin. (A) Case 1, note “question mark ears” (constriction at the junction between the lower and the middle thirds of the pinna); (B) Case 2; (C) Case 3; (D) Case 4; (E) Case 5; (F) Case 7 harbouring the MEF2C mutation.

**Figure 2**

Array-CGH profiles on chromosome 5 using Agilent 44K or 244K microarray (DNA analytics software display) showing the five microdeletions and the microduplication. In case 1, 244K microarray shows that the proximal and distal breakpoint of the deletion are respectively located between 86,939,816 and 87,005,072 and between 89,690,632 and 89,709,694. Using 44K microarrays, the proximal breakpoints of the four other deletions and of the duplication were located between 87,770,283 and 88,051,970 in case 2, between 86,142,271 and 86,412,812 in case 3, between 88,185,407 and 88,268,343 in case 4, between 87,770,283 and 88,051,970 in case 5 and between 85,951,601 and 86,142,512 in case 6. Note that in patient 4, the proximal breakpoint has been localized by qPCR, between 88,221,326 and 88,235,476. The distal breakpoints of these rearrangements are respectively located between 91,578,247 and 91,730,827 in case 2, between 95,315,261 and 95,494,937 in case 3, between 89843194 and 89966438 in case 4, between 88,268.402 and 88,629.033 in case 5 and between 90,712,814 and 90,731,163 in case 6. The Human Gene Assembly used to define the extensions of the deletion is Hg18.

**Figure 3**

Schematic representation of the 5q14 genomic region. MEF2C gene is indicated by black box. BAC clones appear above the genomic representation and black bars. The minimal extents of deletions and of the duplication are respectively shown by grey boxes and a black box below the chromosome scheme. The maximal extents of the region implicated are shown by dotted lines. Note that the smallest CNV detected is a deletion of a single gene, MEF2C, located from approximately 88,051,970 to 88,268,402 in hg 18 (in patient 5).

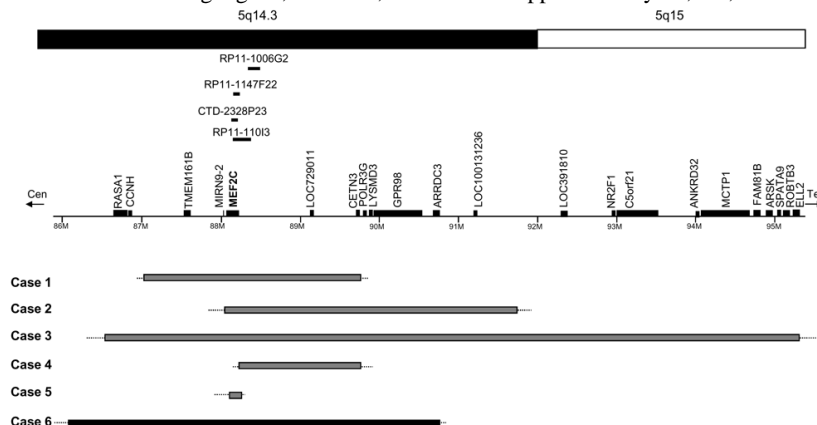


Figure 4

Confirmation of the 5q14 deletion by QMPSF and FISH in case 1. (A) Electropherogram in case 1 (in red) was superimposed to that of a normal female (in blue) by adjusting to the same level the peaks obtained for the HMBS and MECP2 control amplicons. Case 1 is a female. The Y axis displays fluorescence in arbitrary units, and the X axis indicates the size in bp. Heterozygous 5q14 deletions are easily detected by 50% reduction of the MEF2C peak in the patient compared to a normal control. (B) Results of two-colour FISH analysis in case 1 with RP11-1006G2 labelled with SpectrumGreen in combination with Cridu-chat syndrome probe used as control (5p15.2, Spectrum Green, 5q31 EGR1 Spectrum Orange, Abbott). Note that RP11-1006G2 is lacking on one chromosome 5 in the patient and is present on both homologous chromosomes in the parents, demonstrating de novo origin of the deletion. (C) Sequencing DNA chromatogram in case 7. Arrow indicates the c.683 C>G mutation within exon 7 of MEF2C .

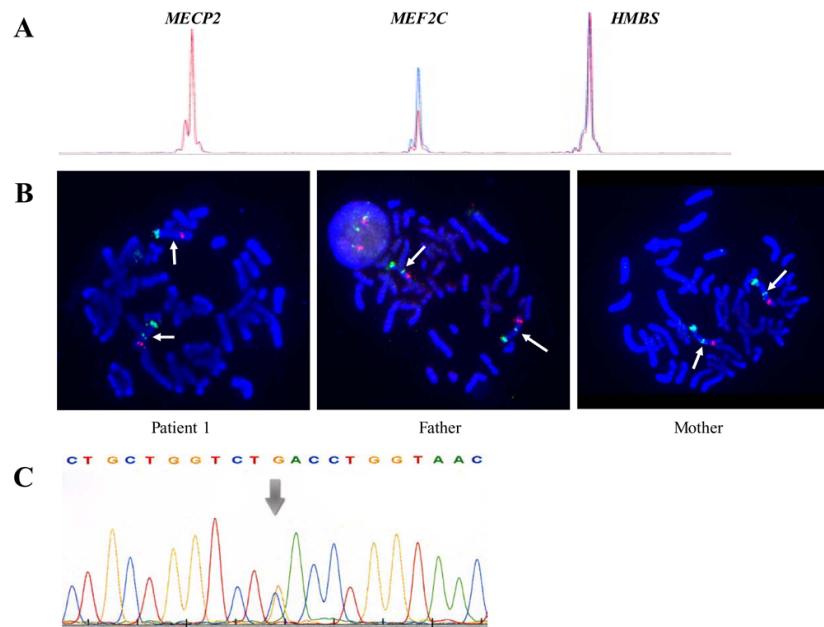


Table 1

Clinical findings in the 6 patients with MEF2C deletions or mutation

	Case 1	Case 2	Case 3	Case 4	Case 5	Case 7
Age at last examination	4 years 9 months	9 months	18 months	3 years	8 years	7 years
Birth weight/length/OFC	0 SD/0 SD/0 SD	0 SD/0 SD/-3SD	+3 SD/+3 SD/-2.5 SD	-1 SD/+1.5 SD/-1 SD	-3SD/-3SD/-3SD	0 SD/0 SD/+1.5 SD
Postnatal weight/height/OFC	-0.5 SD/-0.5 SD/-0.5 SD	+2 SD/-0.5 SD/-2 SD	-2 SD/0 SD/+1 SD	-1 SD/+1 SD/-0.5 SD	-1SD/-1 SD/-1.5 SD	0 SD/0 SD/+2 SD
Hypotonia	+	+	+	+	+	-
Head control (age)	+ (1 year)	-	-	+ (7 months)	+ (1 year)	+ (1 year)
Sitting position (age)	+ (4 years)	-	-	+ (18 months)	+ (3 years)	+ (2 years)
Independent walking (age)	-	-	-	-	-	+ (3 years)
Poor eye contact	+	+	+	+	+	+
Absent speech	+	+	+	+	+	+
Stereotypic movements	+	-	-	+	+	+
High and broad forehead	+	+	+	+	+	-
Up slanted palpebral fissures	+	+	+	-	-	-
Short prominent philtrum	+	+	-	-	+	-
Dysmorphic features						
Small chin	+	+	+	+	-	-
Short nose	-	+	+	+	-	-
Deep set eyes	-	-	-	-	+	+
Large open mouth	-	-	-	+	+	-
Additional dysmorphic features	Dysplastic ears, Sus-sternal fistula, Lobulation of the tongue	-	Thin upper lip, clinodactyly of both 5 th fingers, Simian creases,	-	-	-
Epilepsy type/onset	Myoclonic, refractory/4 months	Tonicoclonic, refractory/neonatal	-	-	Febrile seizure controlled by valproate/3 years	Tonicoclonic controlled by valproate/9 months
Abnormal corpus callosum	-	+	+	-	+	-
MRI						
Other brain MRI anomalies	Fronto parietal atrophy, Enlarged pericerebral spaces	Enlarged lateral ventricles, Reduced cortical gyration	Verticalisation of the tent of the cerebellum, Enlarged 4 th ventricle	Enlarged 4 th ventricle	-	Enlarged lateral ventricles, Periventricular white-matter hyperintensities
Periventricular heterotopia	-	-	-	-	-	-
Additional features		Oedema of hands and feet	Bilateral 2-3 toe syndactyly, Ectopic testis	Left 2-3 toe syndactyly, Right distal phalange Agnesis of toes 2-5	Episodic hyperventilation and apnea	Feeding difficulties

OFC, occipitofrontal circumference; SD, standard deviation; MRI, magnetic resonance imaging; EEG, electroencephalogram