



HAL
open science

Multimodal MRI segmentation of ischemic stroke lesions

Yacine Kabir, Michel Dojat, Benoît Scherrer, Florence Forbes, Catherine Garbay

► **To cite this version:**

Yacine Kabir, Michel Dojat, Benoît Scherrer, Florence Forbes, Catherine Garbay. Multimodal MRI segmentation of ischemic stroke lesions. EMBS 2007 - 29th Annual International Conference of the IEEE Engineering in Medicine and Biology Society, Aug 2007, Lyon, France. pp.1595-1598, <10.1109/IEMBS.2007.4352610>. <inserm-00402278>

HAL Id: inserm-00402278

<https://inserm.hal.science/inserm-00402278v1>

Submitted on 7 Jul 2009

HAL is a multi-disciplinary open access archive for the deposit and dissemination of scientific research documents, whether they are published or not. The documents may come from teaching and research institutions in France or abroad, or from public or private research centers.

L'archive ouverte pluridisciplinaire HAL, est destinée au dépôt et à la diffusion de documents scientifiques de niveau recherche, publiés ou non, émanant des établissements d'enseignement et de recherche français ou étrangers, des laboratoires publics ou privés.



HAL Authorization

Multimodal MRI segmentation of ischemic stroke lesions

Y.Kabir, M.Dojat, B.Scherrer, F.Forbes, C.Garbay

Abstract— The problem addressed in this paper is the automatic segmentation of stroke lesions on MR multi-sequences. Lesions enhance differently depending on the MR modality and there is an obvious gain in trying to account for various sources of information in a single procedure. To this aim, we propose a multimodal Markov random field model which includes all MR modalities simultaneously. The results of the multimodal method proposed are compared with those obtained with a mono-dimensional segmentation applied on each MRI sequence separately. We constructed an Atlas of blood supply territories to help clinicians in the determination of stroke subtypes and potential functional deficit.

I. INTRODUCTION

Stroke is a major cause of death and disability in both the more developed and the less developed world [9] [20]. Stroke consumes an important part of the total healthcare costs (i.e. excluding social care and indirect costs) in Europe and the USA [8]. *Stroke* is a vernacular term that denotes the sudden development of a neurological deficit. The overwhelming majority of strokes can be placed into two categories: haemorrhage (10% to 15%) and ischemia (approximately 85%), we consider here only the former [5].

Ischemia is a physiological term indicating insufficient blood flow for normal cellular function. Cerebral ischemia occurs when blood flow to the brain is reduced in either a global or a focal fashion.

Magnetic resonance imaging (MRI) offers unique advantages for the evaluation of cerebral ischemia, which leads to alterations in the brain water content, even in its earliest stages. Because of MRI's inherent sensitivity to depict alterations in tissue-free water content, it can detect ischemic insult to the brain within 1 hour after onset (with a diffusion sequence) [5].

The standard questions that must be answered when imaging a patient with stroke by any method are: Is there another lesion mimicking stroke? Is there a haemorrhagic or ischemic stroke? Are there any clues as to the cause of the ischemic stroke? What is the volume of stroke? How old is the stroke? Is salvageable tissue present? [13].

In evaluating therapies for ischemic stroke patients, many physicians are interested in finding consistent, reliable estimates of lesion volume from MR images [19]. The

traditional way for assessing stroke lesions is based on a manual segmentation. It consists of a manual tracing of the stroke regions on all contiguous slices in which the lesion was judged to be present. This manual segmentation is both time consuming and subject to manual variation. Another disadvantage of these interventions is their reliance upon subjective judgments, which raises the possibility that different observers will reach different conclusions about the presence or absence of lesions, or even that the same observer will reach different conclusions on different occasions [9]. A computer automated algorithm to evaluate MRI stroke images as they are obtained may have therefore great clinical usefulness.

MRI Multimodal image segmentation attempts to take advantage of the different kinds of anatomical information provided by different imaging modalities. There are two major difficulties in performing multimodal image segmentation. First, multimodal data are not always available. Second, when the data are available, the various images are typically not in the same alignment, and therefore require registration.

II. RELATED WORK

A. Stroke lesion description

Ischemic stroke lesions in MR imaging are difficult to segment for various reasons, which include especially shape complexity and ambiguity. Creating and evaluating automatic methods for segmenting such lesions is difficult because ground-truth is elusive and stroke lesions are widely varied. In addition, accurate segmentation of stroke lesions requires anatomical knowledge. In particular changes in MR images due to ischemic stroke follow the vascular territory of the occluded blood vessel, which is characteristic of cerebrovascular disease and helps in differentiating it from other disease entities.

As a matter of fact, in the literature devoted to the segmentation of brain lesions, there has been few work done in the area of multimodal stroke segmentation [22].

Most of the work related concentrated on the detection of tumors [17][2] and multiple sclerosis lesions [14].

III. METHOD

A. Patients and MRI data acquisition

Our input is a series of slices taken from different MR modalities of the same individual for 3 time points (3 sessions) (fig.1). 56 patients referred to our institution (Neurology Department of Grenoble Hospital) for suspected

Manuscript received April 02, 2007.

Y.Kabir, M.Dojat and B.Scherrer are with INSERM U836-UJF-CEA-CHU (Grenoble Institute of Neuroscience). (e-mail: yacine.kabir@imag.fr, michel.dojat@ujf-grenoble.fr, benoit.scherrer@imag.fr)

C.Garbay is with LIG CNRS UMR 5217 (MAGMA) (e-mail: Catherine.Garbay@imag.fr)

F.Forbes is with INRIA-Laboratory, Jean Kuntzman, Grenoble University (e-mail: Florence.Forbes@inrialpes.fr)

acute stroke. All examinations were performed on the same 1.5-T imaging device (Philips).

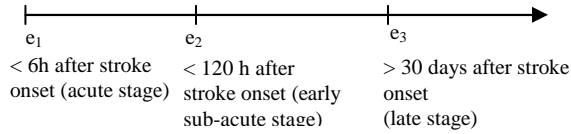


Fig 1. Time points acquisition corresponding to 3 MRI sessions

The MRI parameters were as follows: (1) axial T2FFE: TR/TE: 4096.87 ms/105.0 ms; Voxel size: $0.9375 \times 0.9375 \times 5$; Flip angle: 15° (2) axial DW: TR/TE: 4599ms / 101 ms; Voxel size: $0.9375 \times 0.9375 \times 5$; Flip angle: 90° (3) axial FLAIR: TR/TE, 10000 ms/140 ms; $0.9375 \times 0.9375 \times 5$; Flip angle: 90° .

B. Registration

A coregistration operation by affine transformation was used to correct the misalignment and mismatch among the different imaging modalities caused by patient movement or other factors [4], we consider the T2 sequence of session 1 as a reference image for all other sequences of all sessions.

C. Segmentation

Before performing the segmentation, the skull is removed from the images to keep brain tissues only [18].

We consider a finite set of N voxels $V = \{1, \dots, N\}$ on a regular three dimensional (3D) grid. When considering m different sequences simultaneously, each voxel i , $i \in \{1, \dots, N\}$, is described by a m -D intensity vector $\mathbf{y}_i = (y_{i1}, \dots, y_{im})$. Our aim is to assign each voxel i to one of K classes considering the observed grey level intensities \mathbf{y}_i at voxel i . Lesion voxels are assumed to be distinctly different from normal tissues and we consider $K=4$ corresponding to 4 classes, namely, White Matter (WM), Grey Matter (GM), Cerebro-Spinal Fluid (CSF) and the lesion. Similarly to [14] for Multiple Sclerosis data, we consider Stroke lesions as an additional class.

Both observed intensities and unknown classes are considered to be random field denoted respectively by $Y = \{Y_1, \dots, Y_N\}$ and $Z = \{Z_1, \dots, Z_N\}$. Each random variable Z_i takes its values in $\{e_1, \dots, e_K\}$ where e_k is a K -dimensional binary vector corresponding to class k . Only the k^{th} component of this vector is non zero and is set to 1. In a traditional Markov model based segmentation framework, it is assumed that the conditional field Z given $Y=y$ is a Markov random field, ie.

$$p(z|Y = y, \Phi) = W_{y,\Phi}^{-1} \exp(-H(z|y, \Phi)) \quad (1)$$

where $H(z|y, \Phi)$ is an energy function depending on some parameters $\Phi = (\Phi_y, \Phi_z)$ and given by:

$$H(z|y, \Phi) = H(z|\Phi_z) - \sum_{i \in V} \log p(y_i|z_i, \Phi_y) \quad (2)$$

This energy is a combination of two terms: the first term in

(2) is a regularization term that accounts for spatial dependencies between voxels. Denoting by $N(i)$ the neighbours of voxels i , we will consider a Potts model with external field

$$H(z|\Phi_z) = \sum_{i \in V} \left[z_i^t v_i - \frac{\beta}{2} \sum_{j \in N(i)} z_i^t z_j \right] \quad (3)$$

The second summation above tends to favour neighbours that are in the same class when parameter β is positive. This β accounts for the strength of spatial interaction. Other parameters are the v_i 's that are K -dimensional vectors defining the so-called external field. In this case $\Phi_z = \{v_1, \dots, v_N, \beta\}$. The v_i 's can be related to a priori weights accounting for the relative importance of the K classes at site i . The introduction of these extra parameters in the standard Potts model enables us to integrate *a priori* knowledge on classes. The second term in (2) is a data driven term based on intensities. For MRI we generally consider a Gaussian probability density function for the observed intensities \mathbf{y}_i when the tissue class is z_i . It follows that $p(y_i|Z_i=e_k, \Phi_y) = g(y_i|\mu_k, \Sigma_k)$ with

$$g(y_i|\mu_k, \Sigma_k) = \frac{1}{(2\pi)^{m/2} |\Sigma_k|^{1/2}} \exp\left\{-\frac{1}{2}(y_i - \mu_k)^T \Sigma_k^{-1} (y_i - \mu_k)\right\} \quad (4)$$

Where μ_j and Σ_j are the mean vector and covariance matrix of the j -th Gaussian. It follows that $\Phi_y = \{\mu_k, \Sigma_k, k=1 \dots K\}$. Segmentation is then performed according to the Maximum A Posteriori principle (MAP) by maximizing over z the probability $p(z|Y=y, \Phi)$. This requires the evaluation of an intractable normalizing constant $W_{y,\Phi}$ and the estimation of unknown parameters Φ . A standard approach is to use the ICM algorithm that alternates between parameter estimation and segmentation but results in biased estimates. EM-based algorithms and variants proposed by [11] can be rather considered. They are based on Mean-field like approximations which make the MRF models case tractable. In all these approaches, MRF estimation is performed globally through the entire volume.

D. Digital Atlas of Brain Blood supply territories

We constructed a digital Atlas of the Blood supply territories of the brain (BST), derived from the 12 printed serial sections in the axial plan developed by Tatu et al. [21]. The atlas fits the Talairach space, this 3D atlas is used to determine the stroke subtype.

IV. RESULTS

To assess the gain in considering multimodal data we compare the segmentations obtained with single sequences to that obtained with multiple sequences (Fig. 2). Single modality segmentations show as expected that some of the modalities are not or less informative in term of lesion detection and cannot therefore be considered alone. In addition, the modalities information varies with the session. The multimodal approach has the advantage to intrinsically

take that into account and to provide satisfactory results in all cases. Further analysis is required. In particular we propose to use Blood Supply territories Atlas (Fig. 3) to further assess the performance of the approach.

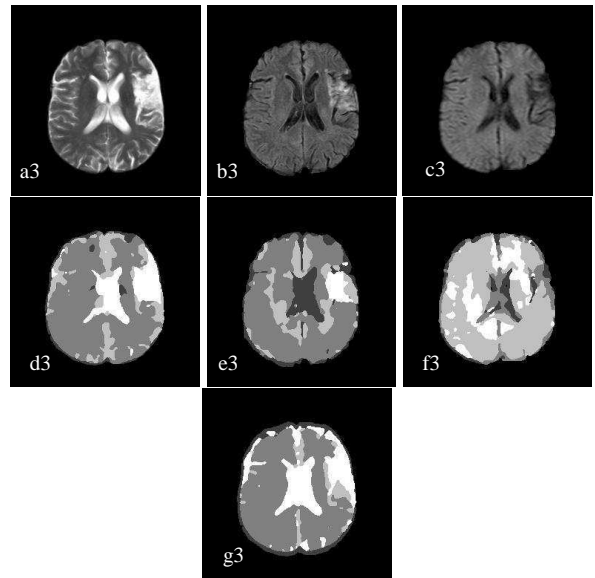
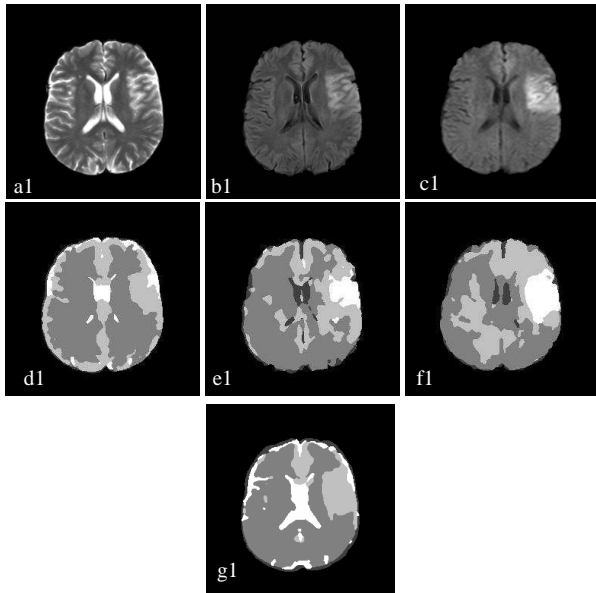
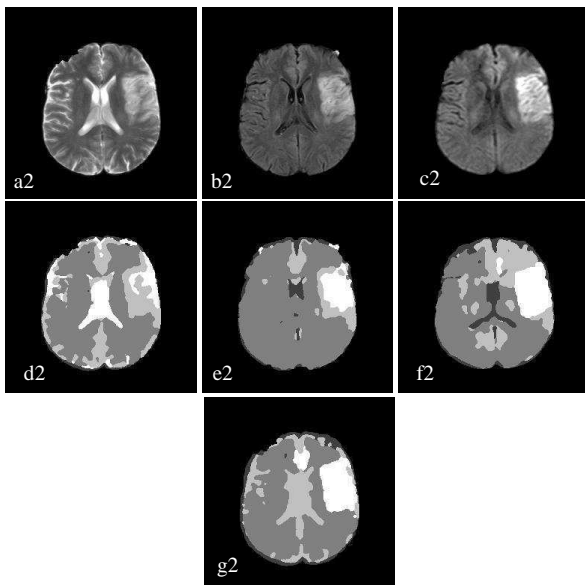


Fig.2. MRI sequences with a stroke lesion in the middle cerebral artery territory (MCA)
 (ai) T2 sequence, (bi) Flair sequence, (ci) Diffusion sequence for the session i,
 (di),(ei) (fi) Segmentation of each sequence separately,
 (gi) Multimodal segmentation for session i
 i=1, 2, 3 correspond to sessions e₁, e₂, e₃ respectively



We have normalized the segmented images obtained into Talairach space in order to superimpose them on the Atlas of flood supply territories, we can see clearly that the stroke lesion is located in the Middle cerebral artery (MCA), such information is very relevant in the functional deficit determination and medical prognostic (Fig. 4).

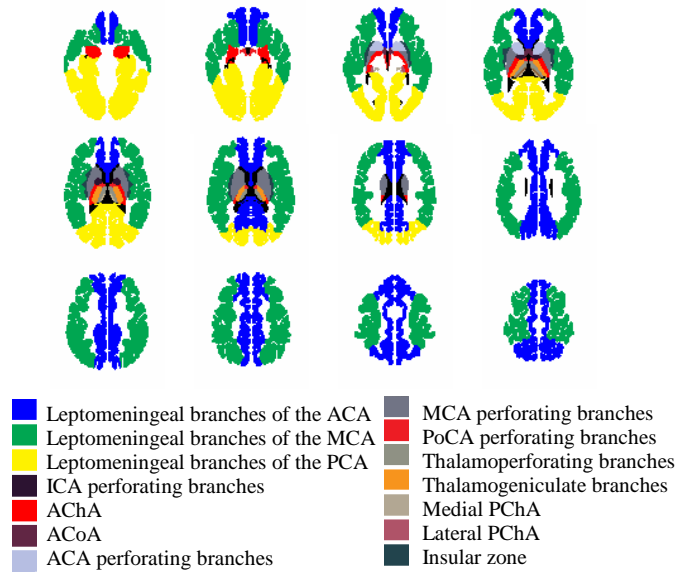


Fig.3. Normalized Blood Supply Territories Atlas derived from [21]

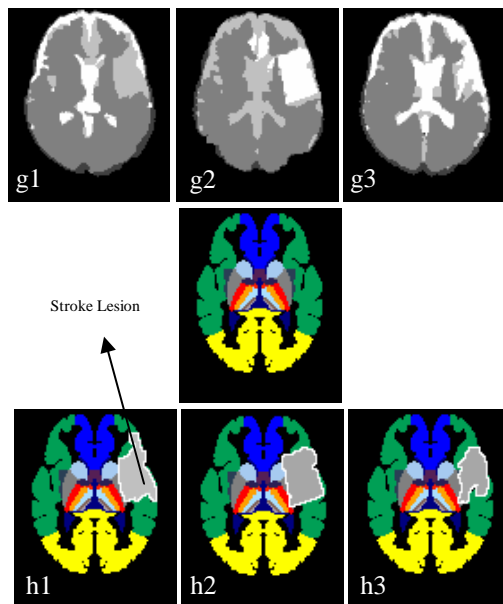


Fig.4. Use of the Blood Supply Territories Atlas for the determination of stroke subtype on the segmented images, (top) multimodal segmentation of the 3 MRI sessions, (middle) corresponding Atlas slice, (bottom) delineation of the lesion superimposed on the Atlas .

In Figure 4, the lesion present in the three sessions h1, h2 and h3 is mainly located in the MCA territory. For acute stage and sub-early acute stage, h1 and h2 respectively, the lesion seems extended to the deep territory (MCA perforating branches). However, for h3, the lesion is restricted to the leptomeningeal branches of the MCA. This indicates that the infarct extension to the deep territory is due to a cytotoxic edema developed during acute stage. This is confirmed by the clinician after an attentive examination on the images ai, bi, ci in Figure 2. By combining all the available information, the multi-modal segmentation appears as a powerful tool to correctly delineate the lesion, assign it the relevant vascular territory and provide synthetic information to the clinician.

V. SUMMARY AND CONCLUSION

An automatic MRI segmentation of stroke lesions was proposed, the algorithm is based on the simultaneous use of different MRI sequences to get more efficiency on lesion assessment. Preliminary experiments show promising results. Further algorithm refinements are required to obtain high level of sensitivity and make our system clinically viable. The potential impact on health care is great and continued efforts are warranted. Future work will focus on the use of Blood Supply Territories Atlas as a priori information in the segmentation process, in fact, a stroke lesion is restricted to a specific blood territory, this anatomical information can therefore be used to constraint the segmentation process to be restricted to a specific territory. The time dimension should be introduced in the algorithm by using the whole session series simultaneously.

REFERENCES

- [1] L. Ait-Ali et al. « STREM: A Robust Multidimensional Parametric Method to Segment MS Lesions in MRI », MICCAI 2005, Palm Springs, CA, USA. S. Lecture Notes in Computer Science, 3749, Springer-Verlag, 2005, vol. 3749, 409 p.
- [2] S. Capelle et al., "Evidential segmentation scheme of multi-echo MR images for the detection of brain tumors using neighbourhood information. *Information Fusion*, 5 :203–216, 2004.
- [3] MC. Clark et al.. Automatic tumor-segmentation using knowledge-based techniques. *IEEE Transactions on Medical Imaging* 117, 187–201, 1998
- [4] F. Collignon et al, "Automated multi-modality image registration based on information theory," in *Information Processing in Medical Imaging*, Y. Bizais et al Eds. 1995, pp. 263–274, Kluwer Academic Publishers
- [5] D. David et al.. *Magnetic Resonance Imaging*, C.V. Mosby; 3rd edition (January 15, 1999)
- [6] G. Dugas-Phocion et al. « Hierarchical Segmentation of Multiple Sclerosis Lesions in Multi-Sequence MRI », International Symposium on Biomedical Imaging, Arlington, VA, USA, April 2004. IEEE
- [7] G. Dugas-Phocion et al., "Improved EM-Based Tissue Segmentation and Partial Volume Effect Quantification in Multi-Sequence Brain MRI". *MICCAI'04*, Lecture Notes in Computer Science, Saint-Malo, France, September 2004. Springer.
- [8] M. Evers et al.. Economic evaluation in stroke research. *J Cerebrovasc Dis* 2000;11:82–91.
- [9] J A. Fiez et al. "Lesion Segmentation and Manual Warping to a Reference Brain: Intra- and Interobserver Reliability", *Human Brain Mapping* 9:192–211(2000)
- [10] H. Fletcher et al., "Automatic segmentation of non-enhancing brain tumors magnetic resonance images. *Artificial Intelligence in Medicine* 21, 43–63, 2001.
- [11] F. Forbes et al., "EM procedures using mean field-like approximations for Markov model-based image segmentation". *Pattern Recognition*, 36:1, 2003
- [12] RG. Gonzalez et al. Diffusion weighted MR imaging: diagnostic accuracy in patients imaged within 6 hours of stroke symptom onset. *Radiology* 1999;210: 155–162
- [13] N. Hoggard et al., "The Imaging of Ischaemic Stroke", *Clinical Radiology* (2001) 56: 171-183
- [14] K V. Leemput et al., "Automated Segmentation of Multiple Sclerosis Lesions by Model Outlier Detection", *IEEE Transactions On Medical Imaging*, VOL. 20, NO. 8, August 2001.
- [15] M. Masayuki et al., "Arterial Hyperintensity on Fast Fluid-attenuated Inversion Recovery Images: A Subtle Finding for Hyperacute Stroke Undetected by Diffusion-weighted MR Imaging", *AJNR Am J Neuroradiol* 22:632–636, April 2001
- [16] D M. Mezzapesa et al., "Multimodal MR examination in acute ischemic stroke", *Neuroradiology* (2006) 48: 238–246
- [17] M. Prastawa , E.Bullitt, S.Ho, G.Gerig, "A brain tumor segmentation framework based on outlier detection", *Medical Image Analysis* 18(3): 217–231, 2004.
- [18] S M. Smith., "Fast robust automated brain extraction", *Human. Brain Mapping*. 2002, 17 (3), 143– 155.
- [19] B.Stem et al., « Statistical and Deformable Model Approaches to the Segmentation of MR Imagery and Volume Estimation of Stroke Lesions », MICCAI 2001
- [20] C L M. Sudlow et al. "Comparable studies of the incidence of stroke and its pathological types. Results from an international collaboration". *Stroke* 1997;28(3):491–9.
- [21] L.Tatu et al. " Arterial territories of the human brain", *NEUROLOGY* 50 June 1998
- [22] J.Weinman et al., "Nonlinear diffusion scale-space and fast marching level sets for segmentation of MR imagery and volume estimation of stroke lesions", *MICCAI 2003*, LNCS 2879, pp. 496–504, 2003.