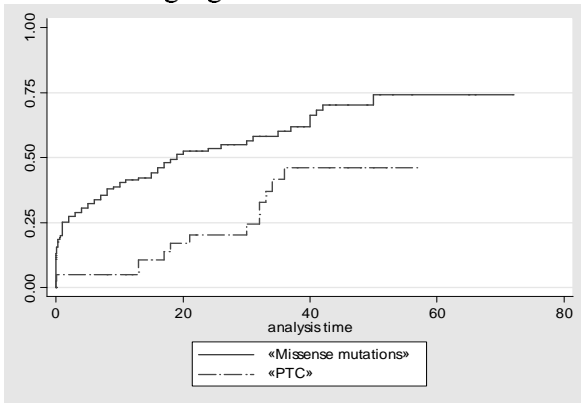


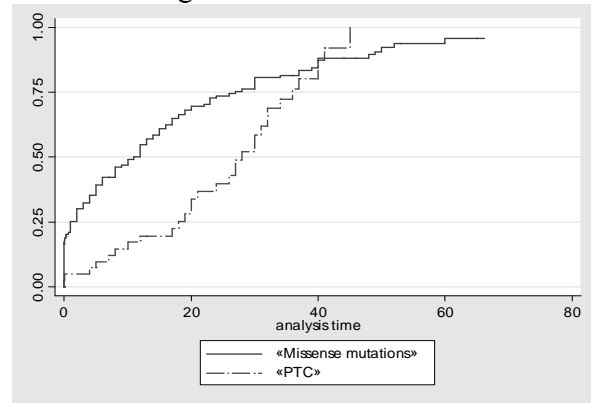
Figure 5

A : Mitral regurgitation



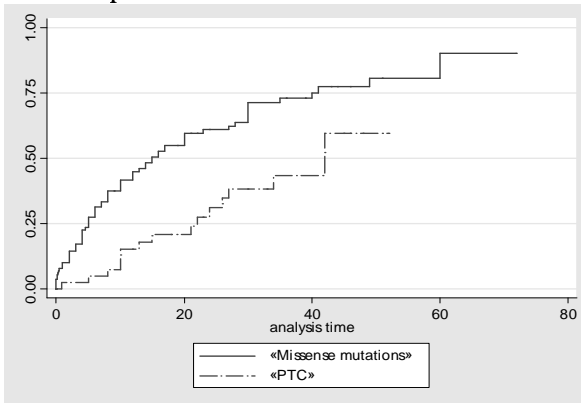
p=0.001

B : Ascending Aortic Dilatation



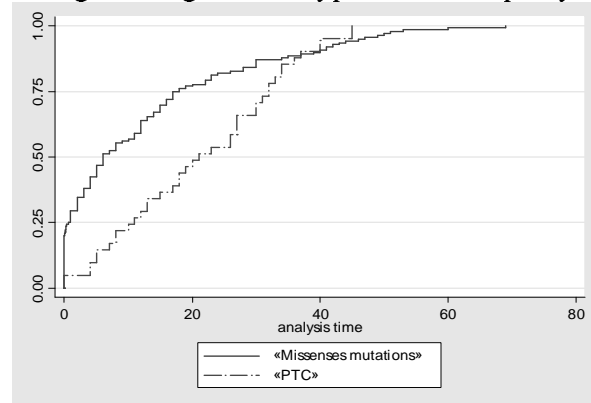
p=0.0218

C : Ectopia lentis



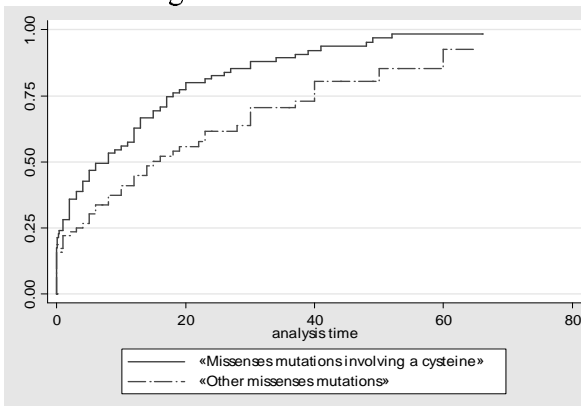
p=0.0009

D : Age at diagnosis of type I fibrillinopathy



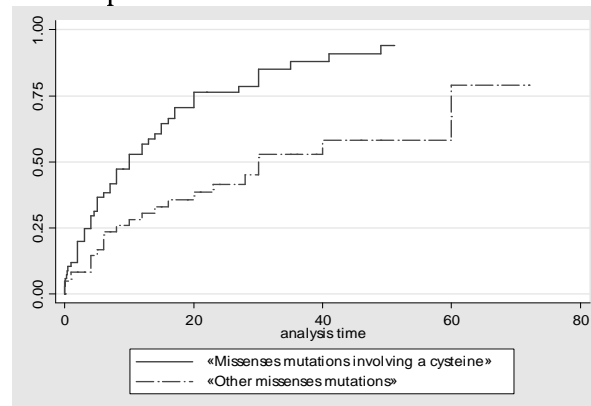
p=0.0278

E : Ascending Aortic Dilatation



p=0.0022

F : Ectopia lentis



p=0.0001