

188Re-loaded lipid nanocapsules as a promising radiopharmaceutical carrier for internal radiotherapy of malignant gliomas

Allard Emilie¹, Hindré François^{1*}, Passirani Catherine¹, Lemaire Laurent¹, Lepareur Nicolas², Noiret Nicolas³, Menei Philippe^{1,4}, Benoit Jean-Pierre¹

¹ Ingénierie de la vectorisation particulière INSERM : U646, Université d'Angers, Batiment IBT 10, Rue Andre Boquel 49100 ANGERS,FR

² Centre de Médecine Nucléaire CRLCC, Centre Eugène Marquis 35700 RENNES,FR

³ ENSCR, UMR CNRS 6052 CNRS : UMR6052, 35700 Rennes-Beaulieu France,FR

⁴ Service de neurochirurgie CHU Angers, Angers,FR

* Correspondence should be adressed to: François Hindré <francois.hindre@univ-angers.fr>

Abstract

Purpose

Lipid nanocapsules (LNC) entrapping lipophilic complexes of ¹⁸⁸Re (¹⁸⁸Re(S₃CPh)₂(S₂CPh) [¹⁸⁸Re-SSS]) were investigated as a novel radiopharmaceutical carrier for internal radiation therapy of malignant gliomas. The present study was designed to evaluate the efficacy of intracerebral administration of ¹⁸⁸Re-SSS LNC by means of convection-enhanced delivery (CED) on a 9L rat brain tumour model.

Methods

Female Fischer rats with 9L glioma were treated with a single injection of ¹⁸⁸Re-SSS LNC by CED 6 days after cell implantation. Rats were put into random groups according to the dose infused: 12, 10, 8, and 3 Gy in comparison with blank LNC, perrhenate solution (4Gy) and non-treated animals. The radionuclide brain retention level was evaluated by measuring ¹⁸⁸Re elimination in faeces and urine over 72h after the CED injection. The therapeutic effect of ¹⁸⁸Re-SSS LNC was assessed based on animal survival.

Results

CED of ¹⁸⁸Re perrhenate solution resulted in rapid drug clearance with a brain T_{1/2} of 7h. In contrast, when administered in LNC, ¹⁸⁸Re tissue retention was greatly prolonged, with only 10% of the injected dose being eliminated at 72h. Rat median survival was significantly improved for the group treated with 8Gy ¹⁸⁸Re-SSS LNC compared to the control group and blank-LNC treated animals. The increase in the median survival time (IST_{median}) was about 80% compared to the control group; 33% of the animals were long-term survivors. The dose of 8Gy proved to be a very effective dose, between toxic (10–12Gy) and ineffective (3–4Gy) doses.

Conclusions

These findings show that CED of Rhenium-188-loaded lipid nanocapsules is a safe and potent antitumour system for treating malignant gliomas. Our data are the first to show the in vivo efficacy of Rhenium-188 internal radiotherapy for the treatment of brain malignancy.

MESH Keywords Animals ; Bacterial Proteins ; Brain Neoplasms ; diagnosis ; radiotherapy ; Cell Line, Tumor ; Drug Carriers ; administration & dosage ; chemistry ; Female ; Gliosarcoma ; diagnosis ; radiotherapy ; Glucosyltransferases ; Lipids ; chemistry ; Nanostructures ; administration & dosage ; chemistry ; Radioisotopes ; administration & dosage ; chemistry ; Radiopharmaceuticals ; administration & dosage ; chemistry ; Rats ; Rats, Inbred F344 ; Rhenium ; administration & dosage ; chemistry ; Treatment Outcome

Author Keywords Lipid nanocapsules ; ¹⁸⁸Re ; 9L glioma model ; convection-enhanced delivery ; MRI

Introduction

Malignant gliomas are still associated with a poor prognosis despite advances in neurosurgery, radiotherapy and chemotherapy [1]. The median survival time after tumour resection, external beam irradiation, and various forms of chemotherapy, still lies in the range of 12 months, and more than 80% of patients have fatal local tumour recurrence [2]. Among many attempts to fight this disease, conclusive results have often been associated with the use of radiotherapy, alone or in combination with chemotherapy. Whereas classic radiotherapy involves external sources of radiation, internal tumour radiotherapy uses a radioisotope that is conjugated to a suitable agent such as an antibody, a peptide or a nanocarrier. Several nanoscale carriers (nanoparticles, liposomes, water-soluble polymers, micelles and dendrimers) have been developed for the targeted delivery of diagnostic and therapeutic cancer agents [3]. These carriers can selectively target cancer sites and carry large payloads, thereby improving cancer detection and therapy effectiveness. However, for therapeutic cancer applications, only a few attempts of internal radiotherapy have been described for the treatment of malignant gliomas [4, 5]. Among all the therapeutic radiopharmaceuticals used for radionuclide imaging and therapy, ¹⁸⁸Re is of widespread interest due to its attractive physical

and chemical properties [6] linked to its short physical half-life of 16.9h with 155keV gamma emissions for imaging and its 2.12MeV beta emission for therapy [7]. Furthermore, the availability of ^{188}Re from a generator at a reasonable cost has increased the clinical applications of ^{188}Re -labelled radiopharmaceuticals [8].

In a previous study, the formulation and biodistribution of ^{188}Re -labelled lipid nanocapsules (LNC) were assessed [9]. Neutral lipophilic complexes chosen for their affinity for hydrophobic substrates allowed the encapsulation of the radioelement in the LNC lipid core as well as labelling stability [10]. Prepared from a phase-inversion process [11], these LNC are characterised by a stable monodispersal size distribution and a small diameter in the range of 20 to 100nm. The present work has focused on the therapeutic application of such $^{188}\text{Re}(\text{S}_3\text{CPh})_2(\text{S}_2\text{CPh})$ complex (^{188}Re -SSS LNC) on a 9L rat glioma model. Convection- enhanced delivery (CED) [12], a direct intra-cerebral drug delivery technique that uses a bulk flow mechanism to distribute molecules to clinically significant volumes of tissue, was used to administer ^{188}Re -SSS LNC into rat brains. The aim of this work was to test the capacity of different ^{188}Re dose-loaded nanocapsules to eradicate tumours by studying the prolonged survival time of 9L glioma-bearing rats in comparison with the injection of ^{188}Re perrhenate solution and blank LNC.

Materials and methods

Materials

Lipophilic Labrafac[®] CC (caprylic-capric acid triglycerides) was kindly provided by Gattefosse S.A. (Saint-Priest, France). Lipoid[®] S75-3 (soybean lecithin at 69% of phosphatidylcholine) and Solutol[®] HS15 (a mixture of free polyethylene glycol 660 and polyethylene glycol 660 hydroxystearate) were a gift from Lipoid GmbH (Ludwigshafen, Germany) and BASF (Ludwigshafen, Germany), respectively. NaCl, dichloromethane and acetone were obtained from Prolabo (Fontenay-sous-bois, France). Deionised water was obtained from a Milli-Q plus system (Millipore, Paris, France).

Complex preparation

The lipophilic ^{188}Re -SSS [(bis(perthiobenzoato)(dithiobenzoato)rhenium(III))] was prepared according to a previously described process [9]. The radiochemical purity (RCP) of the ^{188}Re -SSS complex was checked by thin-layer chromatography as the ratio of migrated radioactivity to total radioactivity. Thin-layer chromatography was carried out using silica gel 60 F₂₅₄ alumina plates (Merck) and a solution of petroleum ether/dichloromethane (6/4, v/v) as an eluant (R_f 0.70). The detection was evaluated by a phospho-imager apparatus (Packard, Cyclone storage phosphor system).

Nanocapsule formulation

The preparation of ^{188}Re -SSS LNC was based on a phase-inversion process described by Heurtault et al. [11]. The suspension was prepared by mixing all the components under magnetic stirring (37.5mg Lipoid[®], 423mg Solutol[®], 514mg Labrafac[®], 44.5mg NaCl and 1,481mg deionized water). Because of its precipitation in aqueous media, the ^{188}Re -SSS complex was first extracted with dichloromethane (1ml) and then added to the other components of the emulsion. The organic solvent was then removed by heating at 60°C for 15min. Three cycles of progressive heating and cooling between 85°C and 60°C were then carried out allowing the residual organic solvent to evaporate. At 70°C and during the last cycle, an irreversible shock was induced by dilution with cold deionised water (1ml at 2°C), leading to the formation of stable nanocapsules. Afterwards, slow magnetic stirring was applied to the suspension for 5 min.

Nanocapsule characterisation

LNC were analysed for their size distribution using a Malvern Zetasizer[®] Nano Serie DTS 1060 (Malvern Instruments S.A., Worcestershire, UK). The complex formation yield was determined with a gamma counter (Packard Auto-Gamma 5,000 series) according to Eq. 1, and encapsulate rate was estimated according to Eq. 2. Before injection, ^{188}Re -SSS LNC were dialysed with deionised water at room temperature under magnetic stirring. Following this, dialysate samples were collected and counted to determine a dialysis recovery as shown in Eq. 3. As referred to the starting perrhenate activity, labeling yield was calculated by Eq. 4.

$$\text{Complex formation yield (\%)} = \frac{{}^{188}\text{Re - SSS complex activity}}{\text{starting perrhenate solution activity}} \times 100$$

$$\text{Encapsulation rate (\%)} = \frac{\text{LNC suspension activity}}{{}^{188}\text{Re - SSS complex activity}} \times 100$$

$$\text{Dialysis recovery (\%)} = \frac{\text{LNC suspension activity after dialysis}}{\text{LNC suspension activity before dialysis}} \times 100$$

$$\text{Labeling yield (\%)} = \frac{\text{LNC suspension activity after dialysis}}{\text{starting perrhenate solution activity}} \times 100$$

Animal study

Animals and anesthesia

Syngeneic Fischer F344 female rats weighing 150–175g were obtained from Charles River Laboratories France (L'Arbresle, France). All experiments were performed on 10 to 11-week old female Fisher rats. The animals were anaesthetised with an intraperitoneal injection of 0.75–1.5ml/kg of a solution containing 2/3 ketamine (100mg/ml) (Clorketam[®], Vétoquinol, Lure, France) and 1/3 xylazine (20mg/ml) (Rompun[®], Bayer, Puteaux, France). Animal care was carried out in strict accordance to the French Ministry of Agriculture regulations.

Cell culture and cell implantation

Rat gliosarcoma 9L cells were obtained from the European Collection of Cell Culture (Salisbury, UK, no. 94110705). The cells were grown at 37°C/5% CO₂ in Dulbecco's modified Eagle medium with glucose and L-glutamine (BioWhittaker, Verviers, Belgium) containing 10% foetal calf serum (FCS; BioWhittaker) and 1% antibiotic and antimycotic solution (Sigma, Saint-Quentin Fallavier, France). A cultured tumour monolayer was detached with trypsin-ethylenediamine tetraacetic acid, washed twice with Eagle's minimal essential medium without FCS or antibiotics, counted and re-suspended to the final concentration desired. For intra-cranial implantation, 10µl of 10³ 9L cell suspension were injected into the rat striatum at a flow rate of 2µl/min using a 10-µl syringe (Hamilton[®] glass syringe 700 series RN) with a 32-G needle (Hamilton[®]). For that purpose, rats were immobilised in a stereotaxic head frame (Lab Standard Stereotaxic; Stoelting, Chicago, IL). A sagittal incision was made through the skin, and a burr hole was drilled into the skull with a twist drill. The cannula coordinates were 1mm posterior from the bregma, 3mm lateral from the sagittal suture and 5mm below the dura (with the incisor bar set at 0mm). The needle was left in place for an additional 5min to avoid expulsion of the suspension from the brain during removal of the syringe, which was withdrawn very slowly (0.5mm/min).

Convection Enhanced Delivery (CED) procedure

On day6, 60µl of the LNC suspension was injected by CED at the coordinates of the tumour cells. Infusions were performed at the depth of 5mm from the brain surface using a 10-µl Hamilton[®] syringe with a 32-G needle. This syringe was connected to a 100-µl Hamilton 22-G syringe containing the product (Harvard Apparatus, Les Ulis, France) through a cannula (CoExTMPE/PVC tubing, Harvard Apparatus). CED was performed with an osmotic pump PHD 2,000 infusion (Harvard Apparatus) by controlling a 0.5 µl/min rate for 2h.

Subgroups

The rats treated with ¹⁸⁸Re-SSS LNC were put into four random sub-groups and received rhenium activity equivalent to 1.1 (group 1: n = 5; 3Gy), 2.8 (group 2: n = 6; 8Gy), 3.7 (group 3: n = 4; 10Gy) and 4.4MBq (group 4: n = 4; 12Gy), respectively. Group 5 received 60µl of ¹⁸⁸Re perrhenate solution equivalent to 1.5MBq (n = 4; 4Gy). Group 6 received blank LNC (n = 7), and rats of group 7 (control group) did not receive treatment by CED on day6 but were anaesthetized with the same protocol compared to the rats who underwent a CED infusion (n = 8). After treatment, rats from groups 4 and 5 were maintained in metabolism cages for 72h and were fed ad libitum. Urine and faeces were collected every 12h and measured with a gamma counter (Packard Auto-Gamma 5,000 series) to evaluate ¹⁸⁸Re elimination. Doses delivered to tumours were estimated according to Eq. 5:

$$D = \frac{A \times E_{\beta_{moy}} \times 0.576 \times T}{d \times V \times \ln 2}$$

where A = ¹⁸⁸Re activity delivered to each rat, E_{β_{moy}} = mean energy, T = physical half-life (16.9h) and d and V = density and volume of the irradiated organ. The irradiated organ was considered to be a sphere with a radius equivalent to ¹⁸⁸Re range of beta particles in tissue (¹⁸⁸Re R_{tissue} = 10.15mm) [7] and with a density of 1.

MRI and ¹H-magnetic resonance spectroscopy

MRI was performed with a Bruker Avance DRX 300 (Germany) apparatus equipped with a vertical superwide- bore magnet of 7T. Rapid qualitative T2-weighted images were obtained using rapid acquisition with relaxation enhancement (RARE) sequence (TR = 2,000ms; mean echo time (Tem) = 31.7ms; RARE factor = 8; FOV = 3 × 3cm; matrix 128 × 128; nine contiguous slices of 1mm, eight acquisitions). Magnetic resonance spectroscopy (MRS) was performed using a PRESS sequence with water suppression and cardiac triggering (Rapid Biomed GmbH, Germany). ¹H spectra were acquired with the following parameters: TR/TE = 1,500/11ms; NEX = 128; voxel size 27µl (3 × 3 × 3mm)

Statistical analysis

The Kaplan–Meier method was used to plot animal survival. Statistical significance was calculated using the log-rank test (Mantel–Cox Test). StatView software version 5.0 (SAS Institute) was used for that purpose, and tests were considered as significant with p values of less than 0.05. The different treatment groups were compared in terms of survival time, increase in survival time (IST median %), maximal survival time and long-term survivors.

RESULTS

Complex and Nanocapsule characterisation

^{188}Re -SSS complexes were obtained with satisfactory RCP. Physico-chemical properties of the LNC are given in Table 1. In the proportions described, blank LNC were obtained with a mean size of 55.7 +/- 1.7nm with a good polydispersity index (PI < 0.1). ^{188}Re -SSS LNC were measured at 55.5 +/- 11.5nm but an increase in polydispersity index (PI = 0.20) was observed. Measurement of LNC mean particle size before and after CED infusion showed that there was no size modification (data not shown). ^{188}Re complex formation yield was around 78%. Encapsulation of the ^{188}Re complex into LNC was very efficient (96.7%). Radiolabelling occurred during LNC formulation with important yields (98.5%) after elimination of ^{188}Re perrhenate which was not incorporated into the complex by dialysis. ^{188}Re -SSS LNC were obtained with a final labelling yield of 73.9%.

Internal radiotherapy study

Descriptive and statistical data from the radiotherapy study are summarised in Table 2. Rats were considered as long-term survivors if they survived up to 100 days after tumour implantation (four times the median survival of non-treated rats). As shown in Fig.1, all animals of the control group died due to tumour progression by day 27 and median survival was only 25 days. Rats of group 6, which received a CED infusion of blank LNC, died within 33 days post-implantation, and the median survival was 26 days. There was no significant difference between these two groups ($p > 0.05$). The experiments established that rat median survival was improved significantly for group 3, which was treated with 8Gy ^{188}Re -SSS LNC compared with group 6 (blank LNC) and the control group (no treatment) ($p = 0.0010$ and $p = 0.0003$, respectively). Animals treated with 8Gy ^{188}Re -SSS LNC showed excellent survival, with two of six rats surviving beyond day 100, a median survival of 45 days and an increase in the median survival time (IST_{median}) of 80% compared to the control group. At the highest dose of ^{188}Re activity (12Gy; group 1), 50% of the treated rats died after treatment and median survival was only 27.5 days. In spite of the presence of one long term survivor in this group, comparisons with group 6 or 7 were not significant ($p = 0.32$). At the equivalent dose of 10Gy, treatment with ^{188}Re -SSS LNC resulted in median survival of 28.5 days with one long-term survivor and an IST_{median} that relapsed to 14%. No significant difference was observed with the group treated with blank LNC ($p = 0.2386$), whereas a slight significant difference was noted for this group compared to the control group ($p = 0.0294$). Rats in group 4 treated with 3Gy ^{188}Re -SSS LNC died within 33 days post-implantation; their median survival was 28.0 days with an IST_{median} of 12%. A significant difference was only observed with the control group ($p = 0.0277$) whereas the significance was not shown with rats treated with blank LNC infusion ($p = 0.4858$). Group 5 treated with ^{188}Re perrhenate solution gave no positive results in terms of survival time because the median survival time was about 23.5 days, and no significant difference was observed with rats from the control group ($p = 0.1575$).

To assess ^{188}Re elimination, urine and faeces in two groups (groups 4 and 5) were collected and measured. CED infusion of ^{188}Re perrhenate solution revealed that more than 80% was eliminated in 12h and about 94% after 72h post-CED (Fig. 2a). Rhenium brain half-disappearance time (brain $T_{1/2}$) was equivalent to 7h and ^{188}Re perrhenate was mainly excreted by the kidneys as 99.4% of the total excreted radioactivity was recovered in urine (Fig. 2b). On the contrary, only 10% of ^{188}Re encapsulated in LNC was detected in urine and faeces 72h post-CED infusion. Among the 10% eliminated, LNC was mainly excreted in urine (75.8%; Fig. 2c).

Internal radiotherapy side effects

Two of the four rats infused with the highest dose of ^{188}Re -SSS LNC (12Gy) died on day 7, which was 1 day post-treatment. The two other rats showed clinical signs of toxicity including lethargy and a significant weight loss of 25% by day 18 (Fig. 3). None of the other animals that underwent CED of 10, 8 or 3Gy ^{188}Re -SSS LNC died post-treatment. A slight weight loss of 3.5% and 4.3 % was observed for the two groups treated with 10 and 8Gy ^{188}Re -SSS LNC, respectively, up to day 12. However, a very quick revival of weight was detected for the group treated with 8Gy ^{188}Re -SSS LNC from day 12 and up to day 30. No weight loss was observed for the groups treated with the lowest ^{188}Re doses, i.e. 3Gy ^{188}Re -SSS LNC and 4Gy ^{188}Re perrhenate solution.

Tumour proliferation was evaluated by MRI images. In vivo MRI images were assessed at day 16 (10 days post-CED) on one rat of the control group versus one rat treated with 10Gy ^{188}Re -SSS LNC (Fig. 4). T2-weighted images of the non-treated rat showed a hyper-intense signal on the right striatum caused by tumour tissue (Fig. 4a). On the contrary, images taken on the rat treated by internal radiotherapy showed a hypo-intense signal probably due to the CED infusion of ^{188}Re -SSS LNC (Fig. 4b).

Late side effects were also followed by MRI and by $^1\text{H-MRS}$ (Fig. 5). Images taken on day 83 revealed that the rat treated by internal radiotherapy presented a lesion localised in the right brain, mainly in the striatum but which also affected the ventricle (Fig. 5a). This lesion was still present on days 100 and 140 (Fig. 5b–c). $^1\text{H-MRS}$ performed on day 100 revealed that spectral data for N-acetylaspartate (NAA), creatine (Cr) and choline (Cho) were different in the right and left striata. In fact, the striatum affected by the lesion was characterised by a decrease in NAA and Cr associated with the presence of lactate (Fig. 5d).

DISCUSSION

The development of an in-house $^{188}\text{W}/^{188}\text{Re}$ -generator has greatly increased the use of ^{188}Re for treating various diseases [13]. Many new radiopharmaceuticals labelled with ^{188}Re have been developed, and some of them are currently used in clinical trials. Among different carriers, LNC labeled with a lipophilic complex of ^{188}Re ($^{188}\text{Re-SSS}$) can be obtained with high yield and satisfactory RCP [9]. This study investigated the therapeutic potential of this carrier for the treatment of malignant brain tumours. Due to the presence of the blood-brain barrier (BBB), which restricts the delivery of systemically administered agents, *in situ* administration was carried out using a direct intracranial drug delivery technique, CED [14]. This technique, introduced in 1994 as a method to circumvent the BBB and enhance the distribution of therapeutic agents by local administration, represents a promising technique for brain tumour therapy [15].

The incorporation of ^{188}Re complexes in LNC did not change the size of the particles. Only the polydispersity index was slightly enhanced ($\text{PI} = 0.208$) which represents a higher degree of heterogeneity but remained still inferior to 0.3. This can be explained by the presence of the lipophilic SSS-complexes, which were required for ^{188}Re insertion inside the LNC core. $^{188}\text{Re-SSS}$ LNC could be obtained with a very high labelling yield. This result was expected as the incorporation of lipophilic molecules during the LNC formulation process generally led to high encapsulation efficiency whatever the radionuclide used [16, 17]. These rates are above those obtained in liposome formulations in which the radionuclides are generally post-inserted [18, 19]. In addition, agents directly infused into the brain in a small volume can not readily disperse from their infusion site [20]; this is the reason why CED infusion was used to administer the nanocapsules. MacKay et al. studied the different parameters that can influence the distribution of liposomes in the brain [21]. Based upon these findings, the ideal nanoparticle for CED would be less than 100nm in diameter, have a neutral or negative surface charge, and would need a targeting ligand to adhere to a target cell. To minimise the dose fraction that could be scavenged by perivascular cells, mainly perivascular macrophages, nanoparticles should be shielded by polyethylene glycol (PEG) and infused at a high total lipid concentration. Our LNC, loaded with a ^{188}Re neutral complex, have a mean particle size of 55nm, are mainly composed of lipids, and are covered by a soft layer formed by PEG. They can be conjugated with the OX26 antibody, which binds them to transferrin receptors that are over-expressed both on brain cerebral endothelial cells and on glioma cells [22]. Furthermore, Garcion et al. showed that LNC were able to penetrate intracellular compartments of glioma cells by interacting with cholesterol-rich microdomains [23]. Such characteristics confer ideal properties to LNC to be administered by CED in the rat brain.

To obtain a therapeutic effect, the elimination of the radionuclides deposited by CED in the brain must be as slow as possible. Because perrhenate ($^{188}\text{ReO}_4^-$) is the chemical form of ^{188}Re which is obtained from the $^{188}\text{W}/^{188}\text{Re}$ -generator by elution with physiological saline, $^{188}\text{ReO}_4^-$ infusion in Fisher rat brains was compared to $^{188}\text{Re-SSS}$ LNC. While it has been largely described that perrhenate is rapidly excreted via the urinary bladder following an intravenous injection [24], nothing was known about the elimination of such a solution following brain administration. A largely significant difference between a CED infusion of perrhenate and of $^{188}\text{Re-SSS}$ LNC was observed. Eighty percent of ^{188}Re in solution was eliminated after 12h in accordance with findings by Knapp et al. with 70% of free perrhenate in urine excretions after 12h following an IV injection [13]. $^{188}\text{Re-SSS}$ LNC were found to be a sustained residency system, which constitutes a major advantage (1% of elimination after 12h). Like Noble et al. who showed that the encapsulation of CPT-11 in liposome resulted in at least 196-fold prolongation of residence time in brain tissue compared to free CPT-11 [25], we demonstrated that the lipophilic nature of LNC led to a long radionuclide brain retention time allowing improved tumour irradiation.

The internal radiotherapy study by CED administration of $^{188}\text{Re-SSS}$ LNC was carried out on a well-known 9L rat brain tumour model [26]. The inoculation of 9L cells usually results in 100% tumour take with untreated Fisher 344 rats with a median survival between 20 and 30 days after tumour inoculation [27]. In our study, neither the anaesthetic procedure nor the injection of blank LNC significantly modified the growth or lethality of the 9L gliomas, since the median survival time was 25 and 26 days for the untreated and the blank LNC groups, respectively. This was confirmed by MRI images where a tumour lesion is visible in a non-treated rat on day 16. As shown by Vonarbourg et al., 9L tumour growth is exponential since the tumour lesion volume is between $17 \pm 10\mu\text{l}$ and $167 \pm 19\mu\text{l}$ between days 14 and 24 [28]. The median survival of the group treated by a CED infusion of ^{188}Re perrhenate solution was in the same range as none of the rats survived beyond 26 days. The hydrophilic nature of this solution provoked a very rapid elimination from the brain, which made tumour eradication impossible. Similar results were found by Vavra et al. for the administration of ^{14}C -sucrose, a small water-soluble compound in RG-2 rat gliomas, after CED infusion with less than 3% of the administered dose still present after 1h in either the tumour or in surrounding brain tissues [29].

On the contrary, thanks to the high retention of LNC in rat brains, conclusive dose-dependent results were obtained with internal radiotherapy by ^{188}Re -SSS LNC. Toxicity was observed with the highest studied doses, especially for 12Gy ^{188}Re -SSS LNC. In fact, 50% of the rats died 1 day post-treatment, and a significant weight loss was observed for the two rats left, combined with other signs of toxicity like lethargy, passivity- and poor grooming. Despite the presence of a long-term survivor within this group, an internal irradiation dose of 12Gy can be considered as a toxic dose. For the intermediate dose of 10Gy, results were mitigated. A significant difference in median survival time was observed compared to the control group but not with the group that received blank LNC. The increase in the median survival time of 14% and the presence of one long-term survivor make this dosage midway between the effective and toxic doses. LNC with an equivalent dose of 8Gy constituted the most efficient group treatment in terms of survival, because a high increase in the median survival time of 80% was noted compared to the control group and because two rats from this group (33%) were long-term survivors. CED injection at this dosage seemed to be well tolerated since no side effects were observed except a very slight weight loss observed in the few days after treatment. For the smaller dose equivalent to 3Gy, internal radiotherapy with ^{188}Re -SSS LNC had no effect on survival time. This dosage was considered to be ineffective.

A comparison between our technique and external beam radiotherapy (XRT) is difficult, since the schemes of irradiation for many studies are very varied and often associated with chemotherapy [30–32]. The main theoretical advantage of internal radionuclide therapy with ^{188}Re -SSS LNC is that radiation can be delivered selectively to sub-clinical tumours and metastases that are too small to be imaged and thereby cannot be treated by surgical excision or local XRT.

However, despite obvious benefits noted with internal radiotherapy, side effects in rats were observed in the latter phase of the study. Magnetic resonance images carried out on one long-term survivor treated with 10Gy ^{188}Re -SSS LNC revealed lesions mainly contained in the right striatum, which was obviously not related to tumour tissue as it was still present on day 140 of the study. The histologic nature of the lesion was not identified but was linked to radiation injury. In fact, a decrease of the signal intensity for NAA and Cr with an increase of the lactate signal has often been described in cases of radiation injury [33, 34]. In an attempt to improve the therapeutic ratio, the delivery of ^{188}Re -SSS LNC in multiple fractions separated in time may improve efficacy by decreasing late effects on critical normal structures, while maintaining a high radiation dose distribution within tumour tissue. In terms of dosimetric evaluation, a more detailed study that may consider these parameters should be pursued. To mimic clinical practice, and because multi-therapy might be a solution in the fight against gliomas, chemotherapy could be included since LNC can be loaded with radiosensitive anti-cancer drugs such as etoposide or paclitaxel [23, 35].

Acknowledgements:

The authors are very grateful to Sandrine Vinchon-Petit for CED experiences and to Myriam Moreau for her help in LNC formulation (INSERM U646, Angers, France). We are also grateful to Pierre Legras and Jérôme Roux (Service Commun d'Animalerie Hospitalo – Universitaire, Angers, France) for their technical assistance in animal experiments. This work was supported by a “Région des Pays de la Loire” grant and by the county committee of Maine et Loire of “La ligue contre le cancer”. Animal care was carried out in strict accordance to French Ministry of Agriculture regulations.

References:

BIBLIOGRAPHY

1. Nieder C , Adam M , Molls M , Grosu AL Therapeutic options for recurrent high-grade glioma in adult patients: Recent advances. *Critical Reviews in Oncology/Hematology*. 2006; 60: (3) 181- 193
2. Behin A , Hoang-Xuan K , Carpentier AF , Delattre J-Y Primary brain tumours in adults. *Lancet*. 2003; 361: (9354) 323- 331
3. Mitra A , Nan A , Line BR , Ghandehari H Nanocarriers for nuclear imaging and radiotherapy of cancer. *Curr Pharm Des*. 2006; 12: (36) 4729- 4749
4. Barth RF , Yang W , Coderre JA Rat brain tumor models to assess the efficacy of boron neutron capture therapy: A critical evaluation. *Journal of Neuro-Oncology*. 2003; 62 : (1-2) 61- 74
5. Ljunggren K , Liu X , Erlandsson K , Ljungberg M , Salford L , Strand SE Absorbed dose distribution in glioma tumors in rat brain after therapeutic intratumoral injection of ^{201}Tl -chloride. *Cancer Biother Radiopharm*. 2004; 19: (5) 562- 569
6. Jeong JM , Chung J-K Therapy with ^{188}Re -Labeled Radiopharmaceuticals: An Overview of Promising Results from Initial Clinical Trials. *Cancer Biotherapy and Radiopharmaceuticals*. 2003; 18: (5) 707- 717
7. Iznaga-Escobar N ^{188}Re -direct labeling of monoclonal antibodies for radioimmunotherapy of solid tumors: Biodistribution, normal organ dosimetry, and toxicology. *Nuclear Medicine and Biology*. 1998; 25: (5) 441- 447
8. Lambert B , De Klerk JMH Clinical applications of ^{188}Re -labelled radiopharmaceuticals for radionuclide therapy. *Nuclear Medicine Communications*. 2006; 27: (3) 223- 229
9. Ballot S , Noiret N , Hindre F , Denizot B , Garin E , Rajerison H $^{99\text{mTc}}/^{188}\text{Re}$ -labelled lipid nanocapsules as promising radiotracers for imaging and therapy: Formulation and biodistribution. *European Journal of Nuclear Medicine and Molecular Imaging*. 2006; 33: (5) 602- 607
10. Mevellec F , Roucoux A , Noiret N , Patin H , Tisato F , Bandoli G Synthesis and characterization of the bis(trihiperoxybenzoate)(dithiobenzoate)rhenium(III) hetero complex. *Inorganic Chemistry Communications*. 1999; 2: (6) 230- 233
11. Heurtault B , Saulnier P , Pech B , Proust J-E , Benoit J-P A novel phase inversion-based process for the preparation of lipid nanocarriers. *Pharmaceutical Research*. 2002; 19: (6) 875- 880
12. Mardor Y , Rahav O , Zauberman Y , Lidar Z , Ocherashvilli A , Daniels D Convection-enhanced drug delivery: Increased efficacy and magnetic resonance image monitoring. *Cancer Research*. 2005; 65: (15) 6858- 6863
13. Knapp FF Jr , Guhlke S , Beets AL , Lin WY , Stabin M , Amols H Endovascular beta irradiation for prevention of restenosis using solution radioisotopes: pharmacologic and dosimetric properties of rhenium-188 compounds. *Cardiovasc Radiat Med*. 1999; 1: (1) 86- 97
14. Hunt Bobo R , Laske DW , Akbasak A , Morrison PF , Dedrick RL , Oldfield EH Convection-enhanced delivery of macromolecules in the brain. *Proceedings of the National Academy of Sciences of the United States of America*. 1994; 91: (6) 2076- 2080

- 15. Vogelbaum MA Convection enhanced delivery for the treatment of malignant gliomas: Symposium review. *Journal of Neuro-Oncology*. 2005; 73: (1) 57- 69
- 16. Jestin E , Mougín-Degraef M , Faivre-Chauvet A , Remaud-Le Saec P , Hindre F , Benoit JP Radiolabeling and targeting of lipidic nanocapsules for applications in radioimmunotherapy. *Q J Nucl Med Mol Imaging*. 2007; 51: (1) 51- 60
- 17. Lacoëuille F , Hindre F , Moal F , Roux J , Passirani C , Couturier O In vivo evaluation of lipid nanocapsules as a promising colloidal carrier for paclitaxel. *Int J Pharm*. 2007;
- 18. Bao A , Goins B , Klipper R , Negrete G , Mahindaratne M , Phillips WT A novel liposome radiolabeling method using ^{99m}Tc -“ SNS/S” complexes: In vitro and in vivo evaluation. *Journal of Pharmaceutical Sciences*. 2003; 92: (9) 1893- 1904
- 19. Judge LM , O’Leary DJ , Fujii G , Skenes C , Paquette T , Proffitt RT A hydrazino nicotinamide derivative of cholesterol for radiolabelling liposomes with ^{99m}Tc . *Journal of Labelled Compounds and Radiopharmaceuticals*. 1999; 42: (1) 23- 28
- 20. Sendelbeck SL , Urquhart J Spatial distribution of dopamine, methotrexate and antipyrine during continuous intracerebral microperfusion. *Brain Research*. 1985; 328: (2) 251- 258
- 21. MacKay JA , Deen DF , Szoka FC Jr Distribution in brain of liposomes after convection enhanced delivery; Modulation by particle charge, particle diameter, and presence of steric coating. *Brain Research*. 2005; 1035: (2) 139- 153
- 22. Beduneau A , Saulnier P , Hindre F , Clavreul A , Leroux JC , Benoit JP Design of targeted lipid nanocapsules by conjugation of whole antibodies and antibody Fab’ fragments. *Biomaterials*. 2007; 28: (33) 4978- 4990
- 23. Garcion E , Lamprecht A , Heurtault B , Paillard A , Aubert-Pouessel A , Denizot B A new generation of anticancer, drug-loaded, colloidal vectors reverses multidrug resistance in glioma and reduces tumor progression in rats. *Mol Cancer Ther*. 2006; 5: (7) 1710- 1722
- 24. Hsieh BT , Hsieh JF , Tsai SC , Lin WY , Huang HT , Ting G Rhenium-188-Labeled DTPA: a new radiopharmaceutical for intravascular radiation therapy. *Nucl Med Biol*. 1999; 26: (8) 967- 972
- 25. Noble CO , Krauze MT , Drummond DC , Yamashita Y , Saito R , Berger MS Novel nanoliposomal CPT-11 infused by convection-enhanced delivery in intracranial tumors: pharmacology and efficacy. *Cancer Res*. 2006; 66: (5) 2801- 2806
- 26. Barth RF Rat brain tumor models in experimental neuro-oncology: the 9L, C6, T9, F98, RG2 (D74), RT-2 and CNS-1 gliomas. *J Neurooncol*. 1998; 36: (1) 91- 102
- 27. Kimler BF The 9L rat brain tumor model for pre-clinical investigation of radiation-chemotherapy interactions. *J Neurooncol*. 1994; 20: (2) 103- 109
- 28. Vonarbourg A , Sapin A , Lemaire L , Franconi F , Menei P , Jallet P Characterization and detection of experimental rat gliomas using magnetic resonance imaging. *Magnetic Resonance Materials in Physics, Biology and Medicine*. 2004; 17: (3-6) 133- 139
- 29. Vavra M , Ali MJ , Kang EW , Navalitloha Y , Ebert A , Allen CV Comparative pharmacokinetics of ^{14}C -sucrose in RG-2 rat gliomas after intravenous and convection-enhanced delivery. *Neuro Oncol*. 2004; 6: (2) 104- 112
- 30. Kimler BF , Martin DF , Evans RG , Morantz RA , Vats TS Combination of radiation therapy and intracranial bleomycin in the 9L rat brain tumor model. *Int J Radiat Oncol Biol Phys*. 1990; 18: (5) 1115- 1121
- 31. Lemaire L , Roullin VG , Franconi F , Venier-Julienne MC , Menei P , Jallet P Therapeutic efficacy of 5-fluorouracil-loaded microspheres on rat glioma: a magnetic resonance imaging study. *NMR Biomed*. 2001; 14: (6) 360- 366
- 32. Li Y , Owusu A , Lehnert S Treatment of intracranial rat glioma model with implant of radiosensitizer and biomodulator drug combined with external beam radiotherapy. *Int J Radiat Oncol Biol Phys*. 2004; 58: (2) 519- 527
- 33. Schlemmer H-P , Bachert P , Herfarth KK , Zuna I , Debus J , Van Kaick G Proton MR spectroscopic evaluation of suspicious brain lesions after stereotactic radiotherapy. *American Journal of Neuroradiology*. 2001; 22: (7) 1316- 1324
- 34. Zeng Q-S , Li C-F , Liu H , Zhen J-H , Feng D-C Distinction Between Recurrent Glioma and Radiation Injury Using Magnetic Resonance Spectroscopy in Combination With Diffusion-Weighted Imaging. *International Journal of Radiation Oncology Biology Physics*. 2007; 68: (1) 151- 158
- 35. Lamprecht A , Benoit J-P Etoposide nanocarriers suppress glioma cell growth by intracellular drug delivery and simultaneous P-glycoprotein inhibition. *Journal of Controlled Release*. 2006; 112: (2) 208- 213

Figure 1

Graph of Kaplan-Meier survival curve associated with treatment of rat bearing 9L glioma with single CED infusion of blank LNC, ^{188}Re -SSS LNC or ^{188}Re perrhenate. On day 6, rats were treated with 12 Gy ^{188}Re -SSS LNC (n=4; -⊕-), 10 Gy ^{188}Re -SSS LNC (n=4; -×-), 8 Gy ^{188}Re -SSS LNC (n=6; -▽-), 3 Gy ^{188}Re -SSS LNC (n=5; -◇-), 4 Gy ^{188}Re perrhenate (n=4; -◄-), blank LNC (n=7; -○-), or no treatment (n=8; -■-). Four rats (*) were long-term survivors (>100 days).

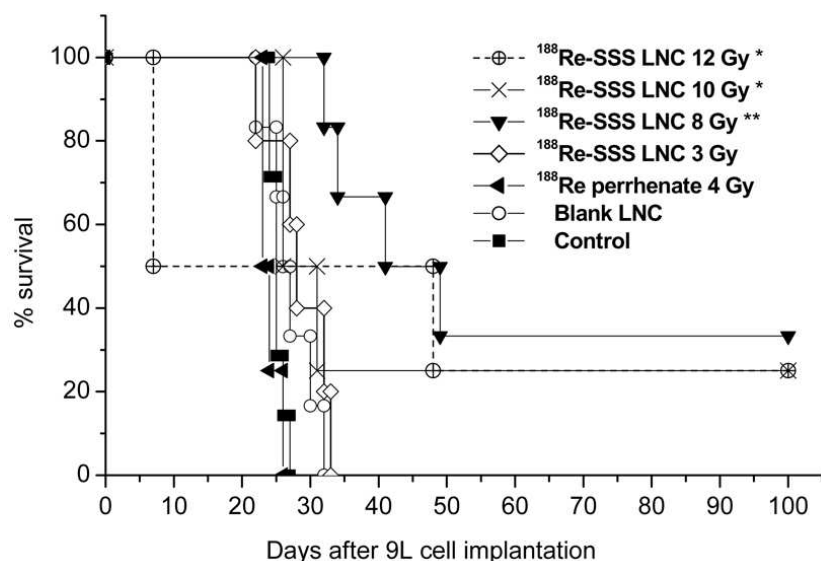


Figure 2

^{188}Re elimination measured in urine and faeces by a gamma counter during 72h after CED infusion of ^{188}Re perrhenate, and ^{188}Re -SSS LNC in 9L glioma bearing rats 6 days post 9L cell implantation (A). Repartition between urines and faeces for ^{188}Re perrhenate solution (B) and ^{188}Re -SSS LNC (C).

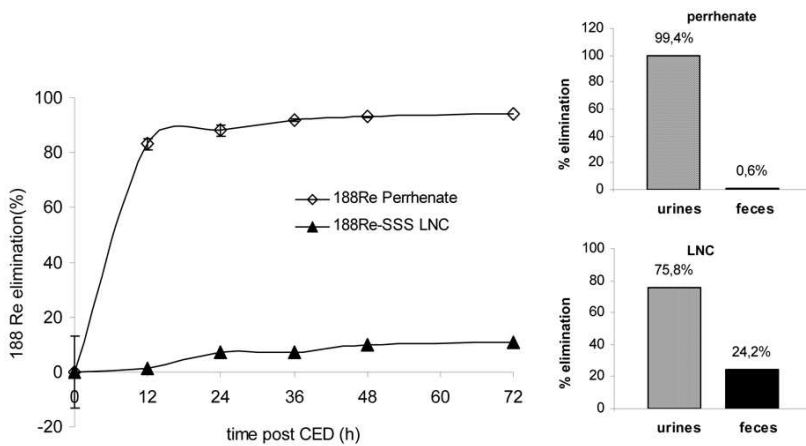


Figure 3

Evolution of weight measurements during 30 days after 9L inoculation in rats which received ^{188}Re -SSS LNC or ^{188}Re perrhenate solution for internal radiotherapy.

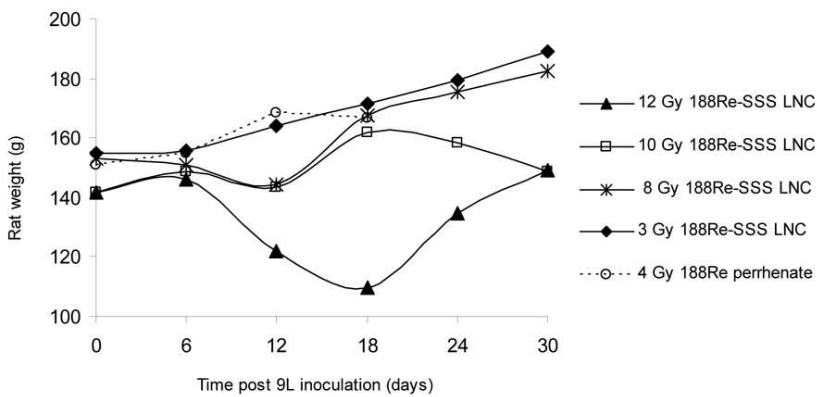


Figure 4

T2-weighted axial magnetic resonance images of a non treated rat (A) at Day 16 after 9L inoculation compared with a long-term survivor rat which received 10 Gy ^{188}Re -SSS LNC at Day 16 (B).

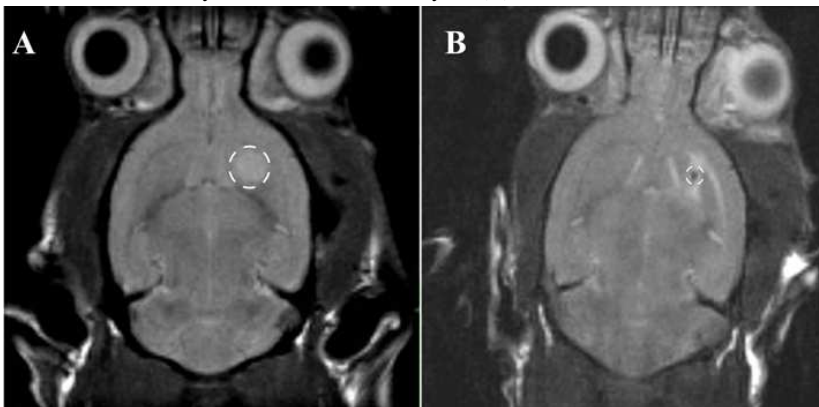


Figure 5

T2-weighted axial magnetic resonance images of one long-term survivor rat which received 10 Gy ^{188}Re -SSS LNC at Days 83, 100, and 140, respectively for A, B and C. D represents the ^1H -MR spectra realised at Day 100. Signal intensities of creatine (Cr), N-acetyl aspartate (NAA) and Lactate (Lac) were compared between affected striatum (i) and safe striatum (ii). iii represents the difference between the two spectra.

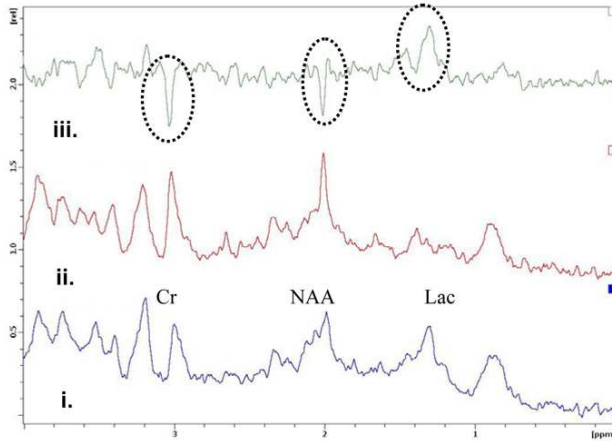
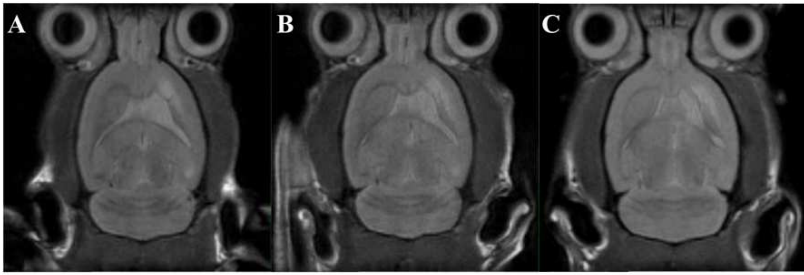

Table 1Physico-chemical characteristics of blank and ¹⁸⁸Re SSS LNC.

	Mean particle size (nm)	Polydispersity index (PI)	Complex formation yield (%)	Encapsulation rate (%)	Dialysis recovery (%)	Labeling yield (%)
Blank LNC	55.7 ± 1.7	0.084 ± 0.003	-	-	-	-
¹⁸⁸ Re-SSS LNC	55.5 ± 11.5	0.208 ± 0.051	77.6	96.7	98.5	73.9

Table 2

Descriptive and statistical data from the radiotherapy study.

	Median survival time (days)	IST median (%)	Maximal survival time (days)	Long term survivors	P values versus control	P values versus blank LNC
1 12 Gy ¹⁸⁸Re-SSS LNC	27.5	10	> 100	1	0.3210	0.3205
2 10 Gy ¹⁸⁸Re-SSS LNC	28.5	14	> 100	1	0.0294	0.2386
3 8 Gy ¹⁸⁸Re-SSS LNC	45.0	80	> 100	2	0.0003	0.0010
4 3 Gy ¹⁸⁸Re-SSS LNC	28.0	12	33	0	0.0277	0.4858
5 4 Gy ¹⁸⁸Re perhenate	23.5	0	26	0	0.1575	0.0942
6 Blank LNC	26.0	4	33	0	0.1729	-
7 Control = No treatment	25.0	-	27	0	-	0.1729

The increases in median survival time (IST_{median}%) are calculated in comparison to the control group. Survival data were analysed using the logrank test (Mantel–Cox test), which was considered as significant when the p values were less than 0.05.