



HAL
open science

Virtual imaging for teaching cardiac embryology.

Jean-Marc Schleich, Jean-Louis Dillenseger

► **To cite this version:**

Jean-Marc Schleich, Jean-Louis Dillenseger. Virtual imaging for teaching cardiac embryology.. *Circulation*, 2001, 104 (24), pp.E134. inserm-00130668

HAL Id: inserm-00130668

<https://inserm.hal.science/inserm-00130668v1>

Submitted on 14 Feb 2007

HAL is a multi-disciplinary open access archive for the deposit and dissemination of scientific research documents, whether they are published or not. The documents may come from teaching and research institutions in France or abroad, or from public or private research centers.

L'archive ouverte pluridisciplinaire **HAL**, est destinée au dépôt et à la diffusion de documents scientifiques de niveau recherche, publiés ou non, émanant des établissements d'enseignement et de recherche français ou étrangers, des laboratoires publics ou privés.

This is an un-copyedited author manuscript that was accepted for publication in *Circulation*, copyright The American Heart Association. This may not be duplicated or reproduced, other than for personal use or within the "Fair Use of Copyrighted Materials" (section 107, title 17, U.S. Code) without prior permission of the copyright owner, The American Heart Association. The final copyedited article, which is the version of record, can be found at <http://circ.ahajournals.org/>. The American Heart Association disclaims any responsibility or liability for errors or omissions in this version of the manuscript or in any version derived from it .

Virtual Imaging for Teaching Cardiac Embryology

Jean-Marc Schleich M.D. *, Jean-Louis Dillenseger Ph.D. **

*Département de Cardiologie et Maladies Vasculaires, Hôpital de Pontchaillou, CHR
Rennes, France.

**Laboratoire de Traitement du Signal et de l'Image, Université de Rennes 1, Rennes,
France

key words : Imaging, Computers, Morphogenesis

Corresponding author:

Jean-Marc Schleich, MD

Département de Cardiologie et Maladies Vasculaires,

Hôpital de Pontchaillou,

35033 Rennes CEDEX,

France

Tel: +33 2 99 28 25 17

Fax: +33 2 99 28 25 18

email: jean-marc.schleich@chu-rennes.fr

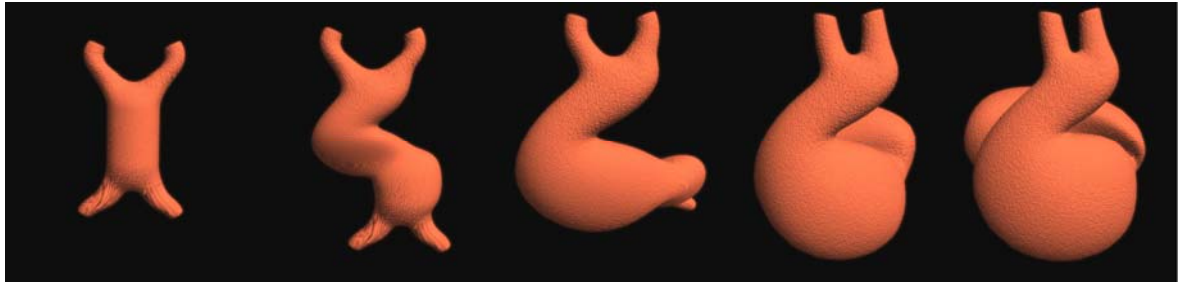
Knowledge of the embryology of the normal heart is essential for understanding the development of congenital cardiopathies. However, learning embryology is not an easy matter because it requires understanding the intricacy and evolution of many complex structures and functions. Classically, this evolution is usually described in textbooks by means of drawings and sketches. With these techniques, however it is difficult to imagine the spatial and temporal links. Recent advances in computer graphics have brought about ways to illustrate these dimensions. We developed a 3-D animation of the full embryogenetic process of the normal heart. A group of cardiac embryology experts composed of cardiologists, paediatrician-cardiologists, and embryologists synthesized the data contained in the main textbooks of embryology. On the basis of the resultant consensus, computer graphics were used to model three-dimensional anatomical structures corresponding to each stage of heart development: fertilization, development of trilaminar germ disc, formation and folding of the primitive heart tube (figure A), morphogenesis of the heart chambers (figure B) and valves (figure C), development of the aorta and the pulmonary artery. These illustrations demonstrate that virtual imaging can significantly improve the understanding of complex systems. It is now possible to understand the normal heart development in fifteen minutes.

Figure legend

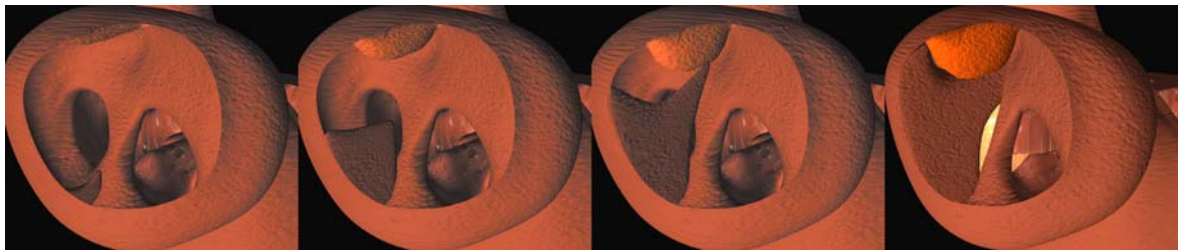
A) From Day 21 to 28. The formation of the cardiac loop where the heart tube is folded into an S-shaped dextro-ventral convexity. B) The partitioning of the atria. The septum primum (in brown) grows from the inferior part of the atria to the top, leaving a foramen called ostium primum. The septum secundum (in orange) comes from the top. The ostium primum will be closed at the end of the fifth week by an expansion of tissue coming from the endocardial cushions (in yellow). C) The partitioning of the conus and the truncus. The dextrodorsal and sinistroventral conus ridges, isolated in the first picture, partition the conus by a helical outgrowth, into two cavities: the subpulmonary and the subaortic conus. The truncus is partitioned from the bottom upward from aortico-pulmonary swellings leading to the formation of the aorta and pulmonary arteries.

Figure

A



B



C

