



Left unilateral neglect as a disconnection syndrome.

Paolo Bartolomeo, Michel Thiebaut de Schotten, Fabrizio Doricchi

► To cite this version:

Paolo Bartolomeo, Michel Thiebaut de Schotten, Fabrizio Doricchi. Left unilateral neglect as a disconnection syndrome.: Disconnection in left neglect. *Cerebral Cortex*, 2007, 17 (11), pp.2479-90. 10.1093/cercor/bhl181 . inserm-00122765

HAL Id: inserm-00122765

<https://inserm.hal.science/inserm-00122765>

Submitted on 13 Feb 2008

HAL is a multi-disciplinary open access archive for the deposit and dissemination of scientific research documents, whether they are published or not. The documents may come from teaching and research institutions in France or abroad, or from public or private research centers.

L'archive ouverte pluridisciplinaire **HAL**, est destinée au dépôt et à la diffusion de documents scientifiques de niveau recherche, publiés ou non, émanant des établissements d'enseignement et de recherche français ou étrangers, des laboratoires publics ou privés.

Left unilateral neglect as a disconnection syndrome

Paolo Bartolomeo¹⁻³, Michel Thiebaut de Schotten^{1,3}, & Fabrizio Doricchi^{4,5}

¹INSERM Unit 610, Hôpital de la Salpêtrière, Paris, France; ²Department of Neurology, AP-HP, Hôpital de la Salpêtrière, Paris, France; ³Université Pierre et Marie Curie-Paris6, Paris, France; ⁴Fondazione Santa Lucia IRCCS, Roma, Italy; ⁵Dipartimento di Psicologia 39, Università degli Studi di Roma "La Sapienza", Roma, Italy

Address correspondence to:

Or to:

Paolo Bartolomeo

Fabrizio Doricchi

INSERM U 610
Pavillon Claude Bernard
Hôpital Salpêtrière
47 bd de l'Hôpital
F-75013 Paris - France
phone +33 (0)1 42 16 00 25 or 58
FAX +33 (0) 1 42 16 41 95
Email: paolo.bartolomeo@chups.inserm.fr
Web: <http://marsicanus.free.fr/>

Centro Ricerche di Neuropsicologia
Fondazione Santa Lucia – IRCCS
Via Ardeatina 306 - 00179 Roma -Italia.
phone: + 39 6 49917929 or + 39 6 51501509
Fax : +39 6 51501366
Email: fabrizio.doricchi@uniroma1.it

Running title: Disconnection in left neglect

Acknowledgements. We thank Francesco Tomaiuolo and Maurizio Corbetta for providing us with details about their anatomical data, Marco Catani for very helpful discussion, Serge Kinkingnéhun and Cyril Poupon for help with neuroimaging processing. The NMR database is the property of CEA SHFJ/UNAF and can be provided on demand to cpoupon@shfj.cea.fr.

Abstract

Unilateral spatial neglect is a disabling neurological condition which typically results from right hemisphere damage. Neglect patients are unable to take into account information coming from the left side of space. The study of neglect is important for understanding the brain mechanisms of spatial cognition, but its anatomical correlates are currently the object of intense debate. We propose a reappraisal of the contribution of disconnection factors to the pathophysiology of neglect based on a review of animal and patient studies, which indicate that damage to the long-range white-matter pathways connecting parietal and frontal areas within the right hemisphere may constitute a crucial antecedent of neglect. Thus, neglect would not result from the dysfunction of a single cortical region, but from the disruption of large networks made up of distant cortical regions. In this perspective, we also re-examined the possible contribution to neglect of inter-hemispheric disconnection. The reviewed evidence, often present in previous studies but frequently overlooked, is consistent with the existence of distributed cortical networks for orienting of attention in the normal brain, has implications for theories of neglect and of normal spatial processing, opens perspectives for research on brain-behavior relationships, and suggests new possibilities for patient diagnosis and rehabilitation.

Keywords: Spatial cognition, Brain lesions, White matter fiber pathways, Attention, Perceptual Disorders

"No wonder Lashley thought the whole brain was involved in mental tasks. It was not the whole brain, but a widely dispersed network of quite localized neural areas"

Michael I. Posner (2005, p. 239)

1. Introduction

Patients with right hemisphere damage often show signs of left unilateral neglect, an inability to take into account information coming from the left side of space (Mesulam 1985; Heilman et al. 1993; Bartolomeo and Chokron 2001; Vallar 2001; Bartolomeo and Chokron 2002; Parton et al. 2004). Neglect patients do not eat from the left part of their dish, they bump with their wheelchair into obstacles situated on their left, when questioned from the left side they may either fail to answer or respond to a right-sided bystander. When presented with bilateral stimuli, they may immediately look towards the rightmost stimulus, as if their attention were “magnetically” attracted (Gainotti et al. 1991). On visuospatial testing, they omit targets on the left in search tasks, deviate rightward when bisecting horizontal lines, and do not copy the left part of drawings. This neurological condition is a significant source of handicap and disability for patients, and entails a poor functional outcome. A better understanding of neglect is thus required both on clinical grounds, for purposes of diagnosis and rehabilitation, and in order to comprehend the brain mechanisms of attention and spatial processing. Unfortunately, however, despite decades of research there are still important disagreements on the interpretation of the neglect syndrome, even on basic matters such as its lesional basis. This question constitutes the specific focus of the present review.

Most studies devoted to the anatomical correlates of neglect indicate the temporal-parietal junction (TPJ) and the inferior parietal lobule (IPL) (Vallar 2001; Mort et al. 2003), consistent with the known role of posterior parietal cortex in spatial attention (Colby and Goldberg 1999; Gitelman et al. 1999; Corbetta and Shulman 2002). In contrast with this view, another line of findings implicated more rostral portions of the superior temporal gyrus

(rSTG) (Karnath et al. 2001; Karnath et al. 2004), emphasizing the role of the ventral visual stream in spatial awareness originally hypothesized by Milner and Goodale (Milner and Goodale 1995). In addition, damage to several other brain structures has been reported to determine neglect, including the thalamus, the basal ganglia and the dorsolateral prefrontal cortex (Vallar 2001; Karnath et al. 2002).

However, at variance with interpretations of neglect stressing the role of damage to local brain modules, it has long been proposed that attentional spatial processes which may be disrupted in neglect do not result from the activity of single brain areas, but rather emerge from the interaction of large-scale networks (Mesulam 1981; Heilman et al. 1993). If so, then damage to the connections making up these networks is expected to impair their integrated functioning, and consequently bring about signs of neglect. Consistent with this prediction, here we review accumulating evidence that long-lasting signs of left unilateral neglect may also result from the important influence of intra- and inter-hemispheric disconnection.

2. Intra-hemispheric disconnection

2.1. Fronto-parietal networks of spatial attention

Within each hemisphere, large-scale cortical networks coordinate the operations of spatial attention (Mesulam 1981; Posner and Petersen 1990; LaBerge 2000; Corbetta and Shulman 2002). Important components of these networks include the dorsolateral prefrontal cortex and the posterior parietal cortex. Physiological studies indicate that these two structures show interdependence of neural activity. During memory-guided saccades, cooling of parietal neurons engenders changes in neural activity in prefrontal neurons, and vice-versa (Chafee and Goldman-Rakic 2000). Not surprisingly, in the monkey, these two structures are directly and extensively interconnected (Selemon and Goldman-Rakic 1988; Morecraft et al. 1993). Several distinct fronto-parietal long-range pathways have been identified (Petrides and

Pandya 2002; Schmahmann and Pandya 2006). These pathways include the arcuate fasciculus (AF), the superior longitudinal fasciculus (SLF) and the fronto-occipital fasciculus (FOF). The AF links the caudal portions of the temporal lobe, at the junction with the parietal lobe, with the dorsal portions of the areas 8, 46 and 6 in the frontal lobe (Schmahmann and Pandya 2006). Within the SLF, three distinct branches can be identified on the basis of cortical terminations and course (Fig. 1) (Petrides and Pandya 2002; Schmahmann and Pandya 2006).

=====

Fig. 1 about here

=====

The SLF I links the superior parietal region and the adjacent medial parietal cortex with the supplementary and premotor areas in the frontal lobe. The SLF II originates in the caudal inferior parietal lobe (corresponding to the human angular gyrus) and the occipito-parietal area and projects to the dorsolateral prefrontal cortex. The SLF III connects the rostral portion of the inferior parietal lobe (homologous to the human supramarginal gyrus) with the ventral premotor area 6, the adjacent area 44, the frontal operculum and area 46. The FOF links the medial preoccipital area PO, the lateral-dorsal occipital area DP, the medial parietal area PGm, the caudal cingulate gyrus and the caudal IPL to the dorsal premotor cortex (area 6) and the dorsal prefrontal cortices (areas 8, 9 and 46)(Schmahmann and Pandya 2006). Rizzolatti and Matelli (Rizzolatti and Matelli 2003) proposed to dissociate the dorsal cortical visual stream (see Mishkin et al. 1983; Milner and Goodale 1995) into two components, a dorso-dorsal stream, which controls actions “on line”, and whose damage leads to optic ataxia, and a ventro-dorsal stream, implicated in space perception and action understanding. In this framework, FOF and SLF II may be considered to connect, respectively, the dorso-dorsal and the ventro-dorsal cortical networks (Schmahmann and Pandya 2006). Although it is not a fronto-parietal pathway, the inferior longitudinal fasciculus (ILF) may also be relevant here,

because its lesion has been implicated in neglect (Leibovitch et al. 1998; Bird et al. 2006). In the monkey, the ILF originates in the ventral-lateral and ventral preoccipital areas, and runs in the depth of the temporal lobe to terminate in the superior temporal sulcus, the inferior temporal gyrus, and other temporal areas; moreover, it connects the caudal part of the cingulate gyrus, the IPL, and the STG to the parahippocampal gyrus (Schmahmann and Pandya 2006).

Diffusion tensor imaging (DTI), a new technique to map the course of white matter tracts in the living human brain (Basser et al. 1994), has demonstrated a similar organization of parietal-frontal pathways in humans (Catani et al. 2002; Makris et al. 2005; Rushworth et al. 2005), although the identification of the cortical terminations remains uncertain due to the technical limitations of the DTI method.

2.2. Fronto-parietal disconnection and spatial neglect

How is visuo-spatial processing affected by damage to these fronto-parietal networks? In a ground-breaking study in the monkey, Gaffan and Hornak (Gaffan and Hornak 1997) showed that severe neglect may arise after a unilateral section of the white matter between the fundus of the intraparietal sulcus and the lateral ventricle, interrupting long-range communication pathways between the parietal and the frontal lobe. When showed several horizontally arranged stimuli, neglect monkeys often omitted to respond to targets contralateral to the lesion, choosing instead an ipsilateral distractor. Interestingly, in this study monkeys demonstrated little, if any, contralateral neglect after isolated ablations of the frontal cortex and of the posterior parietal cortex, or even after a combined lesion of both of these structures. The monkeys with neglect also had clear impairments in everyday activities, such as visual searching for food in free vision in the home cage. When offered two handfuls of food by an observer, they failed to find the food in the observer's hand that was contralateral to the monkey's lesion. This was in marked contrast to the monkeys with hemianopia alone, who had

efficient visual searching which compensated for their hemianopia in free vision (David Gaffan, personal communication, 2006). Thus, disconnection really proved crucial to observe neglect in monkeys in this study (see Burcham et al. 1997; Reep et al. 2004, for analogous results obtained in rodents).

Importantly, analogous findings were reported in different studies in human patients. Using CT scans and SPECT, Leibovitch and co-workers (1998) investigated the anatomical correlates of neglect in a large sample of right brain-damaged patients not selected for the presence or absence of concomitant visual field defects. These authors found that the main correlate of chronic neglect was the combined lesion involvement and hypofunctioning of fibers connecting the parietal and temporal lobes (ILF), as well as those linking the parietal and frontal lobes (SLF), loaded in the white matter beneath the TPJ.

More recently, Doricchi and Tomaiuolo (2003) made a further step and disentangled the contribution of SLF and ILF disconnection to spatial neglect. In their study, lesion overlap was mapped in a sample of chronic neglect patients without visual field defects. Patients were further divided in two subgroups based on whether the lesion involved or spared the basal ganglia. In both subgroups, areas of maximal lesion overlap were found in the SLF beneath the rostral sector of the supramarginal gyrus. This finding revealed that, in humans, damage limited to parietal-frontal connections in the SLF is sufficient to contribute to the development of chronic neglect. The authors concluded that, while “a brain damage affecting circumscribed portions of the IPL could... disrupt only a subset of those different spatial abilities that, with different emphasis and by different authors, are currently considered to be specifically defective in neglect patients, ...disconnection of the parietal–frontal spatial attentional network... might render neglect more persistent by extensively compromising the sensory-to-motor mapping of the contralesional space even in those patients who, suffering only partial damage of the functionally heterogeneous IPL-TPJ area, would otherwise show more

selective (and perhaps transitory) parietal related spatial deficits” (p. 2242).

More compelling and direct evidence stressing the importance of parietal-frontal disconnection in neglect came from a recent study employing intraoperative electrical stimulation in human patients (Thiebaut de Schotten et al. 2005). During brain surgery for resection of low-grade gliomas, neurosurgeons often awaken patients in order to assess the functional role of restricted brain regions, so that the extent of the exeresis can be maximized without provoking cognitive impairments. Patients perform cognitive tasks, such as counting or naming, while the surgeon temporarily inactivates restricted regions around the tumor, using electrical stimuli. If the patient stops talking or produce incorrect responses, the surgeon avoids removing the stimulated region. This technique allows researchers to map cognitive functions in humans with unrivalled spatiotemporal resolution (~5mm by 4sec). Thiebaut de Schotten et al. (2005) asked two patients with gliomas in the right temporo-parietal region to mark the midpoint of 20-cm horizontal lines (a typical neglect task; Azouvi et al. 2002) while being stimulated. Electrical stimulation of the right IPL or of the caudal STG, but not of its more rostral portions, determined rightwards deviations on line bisection.

However, the strongest shifts occurred when one of the patients was stimulated subcortically. Fiber tracking using diffusion tensor imaging identified the stimulated site as the likely human homologue of the SLF II¹, consistent with the postulated role of this pathway in space perception (Rizzolatti and Matelli 2003; Schmahmann and Pandya 2006). Thus, there is a remarkable consistency between the behavioral consequences of fronto-parietal disconnection in humans and in monkeys, despite the fact that different behavioral tests were

¹ In the original article, which was published before the Schmahmann and Pandya atlas became available, the pathway was incorrectly labelled as FOF. This, however, does not hamper the main point made by Thiebaut de Schotten and co-workers, that damage to the fronto-parietal pathways is important to produce neglect.

used: line bisection (Thiebaut de Schotten et al. 2005) or target cancellation (Doricchi and Tomaiuolo 2003) in humans, target search in monkeys (Gaffan and Hornak 1997). This convergence of results strongly suggests a similar organization of space processing mechanisms across the two species. The demonstration of the role of parieto-frontal disconnections in neglect supports models of neglect postulating an impairment of large-scale right-hemisphere networks (Mesulam 1999), including pre-frontal, parietal and cingulate components. The parietal component could determine the perceptual salience of extrapersonal objects, whereas the frontal component might be implicated in the production of an appropriate response to behaviorally relevant stimuli (Mesulam 1999), in the online retention of spatial information (Husain and Rorden 2003), or in the focusing of attention on salient items through reciprocal connections to more posterior regions (Petrides and Pandya 2002). We also note that, as a consequence of parietal-frontal disconnection, inaccurate or slowed communication between posterior and anterior brain regions, whether coupled or not with a general deficit in responding to unattended stimuli, might delay the information transfer from sensory-related areas to response-related regions to the point of exceeding an elapse of time after which this information is no longer useful for affecting behavior (Bartolomeo and Chokron 2002).

2.3. Re-appraisal of previous lesion overlap studies

To explore the consistency of the above reviewed results with previous evidence from vascular patients, we plotted on a standardized brain the subcortical lesions of the stroke patients with neglect from the lesion overlapping studies which contained sufficient details (Doricchi and Tomaiuolo 2003; Mort et al. 2003; Karnath et al. 2004; Corbetta et al. 2005). Long-range connections were visualized using fiber tracking (Thiebaut de Schotten et al. 2006) (see Supplementary Material). Most interestingly, neglect patients' lesions invariably overlapped at or near the subcortical long-range pathways linking the parietal to the frontal

lobes (Fig. 2). The same meta-analysis revealed the presence of an important lesion overlap in the white matter fronto-parietal connections in the study by Karnath et al. (2004). This overlap shows striking resemblance with the lesion overlap documented by Doricchi and Tomaiuolo (2003) in the same area, indicating that in the sample of patients studied by Karnath et al. (2004), lesion overlap in the STG was not selective and that neglect could have been due to parietal-frontal disconnection rather than STG damage.

=====

Fig. 2 about here

=====

2.4. Further evidence on fronto-parietal disconnection in neglect

In a recent group study on 52 right-brain damaged patients with vascular lesions, Committeri et al. (Committeri et al. 2006) investigated the anatomical correlates of personal neglect (i.e. neglect concerning the patient's own body) and extrapersonal neglect (concerning the space external to the patient's body). Committeri et al. concluded that personal neglect is due to lesion involvement of the supra-marginal gyrus in the parietal lobe, whereas extrapersonal neglect results from damage of more ventral areas including the STG and the IFG.

In a first series of comparisons, the authors made voxel-by-voxel subtractions between (a) patients with extrapersonal neglect (whether isolated or in combination with personal neglect) vs. patients with pure personal neglect or no neglect at all; (b) patients with personal neglect (whether isolated or in combination with extrapersonal neglect) vs. patients with pure extrapersonal neglect or no neglect. The results of these subtractions are reported in their Fig. 2. In the first row of axial slices, a distinct area of overlap is clearly present in the white matter of the axial slice Z=+28. We found that this spot is perfectly centered on the SLF on the matching Talairach template, and is only 9mm caudal and 1mm superior to the maximum lesion overlap previously found by Doricchi and Tomaiuolo (Doricchi and Tomaiuolo 2003)

in a group of patients showing extrapersonal neglect on both line bisection and multiple item cancellation tasks (see Supplementary Fig. 2).

In a second series of subtractions, Committeri et al. compared patients with pure extrapersonal neglect or pure personal neglect to patients without neglect. Also in this case, a similar maximum lesion overlap on the SLF was found in patients with pure extrapersonal neglect (see the axial slice $z = +28$ in the third row of their Fig. 2). These anatomical findings went probably unnoticed, because for the quantitative analysis Committeri et al. considered the percentage of white matter damaged within three ample regions of interest: the centrum semiovale, the supralenticular and sublenticular corona radiata, the external and internal capsulae. They found that the white matter immediately dorsal (supralenticular corona radiata and centrum semiovale) and ventral (sublenticular corona radiata) to the insula was significantly more damaged in patients with extrapersonal neglect and that the white matter underlying the supramarginal gyrus was more damaged in patients with personal neglect. However, with respect to a more precise anatomical localisation of these areas, the higher spatial resolution provided by voxel-by-voxel subtractions reported in their figures 2 and 4 is instructive and unequivocal in indicating specific damage of white matter fasciculi linking parietal and frontal areas in patients with extrapersonal neglect. With reference to the distinct branches of the SLF identified in the monkey by Schmahmann and Pandya (2006) (see Fig. 1 and Supplementary Material), we found that the maximum lesion overlap found by Committeri et al. locates itself at the boundary between the likely human homologous of SLF II and SLF III (see Supplementary Fig. 2). Thus, the involvement of dorsal SLF underneath the central sulcus documented by Doricchi and Tomaiuolo (Doricchi and Tomaiuolo 2003) cannot be merely attributed to the presence of concomitant and undetected personal neglect that, as proposed by Committeri et al in the discussion section, would have shifted the lesion overlap dorsally with respect to more ventral areas which, in their proposal, would subserve

awareness of the extrapersonal space.

In a third analysis of their data, Committeri et al. used voxel-based lesion-symptom mapping (VLSM; see Bates et al. 2003). For each voxel, patients were divided into two groups according to whether or not their lesion affected that voxel. Scores for extrapersonal and personal neglect were then compared for these two groups, yielding a *t* statistics for each voxel and corresponding *t*-test based statistical maps for the entire voxel-based brain volume. Also in this case, white matter involvement was present for extrapersonal neglect in fibers feeding the frontal eye field (first row of their Fig. 4, sagittal slice $x = +36$; a more ventral white matter involvement is evident in axial slice $z = +20$), as well as for personal neglect (second row of their Fig. 4, axial slice $z = +32$ and sagittal slice $z = +36$). VLSM analysis also allows researchers to evaluate the similarity between *t*-test based statistical maps by calculating the correlations between *t* scores of personal and extrapersonal neglect for each voxel (Bates et al. 2003). A positive correlation for one voxel suggests that this voxel performs a core function common to both types of deficit (Bates et al. 2003). Committeri et al. obtained a strong positive correlation of 0.84 (reflecting 70% of overlap in the variance) for the IFG (see Husain and Kennard 1996), the posterior insular-opercular temporal-parietal cortex and, most importantly, the white matter underlying the central sulcus (see Doricchi and Tomaiuolo 2003). Therefore, also the VLSM analysis demonstrated that this region of the white matter is implicated in a core function for spatial awareness, as originally suggested by the results of Doricchi and Tomaiuolo (2003) and Thiebaut de Schotten et al. (Thiebaut de Schotten et al. 2005).

In support of this interpretation, another recent VLSM study on 80 stroke patients (Verdon et al. 2006) found that damage to fronto-parietal white matter fibers, which the authors identified with the pathway described by Thiebaut de Schotten et al. (Thiebaut de Schotten et al. 2005), correlated with the presence of generalized and severe neglect.

2.5. Relation to spatial working memory impairment

A cognitive function that could be particularly sensitive to fronto-parietal disconnection is the building up and maintenance of memory for inspected spatial locations. In a series of studies, Husain and his co-workers showed that neglect in cancellation tasks is significantly increased by the failure to remember the location of already cancelled items (Husain et al. 2001). In a study addressing the anatomical correlates of poor spatial working memory (SWM) in neglect patients, Malhotra et al. concluded that "...a deficit in SWM would not be expected in all neglect patients, but it would be anticipated to occur in those who have damage to critical areas in the right parietal and frontal lobe that support SWM performance... lesion locations associated with the poorest SWM performance among neglect patients were *in right parietal white matter* and... the right insula. Damage to both these sites would be consistent with deafferentation and/or loss of cortical regions known to support SWM based on functional neuroimaging evidence" (Malhotra et al. 2005, p. 434, our italics). This conclusion clearly suggests the possibility that a lesion of the white matter can disrupt the whole fronto-parietal network subserving SWM capacities.

2.6. Other intra-hemispheric pathways

A recent anatomical investigation suggests that parietal-frontal disconnection due to middle cerebral artery infarctions might not be the only type of intra-hemispheric disconnection related to neglect. Bird et al. (Bird et al. 2006), showed that in patients with infarctions in the territory of the right posterior cerebral artery, disconnection of white matter fiber tracts between the parahippocampal gyrus and the angular gyrus was correlated with left neglect. Interestingly, the authors also noted that when this type of intrahemispheric disconnection was coupled with lesions of the splenium of the corpus callosum (producing inter-hemispheric disconnection, see section 3 below), neglect tended to be more severe.

2.7. Intra-hemispheric disconnection and neglect: Discussion

2.7.1. Disconnection and cortical de-activation

Despite the abundant evidence reviewed above, an apparent challenge to the role of subcortical disconnection in the pathogenesis of neglect comes from a number of investigations on the correlation between levels of cortical perfusion and presence of neglect in the acute, or hyperacute, post-stroke phase. Using perfusion weighting imaging, based on estimates of arrival and clearance of a bolus of contrast indicating the level of functional activity in otherwise structurally spared cortical areas, Hillis and co-workers (Hillis et al. 2002) investigated the functional correlates of neglect and aphasia due to hyperacute (within 48 hours from stroke) subcortical infarction. They found that, independent of the lesion localization (corona radiata or caudate/capsular structures), neglect was only present in patients who had associated cortical hypoperfusion, and absent in those having no cortical hypoperfusion. Importantly, though only tested in aphasic patients, pharmacological or surgical intervention restoring cortical perfusion led to substantial improvement of cognitive impairments and prevented the development of cortical infarcts. This study shows that a lesion in the white matter does not necessarily cause neglect; however, no precise mapping of white matter lesions was made, thus leaving unexplored the relationship between lesion location and extent, cortical hypoperfusion and neglect. Notwithstanding this limitation, the findings by Hillis and co-workers are relevant in that they confirm that a subcortical disruption of parietal-frontal connections, whether resulting from vascular damage (Hillis et al. 2002; Doricchi and Tomaiuolo 2003), surgical section (Gaffan and Hornak 1997) or temporary/functional lesions (Thiebaut de Schotten et al. 2005), might cause neglect by reducing functional activity in the entire cortical-subcortical parietal frontal network connected by these pathways.

Following the terminology recently proposed by Catani and ffytche (2005), the present

pathophysiological interpretation of the neglect syndrome emphasizes the combined role of *topological* factors, related to dysfunction of cortical specialized areas, and *hodological* factors, related to dysfunction of connecting pathways among the same areas. Furthermore, we propose that disconnection might produce more of a deficit than cortical damage / dysfunction alone through several, not mutually exclusive, mechanisms: (1) Damage to the tightly packed fibers of the white matter may result quantitatively more disrupting than damage to equivalent cortical volumes, by impairing the functioning of larger cortical areas (Fig. 3). (2) Brain networks are composed of cortical modules interacting with each other. Disturbed communication between modules might thus produce not only cortical hypo-functioning, but also hyper- or inadequate functioning of several cortical areas, resulting in a more severe disintegration of complex functions than the deficit relative to lesion to isolated modules (Catani and ffytche 2005) (3) Cortical lesions may leave the possibility for other cortical areas to functionally compensate for the deficit, through phenomena of brain plasticity (see, e.g., Duffau 2005); on the other hand, white matter damage, which provokes the dysfunction of a whole network of connected areas, might render compensation more difficult to obtain.

=====

Fig. 3 about here

=====

It remains to be seen whether fronto-parietal disconnection is sufficient to produce signs of neglect, as suggested by some of the results reviewed here, or whether concomitant cortical damage is necessary. A prediction resulting from the first hypothesis is that patients with relatively pure white matter damage, resulting for example from multiple sclerosis or CADASIL, may show signs of neglect. To the best of our knowledge, in the literature there are only a case report (Graff-Radford and Rizzo 1987) and a group study (Gilad et al. in press)

describing the possible occurrence of left neglect in patients with multiple sclerosis. Together with reports of patients with lesions of vascular origin which affected primarily or exclusively the posterior limb of the right internal capsule (Healton et al. 1982; Ferro and Kertesz 1984; Ferro et al. 1987), this evidence does suggest the possibility of a purely disconnective basis of neglect. The apparently rare occurrence of neglect in diseases selectively affecting the white matter may depend on the frequently bilateral hemispheric involvement in these diseases, which may prevent unilateral neglect to occur (see the discussion on inter-hemispheric interactions in section 3.1. below), but probably also on the relative lack of interest for neglect of clinicians whom these patients are referred to. Signs of neglect may easily pass undetected without proper testing, as confirmed by the substantial lack of neglect literature before the mid-twentieth century. Only a systematic assessment of neglect in patients with selective damage of the white matter can shed light on this issue.

2.7.2. Perspectives for neglect research

The above reviewed evidence suggests that there are at least two long-range pathways linking the parietal to the frontal lobes whose dysfunction could be implicated in neglect (see Fig. 1). As previously mentioned, the inactivation of the SLF II in the right hemisphere causes rightward deviation on line bisection tasks (Thiebaut de Schotten et al. 2005). Lesion of the more ventrally located SLF III in the right hemisphere correlates with rightward deviation on line bisection and left omissions on visual search tasks (Doricchi and Tomaiuolo 2003). While the combined lesion of these pathways might well generally disrupt the right-hemisphere attentional networks (Corbetta et al. 2005), thus giving rise to generalized left neglect, future studies might be able to correlate selective lesions of one of these two pathways with particular patterns of functional deactivation in the cortex and behavioral dissociations in neglect symptoms. For example, the identification of white matter pathway(s) disrupted in a particular patient, and of the cortical areas consequently hypoactive even if undamaged

(Corbetta et al. 2005), might help detailing the anatomical correlates of the many dissociations of performance described in neglect patients (near vs. far, perceptual vs. imaginal, etc.). Until now, the neural correlates of neglect dissociations have proved difficult to assess, perhaps because only grey matter lesions were considered. These considerations might prove important for patient diagnosis because a particular form of disconnection might have greater predictive value than the localization of grey matter lesions concerning the patients' deficits and disabilities. The demonstration of anatomically intact but functionally inactivated areas might also open perspectives for treatments (whether pharmacological or rehabilitative), aimed at restoring normal neural activity in these areas.

2.7.3. Implications for theories of neglect

The role of damage to different sectors of the cerebral networks linking the parietal and frontal lobes in the pathogenesis of unilateral neglect is currently a matter of intense debate. One thesis proposes that the higher frequency, severity and duration of left neglect after right brain damage, compared to right neglect after left brain damage, is due to the different competence of the two hemispheres in dealing with the left and the right side of space. According to this theory the left hemisphere is able to represent only the right hemispace whereas the right hemisphere is endowed with sensory-motor representations of both sides of space. Therefore, the higher frequency of neglect following right hemisphere damage is linked to the limited capacity of the left hemisphere in dealing with the left hemispace; conversely, the lower frequency of neglect after left hemisphere damage depends on the ability of the right hemisphere to deal with the whole horizontal space (Heilman et al. 1993; Mesulam 1999).

A second theory based on neuroimaging studies (Corbetta and Shulman 2002) holds that what is lateralized in the right hemisphere is not the sensory-motor representation of both hemispaces but, rather, a network including the IPL, the posterior part of the STG, and the

inferior and middle frontal gyri and the frontal operculum, especially concerned with the detection of novel unexpected stimuli (such as those appearing at an unexpected spatial location following the presentation of an invalid spatial cue). This right hemisphere network triggers re-orienting of attentional resources in dorsal bilateral networks including the superior parietal lobule and the frontal eye field (Corbetta et al. 2005). At variance with the previous hypothesis, Corbetta and co-workers surmise that each hemisphere is endowed with a dorsal network guiding endogenous orienting in the contralateral space and that the higher frequency of neglect following right hemisphere damage is due to the disruption of the alerting ventral network lateralized in the right hemisphere (Corbetta and Shulman 2002). A precise reconstruction of the section of the SLF damaged by the lesion causing neglect might therefore constitute a crucial test of these two hypotheses. Fronto-parietal disconnection in the right hemisphere may disrupt the function of one or both of these networks, or impair the integrated functioning of the two networks (Doricchi and Tomaiuolo 2003; Mort et al. 2003; Corbetta et al. 2005). For instance, showing that a selective lesion of SLF II, connecting the dorsal network, is sufficient to produce neglect signs, would favor the first hypothesis, whereas linking neglect to a selective damage to the SLF III or the AF, connecting the ventral network, would be consistent with the Corbetta and co-workers' theory.

However, more complex anatomical-functional scenarios, consistent with the heterogeneity of the neglect syndrome can be envisaged. For example, selective lesions of the different sectors of the SLF could be associated with different types of neglect, or the presence of different neglect signs (e.g. behavioral dissociations in the performance of different tasks as, for example, line bisection vs. multiple item cancellation). We strongly argue that such a differential approach to the study of neglect syndrome could be by far more fruitful, both from clinical and theoretical standpoints, than trying to attribute neglect to the main influence of disruption of a single anatomical-functional brain module.

3. Inter-hemispheric interactions and disconnection

3.1. *Neglect, orienting of attention and inter-hemispheric*

interactions: callosal or collicular?

Patients with left neglect typically show an asymmetry of attentional orienting, whereby orienting to right-sided objects is easier and faster than orienting to left-sided objects (see Bartolomeo and Chokron 2002 for review). Thus, it has been suggested that left neglect essentially results from a rightward attentional bias (Kinsbourne 1970), from a deficit in disengaging attention from the right side to re-orient it to the left side (Posner et al. 1984; Morrow and Ratcliff 1988), or from a deficit in orienting attention to the left contralesional hemispace (Heilman and Valenstein 1979). A well-articulated account of neglect based on orienting of attention is the opponent processor model (Kinsbourne 1970; 1977; 1987; 1993). According to this hypothesis, each hemisphere shifts attention toward the contralateral hemispace by inhibiting the other hemisphere. Moreover, in the normal brain there is a tendency to rightward orienting supported by the left hemisphere, which has a stronger orienting tendency than the right hemisphere. Right hemisphere lesions, by disinhibiting the left hemisphere, exaggerate this physiological rightward bias, thus giving rise to left neglect. Left neglect does not reflect an attentional deficit, but an attentional bias consisting of enhanced attention towards the right. The verbal interaction between patient and examiner would further enhance left neglect by further activating the already disinhibited left-hemisphere. Furthermore, left neglect patients would suffer from an abnormally tight focus of attention, which would deprive them of the possibility of a more general overview of the visual scene (Kinsbourne 1993). Right neglect would rarely be observed because much larger lesions of the left hemisphere are needed to overcome its stronger tendency to rightward orienting, and because the verbal exchanges with the examiner would now work in the

opposite direction, activating the left hemisphere and minimizing right neglect. Evidence supporting the opponent processor model came from the pioneering report of a patient who showed a severe left neglect following a first right-sided parietal infarct, but abruptly recovered from neglect ten days later, when he suffered from a second infarct in the dorsolateral frontal cortex of the left hemisphere (Vuilleumier et al. 1996). However, conclusive anatomical inferences from this case report seem not easy, because the patient was studied in the acute phase of the disease, when transient phenomena of neural depression in areas remote from the lesion can occur (diaschisis; Meyer et al. 1993). As noted by the authors, the second stroke induced a tonic leftward deviation of head and gaze: this occurrence might have contributed to minimizing left neglect signs, similarly to the effects of vestibular or optokinetic stimulations (see Gainotti 1993; Vallar et al. 1997; Chokron and Bartolomeo 1999).

According to the opponent processing model, increasing severity of neglect should result from an increasingly stronger bias toward the right, reflecting increasing disinhibition of the left hemisphere. Thus, response times to right-sided targets should become progressively faster as neglect increases in severity across patients. Contrary to this prediction, a group study of patients with varying degrees of neglect on paper-and-pencil tests demonstrated that not only patients' response times to left targets, but also those to right targets increased with increasing neglect (Bartolomeo and Chokron 1999a). However, the two regression lines were not parallel. With increasing neglect, responses to left targets increased more steeply than those to right targets did. Thus, a rightward attentional bias is present in patients with left neglect, together with left hypoattention. However, the rightward bias is one of defective, and not enhanced, attention.

Full understanding of the interactions between the opponent processors in the two hemispheres requires the identification of neural mechanisms and pathways mediating such

interactions. Mutually inhibitory inter-hemispheric interactions would intuitively appear to implicate the callosal connections; however, also the superior colliculi (SC), which mutually inhibit one another, are plausible candidates (Kinsbourne 1987). In the cat, lesion of one SC produces contralateral neglect, which can be reversed by lesion to the contralateral SC or by section of the intertectal commissure (Sprague 1966).

A more recent study (Rushmore et al. 2006) showed that ablation or cooling of the posterior parietal cortex induced contralateral neglect, which corresponded to decreased metabolic activity (as measured by 2-deoxyglucose uptake) of the ipsilateral SC and increased activity of the contralateral SC, but not of the contralateral parietal cortex; cooling of the opposite parietal cortex or SC restored orienting reactions to the previously neglected stimuli; correspondingly, collicular activity reverted to symmetry.

Weddell (Weddell 2004) reported a possible human analogue of the Sprague effect (see also Zihl and von Cramon 1979). In a patient with a midbrain tumour, right frontal damage resulting from a surgical procedure provoked signs of left neglect, which disappeared abruptly seven months later, when the tumour extended into the left SC. Most of the retinal afferents to the SC come from the contralateral eye. Thus, patching the right eye should decrease the visual input to the left SC, thereby decreasing its inhibition on the right SC. Consistent with the collicular hypothesis, neglect patients were found to show some improvement during the period when the patch was worn (Butter and Kirsch 1992). However, another study, contrasting monocular eye-patching with patching of the two right visual hemifields, which decreases the visual input to the left hemisphere, found an improvement of neglect only in the hemifield patching group (Beis et al. 1999). Thus, a cortico-subcortical system including both cortical and subcortical systems (respectively, the fronto-parietal regions and the SC) might constitute the neural basis for the opponent processor model.

Also relevant for the opponent processor model are the results from TMS and fMRI studies in humans. Oliveri et al. (Oliveri et al. 1999), studied the effects of temporary inactivation by TMS of parietal and frontal sites in the intact hemisphere upon contralateral tactile extinction to bilateral simultaneous in right and left brain-damaged patients. In right brain-damaged patients, TMS over the intact left frontal site significantly reduced extinction as compared with controls, whereas the same effect was not observed upon stimulation of the homologous site in the intact right hemisphere of left brain damaged patients. These results are in keeping with the idea that TMS reduces inhibition from the stimulated to the unstimulated hemisphere and that mutual inhibition between the two hemispheres is asymmetrical, with more prominent inhibition directed from the left to the right hemisphere. Without excluding the possible contribution of subcortical mechanisms, the authors argued that TMS effects on extinction of tactile digit stimuli could have been well mediated by callosal fibers connecting “hand representations of associative parietal and frontal areas” as these connections “are more powerful and widespread than those between the primary hand motor and sensory areas” (p. 1737). As far as tactile modality is concerned, the authors further argued that this callosal mechanism might be particularly plausible because subcortical mechanisms as the Sprague effect “seem to be valid especially for the visual system” (p. 1737).

A recent fMRI investigation (Corbetta et al. 2005) explored eleven stroke patients with left neglect who, in keeping with previous overlap studies (Doricchi and Tomaiuolo 2003; Mort et al. 2003), showed a maximal lesion overlap in the white matter beneath the IPL (see their Fig. 2 and the present Fig. 2). Four weeks after the stroke, when performing a response time task to lateralized stimuli, neglect patients had decreased activation of structurally intact fronto-parietal regions in the right hemisphere (especially the intraparietal sulcus, the superior parietal lobule and the dorsolateral prefrontal cortex), coupled with robust activation of the

homologous regions in the left hemisphere. Thirty-nine weeks after lesion onset, recovery of neglect signs was paralleled by the disappearance of the imbalance between the two superior parietal lobules. According to the authors, this pattern of results suggests that lesions of the right temporo-parietal junction determine a functional imbalance of the superior parietal lobules, which are structures important to attentional orienting. Consistent with the many previous findings and interpretations of neglect summarized in the present review, Corbetta et al. concluded that their results “rule out the possibility that neglect results from the critical dysfunction of one brain area” (p. 1608).

In conclusion, the reviewed evidence indicates that insight in the anatomical basis of the dynamic interplay between homologous structures in the two halves of the brain is of importance for the diagnosis and treatment of neglect and for the understanding of the mechanisms of spontaneous recovery or of relevant clinical changes during the transition from the acute to the post-acute and chronic phase.

3.2. Confabulations and implicit processing

Four decades ago, in his seminal review of disconnection syndromes, Geschwind (Geschwind 1965) suggested that some neglect signs reflected the activity of the left hemisphere being deprived of information from the right hemisphere. In Geschwind's view, the left hemisphere is dominant not only for language, but for cognition in general; thus, if the right visual and somesthetic cortex are isolated from the left hemisphere, “[t]he left side of the body and of space is then ‘lost’ . The patient will then respond in many instances by using [a] technique of confabulatory completion” (p. 600). These confabulatory responses would be the result of an isolated left hemisphere, with no access to the left-sided information processed by the right hemisphere. In other words, inter-hemispheric disconnection would produce a deafferentation of the left hemisphere, degrading the information coming from the left part of space, processed by the right hemisphere. To address the “vexing problem of why a left parietal

lesion less often produces neglect of half space than does a right parietal lesion” (p. 601), Geschwind further proposed that “disease may simply aggravate the normal disadvantage of the right hemisphere in being further away and responding less well to stimuli” (p. 601), thus anticipating the above reviewed hypothesis later developed by Kinsbourne (see section 3.1. above).

Although the idea of a generally dominant left hemisphere is no longer accepted, other aspects of Geschwind’s proposal might help interpreting patterns of performance later described in split-brain patients and in neglect patients. Following surgical section of the corpus callosum, it has been reported that the left hemisphere sometime provides *post-hoc* confabulatory verbal explanations of actions performed by the right hemisphere (Gazzaniga and Baynes 2000). In a well-known example (see Gazzaniga and Baynes 2000), a split-brain patient was shown tachistoscopically the pictures of a snow scene in the left visual field/right hemisphere and of a rooster claw in the right field/left hemisphere. When the patient was presented with multiple pictures and asked to use each hand to choose those matching the bilateral displays, his right hand chose the picture of a rooster, and his left hand, driven by the right hemisphere, appropriately chose a shovel as a match for the snow scene. At debriefing, however, the patient, whose left hemisphere had not seen the snow scene, confabulated that the shovel was needed to clean out the chicken house.

Right brain-damaged patients with left-sided extinction or neglect may show remarkable implicit processing without overt verbal recognition of stimuli tachistoscopically presented in the left hemifield. Patients can perform better than chance when forced to make same / different judgments or select in a multiple choice the identity of a non-explicitly detected item (Volpe et al. 1979), and can show implicit semantic processing of the stimulus presented in the neglected hemifield (McGlinchey-Berroth et al. 1993; Berti et al. 1994), although only a minority of neglect patients may show such effects (D’Erme et al. 1993). One

may also wonder whether any inter-hemispheric disconnection factors may contribute to the implicit processing and the confabulations concerning the neglected left side of visual stimuli presented in free vision. For example, in an often-cited case report (Marshall and Halligan 1988), patient P.S. was unable to tell the difference between two vertically arranged houses, one of which had its left side on fire. However, when asked in which of the two she would live, P.S. consistently chose the house that was not burning. In Geschwind's view, this behavior could be accounted for by postulating (1) an inability of the left hemisphere to access left-sided information (the fire), with consequent lack of verbal acknowledgment of the difference between the two houses; (2) some residual (right-hemisphere-based?) knowledge of this difference, either (a) resulting in the appropriate behavioral choice, or (b) causing misinterpretation of the difference and resulting in a choice consistent with the misinterpretation. A further prediction coming from this hypothesis is that, if patients are asked *why* they prefer the non-burning house, their left hemisphere should either admit ignorance or produce confabulatory responses. In the case of P.S., no comments about her choices are available, except that she deemed "silly" the task of choosing between two "identical" houses. However, other studies provide this information, and report a variety of responses at debriefing. For instance, a patient described by Manning and Kartsounis (1993) chose the non-burning house stating that it had an extra fireplace, consistent with Geschwind's hypothesis. Another patient described by Bisiach and Rusconi (1990) consistently chose the *burning* house, considering it more "spacious" on the burning side, where the contour of the flames actually enlarged the shape of the house, an example of choice based on an implicit misinterpretation of the difference. In a group of thirteen neglect patients (Doricchi et al. 1997), responses motivating correct implicit choices of the "non-burning house" were equally distributed in two categories: (a) "there is no specific reason for my choice, the two houses are the same anyway", suggesting complete uncoupling of verbal

output from implicit processing; (b) “the house I chose is ‘better’, ‘bigger’, or ‘works better’”, suggesting, in this case, approximation of verbal output to implicit processing. Unfortunately, hypotheses on the functional and anatomical basis of the different examples of dissociation between explicit and implicit processing remain highly speculative, because no related empirical evidence is currently available. Geschwind’s proposal of confabulatory responses resulting from an isolated left hemisphere indicates, however, possible ways to afford this fascinating puzzle.

3.3. Extinction

An important clinical phenomenon that has been interpreted in terms of inter-hemispheric disconnection is extinction after unilateral brain damage. Extinction refers to the failure of verbally reporting the most contralesional of a pair of simultaneous stimuli while maintaining an intact or largely preserved ability of reporting the same contralesional stimulus when presented alone. Extinction can occur both within and between different sensory modalities. It is often clinically detected in the recovery phase of neglect, though it can doubly dissociate from it. Marzi and co-workers (Smania et al. 1996) argued that right brain-damaged patients with extinction might suffer a partial interhemispheric disconnection syndrome “whereby the information on the stimulus presented to the damaged right hemisphere cannot be efficiently integrated with that available to the left hemisphere” subserving the verbal response or mastering the task of deciding about the number of stimuli presented (“one” or “two”). These authors studied a right brain-damaged patient in whom disruption of interhemispheric transfer of visual information was demonstrated by recording of evoked potentials (Smania et al. 1996). In this patient, extinction of contralesional visual stimuli on double simultaneous presentation dropped dramatically when, instead of a verbal response (saying “two”), a motor response with no preferential triggering by one hemisphere (e.g. moving the eyes upward) or a response requiring bilateral muscular control (e.g. lowering the chin) was required to report

double stimuli. According to the authors, when two stimuli are simultaneously presented to a right brain-damaged patient, the one perceived directly by the intact left hemisphere (dominating the verbal response) has stronger central representation, thus masking the weaker callosal input coming from the damaged hemisphere. In case of unilateral presentation to the damaged right hemisphere, the same callosal input triggers normal verbal recognition because no other stimulus competes for response in the left hemisphere. Impaired verbal report of stimuli arriving at the right hemisphere when simultaneously presented with stimuli to the left hemisphere was documented in a split brain patient (Reuter-Lorenz et al. 1995). In line with the hypothesis that weak or impaired access to the responding hemisphere can modulate extinction and neglect phenomena, Corballis and co-workers recently described a callosotomized patient showing striking neglect for stimuli presented to the right hemisphere when these had to be reported verbally (i.e. by the left hemisphere) (Corballis et al. 2005). Neglect, however, disappeared when non-verbal responses were required and the report was no more under the control of the left hemisphere. Thus, callosal damage might contribute, at least in some cases, to the appearance of split-brain-like confabulations or extinction of stimuli presented to the damaged hemisphere.

3.4. Anatomical evidence supporting the influence of inter-hemispheric disconnection on neglect

From an anatomical standpoint, the hypothesis of a contribution of interhemispheric disconnection to some of the behavioral features characterizing neglect has received empirical support from studies in animals and humans. Watson and co-workers (Watson et al. 1984) found that on several behavioral measures (i.e. responses to auditory, visual and somesthetic stimuli, circling behavior and asymmetric orienting), post-operative neglect was more severe in monkeys who underwent callosotomy prior to ablation of the frontal arcuate gyrus as compared with monkeys who underwent only equivalent cortical ablation. Gaffan and Hornak

(Gaffan and Hornak 1997) showed that monkeys with combined resection of the right optic tract (causing complete left hemianopia) and of the corpus callosum (causing complete interhemispheric forebrain disconnection) showed more severe neglect than monkeys undergoing section of fronto-parietal connections (also causing substantial neglect, see section 2.2. above), or resection of the parietal and/or prefrontal cortex (causing very mild and transitory neglect). The authors argued that severe neglect in monkeys with combined optic tract – callosal disconnection depended on the impossibility of the intact attentional fronto-parietal system of the blind hemisphere to receive visual information gathered by the seeing hemisphere and to build up an adaptive compensatory mnemonic representation of the space contralateral to the blind hemisphere. In keeping with Gaffan and Hornak's proposal, the defective integration of visual input from the intact left hemisphere with damaged mechanisms of space representation in the right hemisphere appears to produce erroneous compensation of the visual field defect in patients with neglect and concomitant hemianopia. This is revealed by horizontal distance reproduction tasks forcing patients to set distance endpoints toward the attended or the otherwise spontaneously unattended hemispace (Bisiach et al. 1996; Doricchi and Angelelli 1999; Nico et al. 1999; Doricchi et al. 2005). In these tasks, the combination of neglect and hemianopia leads to marked and paradoxical hypometric distance reproductions in the ipsilesional direction (probably as a consequence of saccadic undershooting made in order to keep the endpoint from falling into the blind hemifield) and hypermetric responses in the contralesional direction (as a consequence of saccadic overshooting made to shift the blind hemifield away and bring the endpoint position into the seeing hemifield moving contralesionally; Ishiai 2002). Also in keeping with Gaffan and Hornak's findings, the greater severity of neglect symptoms in patients with concomitant neglect and hemianopia, as compared with those with neglect unaccompanied by hemianopia, is well documented by studies from several laboratories and can be particularly evident in

tasks requiring parallel processing of stimuli extending along the horizontal space such as, for example, the line bisection task (D'Erme et al. 1987; Binder et al. 1992; Harvey et al. 1995; Bartolomeo and Chokron 1999b; Harvey and Milner 1999; Doricchi et al. 2005).

Results analogous to those obtained by Gaffan and Hornak with hemianopic-callosotomized monkeys were recently reported in human patients by Park et al. (Park et al. 2006), who found that among "...the various combinations of occipital plus adjacent lesions, only occipital injury together with complete injury to the splenium of the corpus callosum significantly contributed to the frequency and severity" of spatial neglect (p. 60). Park et al. further observed that, in their group of patients with unilateral damage in the territory of the posterior cerebral artery, visual field defects *per se* did not predict the severity of neglect. We notice, however, that the absence of a significant correlation between hemianopia and severity of neglect only reconfirms the well-established double dissociation between visual neglect and hemianopia (McFie et al. 1950; Gainotti 1968), and is not surprising to be found in a group of unselected right brain damaged patients. In such an unselected group including hemianopic patients both with and without neglect, the compensatory leftwards attentional bias of pure hemianopic patients (Fuchs 1920; D'Erme et al. 1987; Barton and Black 1998) will tend to cancel out the relationship between presence of hemianopia and severity of neglect that is observed when only patients with neglect are considered (D'Erme et al. 1987; Halligan et al. 1990; Gaffan and Hornak 1997; Doricchi and Angelelli 1999)

Finally, it is worth emphasizing that in patients with neglect, the influence of inter-hemispheric disconnection might be at work independently from the presence of concomitant visual field defect. Kashiwagi et al (1990) described a patient who demonstrated left neglect signs after callosal infarction, with MRI showing no lesion in the right hemisphere. This patient had neglect when performing paper-and-pencil tasks with his right hand, but not when using his left hand (see also the already mentioned study by Corballis et al. 2005). More

recently, the above reviewed lesion overlapping study by Doricchi and Tomaiuolo (Doricchi and Tomaiuolo 2003) found that damage to callosal radiation can be a lesional correlate of chronic neglect unaccompanied by hemianopia.

In conclusion, though inter-hemispheric disconnection might not to be a sufficient cause of neglect *per se*, as also suggested by the fact that split-brain patients do not systematically show signs of left neglect (Plourde and Sperry 1984; Gazzaniga and Baynes 2000), it could still explain some neglect-related phenomena. In this sense, the confabulations produced by split-brain patients and those generated by neglect patients might have at least partially superimposed functional causes, with the left hemisphere being totally deprived of right hemisphere processing in the first case, or being provided with incompletely processed right-hemisphere information in the second case.

4. Conclusion

A wealth of data from cognitive neurosciences indicates that the brain is a mosaic of functionally interconnected areas. The anatomical basis of these functional links begins now to be explored in detail (Mesulam 2005). Recent developments in neuroimaging techniques, such as diffusion tensor imaging and fiber tracking techniques, permit to map *in vivo* the white matter pathways, both in normal individuals (Catani et al. 2002) and in neurological patients (Thiebaut de Schotten et al. 2005). These new and exciting developments are likely to change our way of looking at brain-behavior relationships, for example by giving the possibility of directly testing the disconnection hypotheses put forward by Geschwind 40 years ago (Geschwind 1965; Catani and ffytche 2005), and more specifically the inter-hemispheric disconnection hypothesis of neglect, as well as the fronto-parietal disconnection hypothesis reviewed here. Full consideration of the pathways of communication between functional regions of the brain will help avoid the risk of interpreting in a localist,

“phrenological” way, patterns of performance which reflect instead the complexity of multiple, highly interactive processes.

References

- Azouvi P, Samuel C, Louis-Dreyfus A, Bernati T, Bartolomeo P, Beis J-M, Chokron S, Leclercq M, Marchal F, Martin Y and others. 2002. Sensitivity of clinical and behavioural tests of spatial neglect after right hemisphere stroke. *Journal of Neurology, Neurosurgery and Psychiatry* 73(2):160-166.
- Bartolomeo P, Chokron S. 1999a. Left unilateral neglect or right hyperattention? *Neurology* 53(9):2023-2027.
- Bartolomeo P, Chokron S. 1999b. Egocentric frame of reference: Its role in spatial bias after right hemisphere lesions. *Neuropsychologia* 37(8):881-894.
- Bartolomeo P, Chokron S. 2001. Levels of impairment in unilateral neglect. In: Boller F, Grafman J, editors. *Handbook of Neuropsychology*. 2nd ed. Amsterdam: Elsevier Science Publishers. p 67-98.
- Bartolomeo P, Chokron S. 2002. Orienting of attention in left unilateral neglect. *Neuroscience and Biobehavioral Reviews* 26(2):217-234.
- Barton JJ, Black SE. 1998. Line bisection in hemianopia. *Journal of Neurology, Neurosurgery and Psychiatry* 64(5):660-2.
- Basser PJ, Mattiello J, LeBihan D. 1994. Estimation of the effective self-diffusion tensor from the NMR spin echo. *Journal of Magnetic Resonance, Series B* 103(3):247-54.
- Bates E, Wilson SM, Saygin AP, Dick F, Sereno MI, Knight RT, Dronkers NF. 2003. Voxel-based lesion-symptom mapping. *Nature Neuroscience* 6(5):448-50.
- Beis J-M, Andre J-M, Baumgarten A, Challier B. 1999. Eye patching in unilateral spatial neglect: Efficacy of two methods. *Archives of Physical Medicine and Rehabilitation* 80(1):71-76.
- Berti A, Frassinetti F, Umiltà C. 1994. Nonconscious reading? Evidence from neglect dyslexia. *Cortex* 30:181-197.
- Binder J, Marshall R, Lazar R, Benjamin J, Mohr JP. 1992. Distinct syndromes of hemineglect. *Archives of Neurology* 49(11):1187-1194.
- Bird CM, Malhotra P, Parton A, Coulthard E, Rushworth MF, Husain M. 2006. Visual neglect following right posterior cerebral artery infarction. *Journal of Neurology, Neurosurgery and Psychiatry*.
- Bisiach E, Rusconi ML. 1990. Break-down of perceptual awareness in unilateral neglect. *Cortex* 26(4):643-649.
- Bisiach E, Pizzamiglio L, Nico D, Antonucci G. 1996. Beyond unilateral neglect. *Brain* 119:851-857.
- Burcham KJ, Corwin JV, Stoll ML, Reep RL. 1997. Disconnection of medial agranular and posterior parietal cortex produces multimodal neglect in rats. *Behavioral Brain Research* 86(1):41-47.
- Butter CM, Kirsch N. 1992. Combined and separate effects of eye patching and visual stimulation on unilateral neglect following stroke. *Archives of Physical Medicine and Rehabilitation* 73(12):1133-1139.
- Catani M, Howard RJ, Pajevic S, Jones DK. 2002. Virtual in vivo interactive dissection of white matter fasciculi in the human brain. *Neuroimage* 17(1):77-94.
- Catani M, ffytche DH. 2005. The rises and falls of disconnection syndromes. *Brain* 128(Pt 10):2224-2239.
- Chafee MV, Goldman-Rakic PS. 2000. Inactivation of parietal and prefrontal cortex reveals interdependence of neural activity during memory-guided saccades. *Journal of Neurophysiology* 83(3):1550-1566.

- Chokron S, Bartolomeo P. 1999. Réduire expérimentalement la négligence spatiale unilatérale: revue de la littérature et implications théoriques. *Revue de Neuropsychologie* 9(2-3):129-165.
- Colby CL, Goldberg ME. 1999. Space and attention in parietal cortex. *Annual Review in Neurosciences* 22:319-349.
- Committeri G, Pitzalis S, Galati G, Patria F, Pelle G, Sabatini U, Castriota-Scanderbeg A, Piccardi L, Guariglia C, Pizzamiglio L. 2006. Neural bases of personal and extrapersonal neglect in humans. *Brain* in press.
- Corballis MC, Corballis PM, Fabri M, Paggi A, Manzoni T. 2005. Now you see it, now you don't: Variable hemineglect in a commissurotomed man. *Cognitive Brain Research* 25(2):521-530.
- Corbetta M, Shulman GL. 2002. Control of goal-directed and stimulus-driven attention in the brain. *Nature Reviews Neuroscience* 3(3):201-215.
- Corbetta M, Kincade MJ, Lewis C, Snyder AZ, Sapir A. 2005. Neural basis and recovery of spatial attention deficits in spatial neglect. *Nature Neuroscience* 8(11):1603-1610.
- D'Erme P, De Bonis C, Gainotti G. 1987. Influenza dell'emi-inattenzione e dell'emianopsia sui compiti di bisezione di linee nei pazienti cerebrolesi [Influence of unilateral neglect and hemianopia on line bisection performance in brain-damaged patients]. *Archivio di Psicologia, Neurologia e Psichiatria* 48:165-189.
- D'Erme P, Robertson IH, Bartolomeo P, Daniele A. 1993. Unilateral neglect: The fate of the extinguished visual stimuli. *Behavioural Neurology* 6:143-150.
- Doricchi F, Incoccia C, Galati G. 1997. Influence of figure-ground contrast on the implicit and explicit processing of line drawings in patients with left unilateral neglect. *Cognitive Neuropsychology* 14:573-594.
- Doricchi F, Angelelli P. 1999. Misrepresentation of horizontal space in left unilateral neglect: role of hemianopia. *Neurology* 52(9):1845-1852.
- Doricchi F, Tomaiuolo F. 2003. The anatomy of neglect without hemianopia: a key role for parietal-frontal disconnection? *NeuroReport* 14(17):2239-2243.
- Doricchi F, Guariglia P, Figliozzi F, Silvetti M, Bruno G, Gasparini M. 2005. Causes of cross-over in unilateral neglect: between-group comparisons, within-patient dissociations and eye movements. *Brain* 128(Pt 6):1386-1406.
- Duffau H. 2005. Lessons from brain mapping in surgery for low-grade glioma: insights into associations between tumour and brain plasticity. *Lancet Neurology* 4(8):476-86.
- Ferro JM, Kertesz A. 1984. Posterior internal capsule infarction associated with neglect. *Archives of Neurology* 41(4):422-424.
- Ferro JM, Kertesz A, Black SE. 1987. Subcortical neglect: quantitation, anatomy, and recovery. *Neurology* 37(9):1487-1492.
- Fuchs W. 1920. Untersuchung über das Sehen der Hemianopiker und Hemiamblyopiker. *Zeitschrift für Psychologie und Physiologie der Sinnersorganen* 84:67-169.
- Gaffan D, Hornak J. 1997. Visual neglect in the monkey. Representation and disconnection. *Brain* 120(Pt 9):1647-1657.
- Gainotti G. 1968. Les manifestations de négligence et d'inattention pour l'hémi-espace. *Cortex* 4:64-91.
- Gainotti G, D'Erme P, Bartolomeo P. 1991. Early orientation of attention toward the half space ipsilateral to the lesion in patients with unilateral brain damage. *Journal of Neurology, Neurosurgery and Psychiatry* 54:1082-1089.
- Gainotti G. 1993. The role of spontaneous eye movements in orienting attention and in unilateral neglect. In: Robertson IH, Marshall JC, editors. *Unilateral Neglect: Clinical and Experimental Studies*. Hove (UK): Lawrence Erlbaum Associates. p 107-122.

- Gazzaniga MS, Baynes K. 2000. Consciousness, introspection, and the split-brain: The two minds/one body problem. In: Gazzaniga MS, editor. *The New Cognitive Neurosciences*. Cambridge, Mass.: MIT Press. p 1355-1363.
- Geschwind N. 1965. Disconnexion syndromes in animals and man - Part II. *Brain* 88:585-644.
- Gilad R, Sadeh M, Boaz M, Lampl Y. in press. Visual spatial neglect in multiple sclerosis. *Cortex*.
- Gitelman DR, Nobre AC, Parrish TB, LaBar KS, Kim Y-H, Meyer JR, Mesulam MM. 1999. A large-scale distributed network for covert spatial attention: Further anatomical delineation based on stringent behavioural and cognitive controls. *Brain* 122(6):1093-1106.
- Graff-Radford NR, Rizzo M. 1987. Neglect in a patient with multiple sclerosis. *European Neurology* 26(2):100-103.
- Halligan PW, Marshall JC, Wade DT. 1990. Do visual field deficits exacerbate visuo-spatial neglect? *Journal of Neurology, Neurosurgery and Psychiatry* 53(6):487-491.
- Harvey M, Milner AD, Roberts RC. 1995. An investigation of hemispatial neglect using the landmark task. *Brain and Cognition* 27:59-78.
- Harvey M, Milner AD. 1999. Residual perceptual distortion in 'recovered' hemispatial neglect. *Neuropsychologia* 37(6):745-750.
- Healton EB, Navarro C, Bressman S, Brust JC. 1982. Subcortical neglect. *Neurology* 32(7):776-778.
- Heilman KM, Valenstein E. 1979. Mechanisms underlying hemispatial neglect. *Annals of Neurology* 5:166-170.
- Heilman KM, Watson RT, Valenstein E. 1993. Neglect and related disorders. In: Heilman KM, Valenstein E, editors. *Clinical Neuropsychology*. 3rd ed. New York: Oxford University Press. p 279-336.
- Hillis AE, Wityk RJ, Barker PB, Beauchamp NJ, Gailloud P, Murphy K, Cooper O, Metter EJ. 2002. Subcortical aphasia and neglect in acute stroke: the role of cortical hypoperfusion. *Brain* 125(Pt 5):1094-1104.
- Husain M, Kennard C. 1996. Visual neglect associated with frontal lobe infarction. *Journal of Neurology* 243(9):652-657.
- Husain M, Mannan S, Hodgson T, Wojciulik E, Driver J, Kennard C. 2001. Impaired spatial working memory across saccades contributes to abnormal search in parietal neglect. *Brain* 124(Pt 5):941-52.
- Husain M, Rorden C. 2003. Non-spatially lateralized mechanisms in hemispatial neglect. *Nature Reviews Neuroscience* 4(1):26-36.
- Ishiai S. 2002. Perceptual and motor interaction in unilateral spatial neglect. In: Karnath HO, Milner D, Vallar G, editors. *The Cognitive and Neural Bases of Spatial Neglect*. Oxford: Oxford University Press. p 181-193.
- Karnath H-O, Ferber S, Himmelbach M. 2001. Spatial awareness is a function of the temporal not the posterior parietal lobe. *Nature* 411(6840):950-963.
- Karnath H-O, Himmelbach M, Rorden C. 2002. The subcortical anatomy of human spatial neglect: putamen, caudate nucleus and pulvinar. *Brain* 125(2):350-360.
- Karnath H-O, Fruhmann Berger M, Kuker W, Rorden C. 2004. The anatomy of spatial neglect based on voxelwise statistical analysis: a study of 140 patients. *Cerebral Cortex* 14(10):1164-1172.
- Kashiwagi A, Kashiwagi T, Nishikawa T, Tanabe H, Okuda J. 1990. Hemispatial neglect in a patient with callosal infarction. *Brain* 113(Pt 4):1005-1023.
- Kinsbourne M. 1970. A model for the mechanism of unilateral neglect of space. *Transactions of the American Neurological Association* 95:143-6.

- Kinsbourne M. 1977. Hemi-neglect and hemisphere rivalry. In: Weinstein EA, Friedland RP, editors. *Hemi-Inattention and Hemisphere Specialization*. New York: Raven Press. p 41-49.
- Kinsbourne M. 1987. Mechanisms of unilateral neglect. In: Jeannerod M, editor. *Neurophysiological and Neuropsychological Aspects of Spatial Neglect*. Amsterdam: Elsevier Science Publishers. p 69-86.
- Kinsbourne M. 1993. Orientational bias model of unilateral neglect: Evidence from attentional gradients within hemispace. In: Robertson IH, Marshall JC, editors. *Unilateral Neglect: Clinical and Experimental Studies*. Hove (UK): Lawrence Erlbaum Associates. p 63-86.
- LaBerge D. 2000. Networks of attention. In: Gazzaniga MS, editor. *The New Cognitive Neurosciences*. Cambridge, Mass.: MIT Press. p 711-724.
- Leibovitch FS, Black SE, Caldwell CB, Ebert PL, Ehrlich LE, Szalai JP. 1998. Brain-behavior correlations in hemispatial neglect using CT and SPECT: the Sunnybrook Stroke Study. *Neurology* 50(4):901-908.
- Makris N, Kennedy DN, McInerney S, Sorensen AG, Wang R, Caviness VS, Jr., Pandya DN. 2005. Segmentation of subcomponents within the superior longitudinal fascicle in humans: a quantitative, in vivo, DT-MRI study. *Cerebral Cortex* 15(6):854-869.
- Malhotra P, Jager HR, Parton A, Greenwood R, Playford ED, Brown MM, Driver J, Husain M. 2005. Spatial working memory capacity in unilateral neglect. *Brain* 128(Pt 2):424-435.
- Manning L, Kartsounis LD. 1993. Confabulations related to tacit awareness in visual neglect. *Behavioural Neurology* 6:211-213.
- Marshall JC, Halligan PW. 1988. Blindsight and insight into visuo-spatial neglect. *Nature* 336:766-767.
- McFie J, Piercy MF, Zangwill OL. 1950. Visual spatial agnosia associated with lesions of the right hemisphere. *Brain* 73:167-190.
- McGlinchey-Berroth R, Milberg W, Verfaellie M, Alexander M, Kiduff PT. 1993. Semantic processing in the neglected visual field: Evidence from a lexical decision task. *Cognitive Neuropsychology* 10:79-108.
- Mesulam M-M. 2005. Imaging connectivity in the human cerebral cortex: The next frontier? *Annals of Neurology* 57(1):5-7.
- Mesulam MM. 1981. A cortical network for directed attention and unilateral neglect. *Annals of Neurology* 10:309-325.
- Mesulam MM. 1985. Attention, confusional states and neglect. In: Mesulam MM, editor. *Principles of Behavioral Neurology*. Philadelphia (PA): F.A. Davis. p 125-168.
- Mesulam MM. 1999. Spatial attention and neglect: parietal, frontal and cingulate contributions to the mental representation and attentional targeting of salient extrapersonal events. *Philosophical Transactions of the Royal Society of London B* 354(1387):1325-1346.
- Meyer JS, Obara K, Muramatsu K. 1993. Diaschisis. *Neurol. Res.* 15(6):362-366.
- Milner AD, Goodale MA. 1995. *The Visual Brain in Action*. Oxford: Oxford University Press.
- Mishkin M, Ungerleider LG, Macko KA. 1983. Object vision and spatial vision: Two cortical pathways. *Trends in Neurosciences* 6:414-417.
- Morecraft RJ, Geula C, Mesulam MM. 1993. Architecture of connectivity within a cingulo-fronto-parietal neurocognitive network for directed attention. *Archives of Neurology* 50(3):279-284.
- Morrow LA, Ratcliff G. 1988. The disengagement of covert attention and the neglect syndrome. *Psychobiology* 16(3):261-269.

- Mort DJ, Malhotra P, Mannan SK, Rorden C, Pambakian A, Kennard C, Husain M. 2003. The anatomy of visual neglect. *Brain* 126(Pt 9):1986-1997.
- Nico D, Galati G, Incoccia C. 1999. The endpoints' task: an analysis of length reproduction in unilateral neglect. *Neuropsychologia* 37(10):1181-1188.
- Oliveri M, Rossini PM, Traversa R, Cicinelli P, Filippi MM, Pasqualetti P, Tomaiuolo F, Caltagirone C. 1999. Left frontal transcranial magnetic stimulation reduces contralesional extinction in patients with unilateral right brain damage. *Brain* 122 (Pt 9):1731-1739.
- Park KC, Lee BH, Kim EJ, Shin MH, Choi KM, Yoon SS, Kwon SU, Chung CS, Lee KH, Heilman KM and others. 2006. Deafferentation-disconnection neglect induced by posterior cerebral artery infarction. *Neurology* 66(1):56-61.
- Parton A, Malhotra P, Husain M. 2004. Hemispatial neglect. *Journal of Neurology, Neurosurgery and Psychiatry* 75(1):13-21.
- Petrides M, Pandya DN. 2002. Association pathways of the prefrontal cortex and functional observations. In: Stuss DT, Knight RT, editors. *Principles of frontal lobe function*. Oxford; New York: Oxford University Press. p 31-50.
- Plourde G, Sperry RW. 1984. Left hemisphere involvement in left spatial neglect from right-sided lesions. *Brain* 107 (Pt 1):95-106.
- Posner MI, Walker JA, Friedrich FJ, Rafal RD. 1984. Effects of parietal injury on covert orienting of attention. *Journal of Neuroscience* 4:1863-1874.
- Posner MI, Petersen SE. 1990. The attention system of human brain. *Annual Review of Neuroscience* 13:25-42.
- Posner MI. 2005. How I got here. In: Mayr U, Awh E, Keele SW, editors. *Developing Individuality in the Human Brain: A Tribute to Michael I. Posner*. Washington, DC: American Psychological Association. p 328.
- Reep RL, Corwin JV, Cheatwood JL, Van Vleet TM, Heilman KM, Watson RT. 2004. A rodent model for investigating the neurobiology of contralateral neglect. *Cognitive and Behavioral Neurology* 17(4):191-194.
- Reuter-Lorenz PA, Nozawa G, Gazzaniga MS, Hughes HC. 1995. Fate of neglected targets: a chronometric analysis of redundant target effects in the bisected brain. *Journal of Experimental Psychology: Human Perception and Performance* 21(2):211-230.
- Rizzolatti G, Matelli M. 2003. Two different streams form the dorsal visual system: anatomy and functions. *Experimental Brain Research* 153(2):146-157.
- Rushmore RJ, Valero-Cabre A, Lomber SG, Hilgetag CC, Payne BR. 2006. Functional circuitry underlying visual neglect. *Brain* 129(Pt 7):1803-1821.
- Rushworth MFS, Behrens TEJ, Johansen-Berg H. 2005. Connection patterns distinguish 3 regions of human parietal cortex. *Cerebral Cortex*.
- Schmahmann JD, Pandya DN. 2006. *Fiber Pathways of the Brain*. New York: Oxford University Press. 450 p.
- Selemon LD, Goldman-Rakic PS. 1988. Common cortical and subcortical targets of the dorsolateral prefrontal and posterior parietal cortices in the rhesus monkey: evidence for a distributed neural network subserving spatially guided behavior. *Journal of Neuroscience* 8(11):4049-4068.
- Smania N, Martini MC, Prior M, Marzi CA. 1996. Input and response determinants of visual extinction: A case study. *Cortex* 32:567-591.
- Sprague JM. 1966. Interaction of cortex and superior colliculus in mediation of visually guided behavior in the cat. *Science* 153(743):1544-1547.
- Thiebaut de Schotten M, Urbanski M, Duffau H, Volle E, Lévy R, Dubois B, Bartolomeo P. 2005. Direct evidence for a parietal-frontal pathway subserving spatial awareness in humans. *Science* 309(5744):2226-2228.

- Thiebaut de Schotten M, Kinkingnéhun SR, Delmaire C, Lévy R, Volle E, Dubois B, Lehericy S, Duffau H, Bartolomeo P. 2006. OVER-TRACK: A new tool to visualize the white matter organization in Talairach space. *Neuroimage* 31(Supplement 1).
- Vallar G, Guariglia C, Rusconi ML. 1997. Modulation of the neglect syndrome by sensory stimulation. In: Thier P, Karnath HO, editors. *Parietal Lobe Contributions to Orientation in 3D-Space*. Heidelberg: Springer-Verlag. p 555-578.
- Vallar G. 2001. Extrapersonal visual unilateral spatial neglect and its neuroanatomy. *Neuroimage* 14(1 Pt 2):S52-S58.
- Verdon V, Lovblad K-O, Hauert C-A, Vuilleumier P. Neuroanatomical basis of hemispatial neglect components using Voxel-based Lesion Symptom Mapping. Poster presented at the 2nd Meeting of the European Societies of Neuropsychology; 2006 October 18 – 20; Toulouse, France.
- Volpe BT, Ledoux JE, Gazzaniga MS. 1979. Information processing of visual stimuli in an "extinguished" field. *Nature* 282(5740):722-4.
- Vuilleumier P, Hester D, Assal G, Regli F. 1996. Unilateral spatial neglect recovery after sequential strokes. *Neurology* 46:184-189.
- Watson RT, Valenstein E, Day AL, Heilman KM. 1984. The effect of corpus callosum lesions on unilateral neglect in monkeys. *Neurology* 34(6):812-815.
- Weddell RA. 2004. Subcortical modulation of spatial attention including evidence that the Sprague effect extends to man. *Brain and Cognition* 55(3):497-506.
- Zihl J, von Cramon D. 1979. Collicular function in human vision. *Experimental Brain Research* 35(3):419-424.

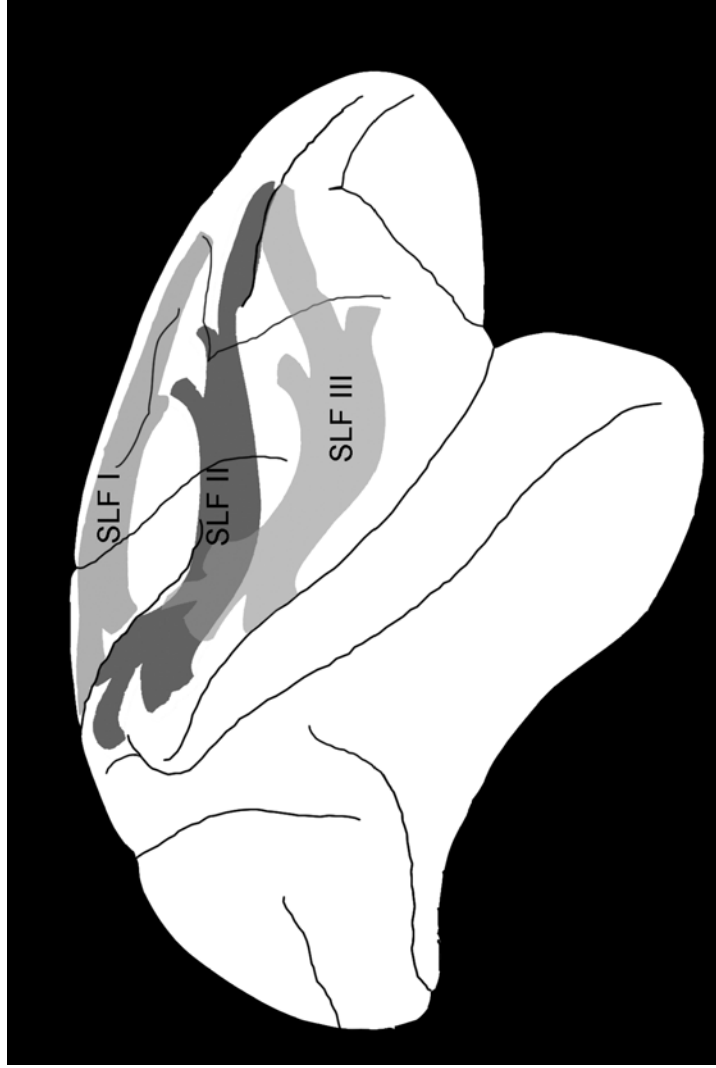
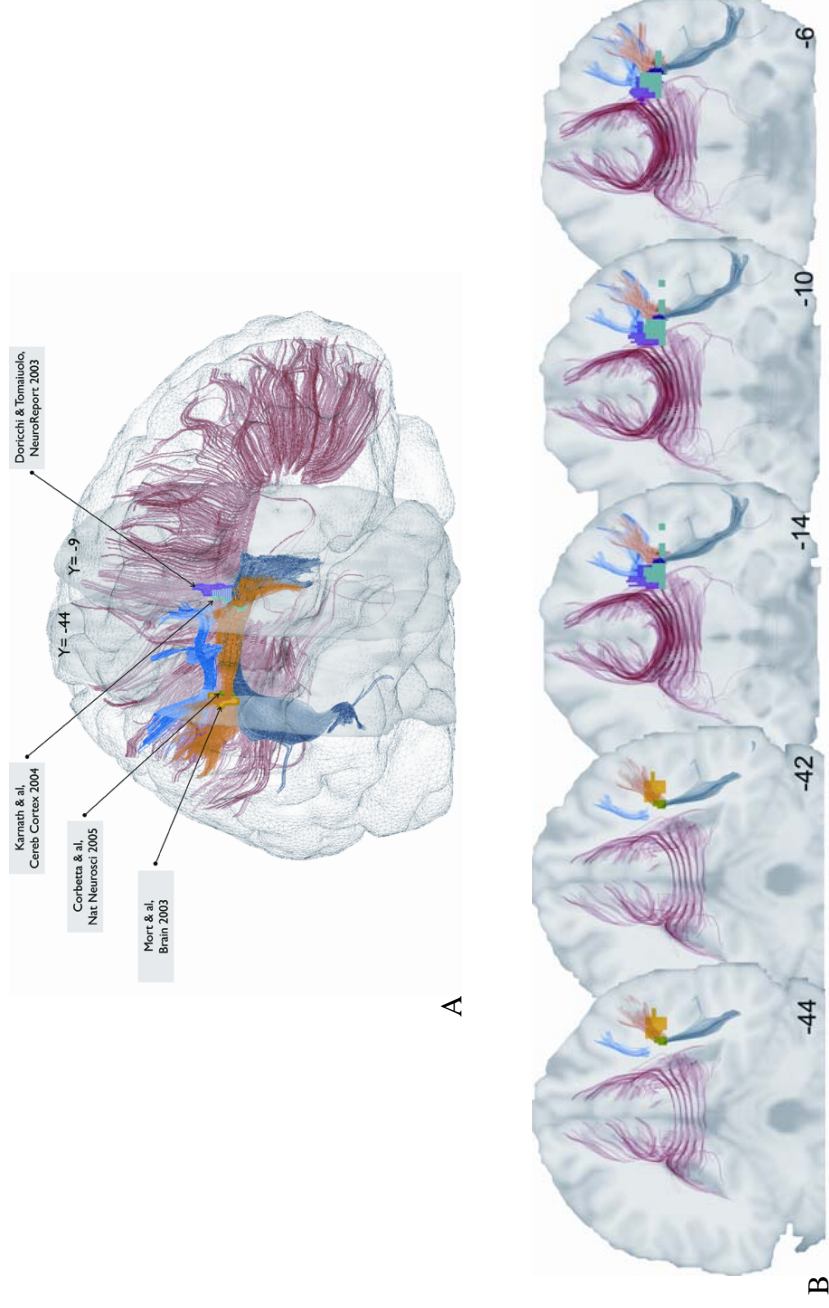


Fig. 1. Schematic depiction of the three branches of the SLF in the monkey brain according to Schmammann and Pandya (2006).

Fig. 2 Lateral view (A) and coronal sections (B) of a normalized brain showing a 3D reconstruction of white matter pathways (red, corpus callosum; dark blue, AF; orange, SLF III; blue, SLF II), and the maximum overlap of neglect patients' subcortical lesions from 4 studies (pink, Doricchi and Tomaiuolo 2003; yellow, Mort et al. 2003; light blue, Karnath et al. 2004; green, Corbetta et al. 2005). See Supplementary Material for methods.



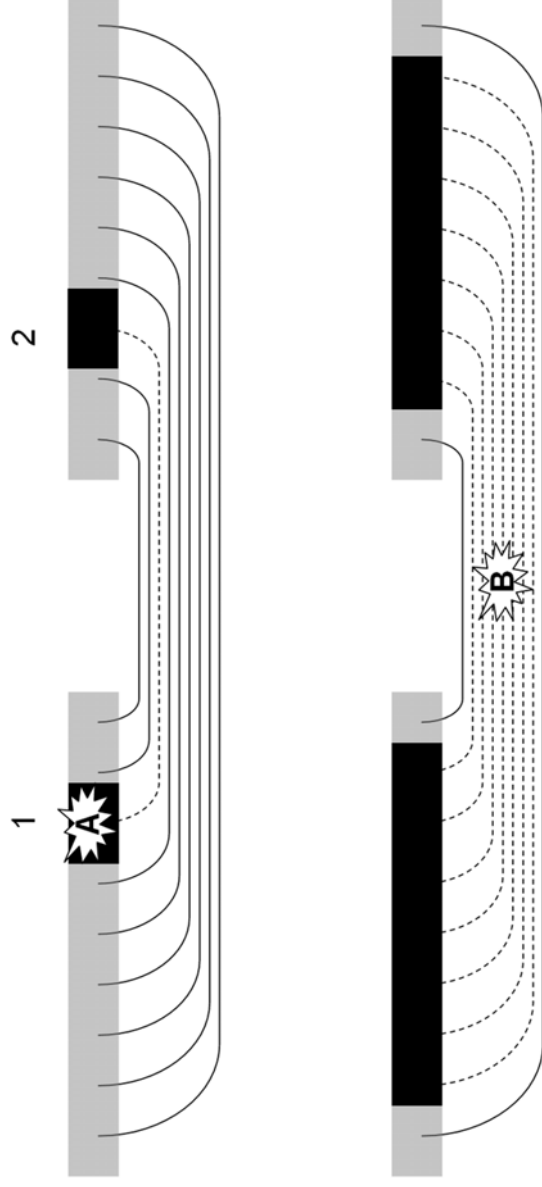


Fig. 3. White matter lesions may cause more severe deficits than equivalent cortical lesions. Grey areas, functionally normal cortex. Black rectangles, dysfunctional cortical regions. Dashed pathways, dysfunctional white matter tracts. Lesion A to the cortical grey matter impairs cortical functions both (1) locally, through topological mechanisms and (2) distally, through hodological mechanisms (see Catani and ffytche 2005). Lesion B, of equivalent volume but affecting the tightly packed white matter tracts, may impair the integrated functioning of larger cortical regions, thus resulting in a more severe deficit.

Supplementary Material

Re-appraisal of previous lesion overlap studies: Methods

Overlap Region of Interest (ROI). Data from the original overlapping maps were used to define the maximum overlap described by Doricchi and Tomaiuolo (Doricchi and Tomaiuolo 2003) (see Table 1 for MNI coordinates). The subcortical maximum lesion overlaps of the Karnath et al study (Karnath et al. 2004, Fig. 2) were manually drawn on the same Montreal Neurological Institute (MNI) template using MRICro 1.40 (Rorden and Brett 2000) (<http://www.sph.sc.edu/comd/rorden/mricro.html>). For the remaining studies (Mort et al. 2003; Corbetta et al. 2005), the maximum overlap was manually drawn in MRICro, using the MNI coordinates reported in the studies for the lesion overlaps correlated to spatial neglect. Supplementary Table 1 reports the MNI coordinates of the centroids of the subcortical maximum overlap areas in these studies.

DTI acquisition. Diffusion-weighted magnetic resonance imaging data were acquired from a healthy 41-year-old male right-handed volunteer, using DTI at 1.5T. Diffusion parameters were TR/TE/angle: 12.5s/66.2ms/90°, voxel size: 1.88x1.88x2 mm³, b-value: 700 s/mm², 41 directions and 1 B0 image. Data were acquired with NMR pulse sequences, reconstructed with NMR reconstructor package and post processed with AIMS/Anatomist/BrainVisa software, available at <http://brainvisa.info>.

Tractography. Diffusion image analysis was performed using tensor diffusion imaging and deterministic fiber algorithm using Brainvisa 3.0.2 (<http://brainvisa.info/>). Fiber tracking was performed using two manually drawn ROIs: (1) a global ROI based on previously published methods (Catani et al. 2005) and (2) caudal selective ROIs (Thiebaut de Schotten et al. 2006), which allowed us to differentiate the single fasciculi (Supplementary Figure 1).

Bundle normalization and visualization. EPI B0 image was normalized with default parameters to the EPI template space provided by statistical parametric mapping software (SPM2, Wellcome Department of Cognitive Neurology, Institute of Neurology, London, UK, <http://www.fil.ion.ucl.ac.uk/spm/>), in association with MATLAB version 7 (The Mathworks, Inc., MA, USA). The resulting deformation matrix was applied to the fiber bundles (Thiebaut de Schotten et al. 2006). The maximum overlaps and the normalized bundles were visualized using Anatomist 3.0.2 (<http://brainvisa.info>).

References

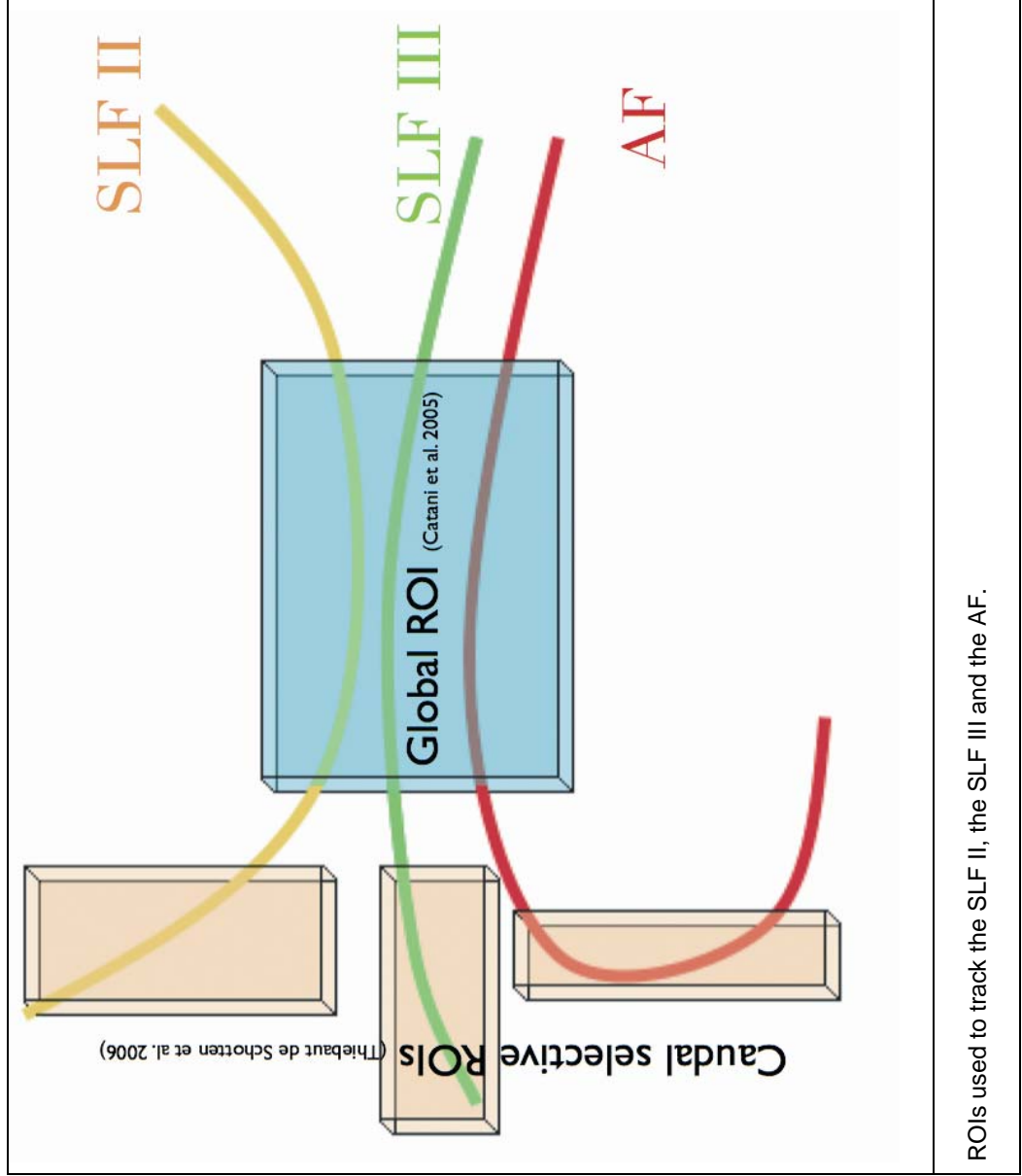
- Catani M, Jones DK, ffytche DH. 2005. Perisylvian language networks of the human brain. *Annals of Neurology* 57(1):8-16.
- Committeri G, Pitzalis S, Galati G, Patria F, Pelle G, Sabatini U, Castriota-Scanderbeg A, Piccardi L, Guariglia C, Pizzamiglio L. 2006. Neural bases of personal and extrapersonal neglect in humans. *Brain*.
- Corbetta M, Kincade MJ, Lewis C, Snyder AZ, Sapir A. 2005. Neural basis and recovery of spatial attention deficits in spatial neglect. *Nature Neuroscience* 8(11):1603-1610.
- Doricchi F, Tomaiuolo F. 2003. The anatomy of neglect without hemianopia: a key role for parietal-frontal disconnection? *NeuroReport* 14(17):2239-2243.
- Karnath H-O, Fruhmann Berger M, Kuker W, Rorden C. 2004. The anatomy of spatial neglect based on voxelwise statistical analysis: a study of 140 patients. *Cerebral Cortex* 14(10):1164-1172.
- Mort DJ, Malhotra P, Mannan SK, Rorden C, Pambakian A, Kennard C, Husain M. 2003. The anatomy of visual neglect. *Brain* 126(Pt 9):1986-1997.
- Rorden C, Brett M. 2000. Stereotaxic display of brain lesions. *Behavioural Neurology* 12(4):191-200.
- Thiebaut de Schotten M, Kinkingnéhun SR, Delmaire C, Lévy R, Volle E, Dubois B, Lehericy S, Duffau H, Bartolomeo P. 2006. OVER-TRACK: A new tool to visualize the white matter organization in Talairach space. *Neuroimage* 31(Supplement 1).

Supplementary Table 1

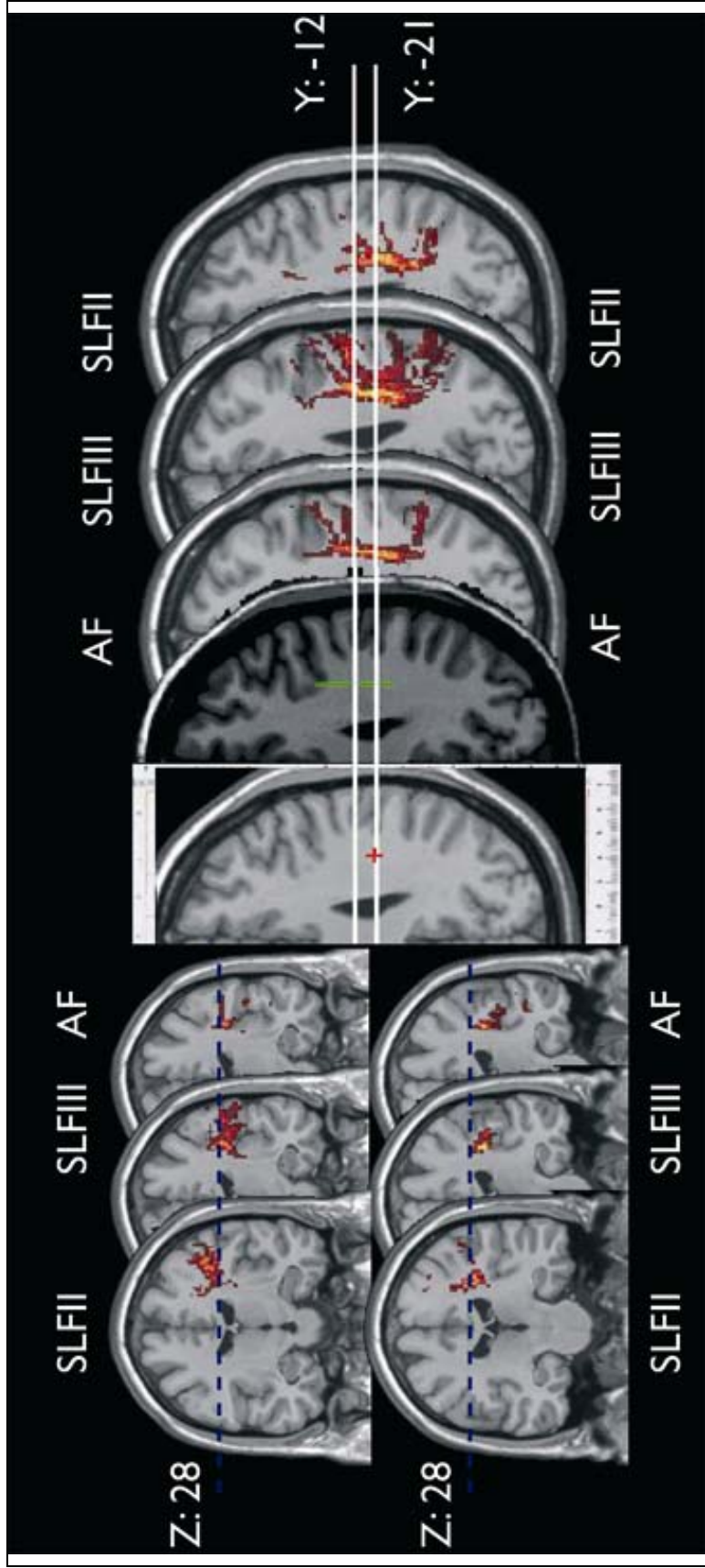
	<i>MNI coordinates</i>		
	<i>x</i>	<i>y</i>	<i>z</i>
(Corbetta et al. 2005)	37	-44	23
(Doricchi and Tomaiuolo 2003)	35	-12	27
	26	-10	35
(Karnath et al. 2004)	26	-5	24
	41	-12	24
(Mort et al. 2003)	46	-44	29

Coordinates of the centroids of the subcortical maximum overlap areas

Supplementary Figure 1



Supplementary Figure 2



The red cross indicates the subcortical maximum lesion overlap found in patients with extrapersonal neglect by Committeri et al. (Committeri et al. 2006, Fig. 2, first row, axial slice Z = +28)). The lesion overlap described in patients with extrapersonal neglect by Doricchi and Tomaiuolo (Doricchi and Tomaiuolo 2003) is indicated in green. The matching MNI templates showing the trajectories of SLF II, III and AF are also shown.