



**HAL**  
open science

**Identification of three novel OA1 gene mutations identified in three families misdiagnosed with congenital nystagmus and carrier status determination by real-time quantitative PCR assay.**

Valérie Faugère, Sylvie Tuffery-Giraud, Christian P. Hamel, Mireille Claustres

► **To cite this version:**

Valérie Faugère, Sylvie Tuffery-Giraud, Christian P. Hamel, Mireille Claustres. Identification of three novel OA1 gene mutations identified in three families misdiagnosed with congenital nystagmus and carrier status determination by real-time quantitative PCR assay.. BMC Genetics, 2003, 4, pp.1. 10.1186/1471-2156-4-1 . inserm-00121538

**HAL Id: inserm-00121538**

**<https://inserm.hal.science/inserm-00121538v1>**

Submitted on 26 Dec 2006

**HAL** is a multi-disciplinary open access archive for the deposit and dissemination of scientific research documents, whether they are published or not. The documents may come from teaching and research institutions in France or abroad, or from public or private research centers.

L'archive ouverte pluridisciplinaire **HAL**, est destinée au dépôt et à la diffusion de documents scientifiques de niveau recherche, publiés ou non, émanant des établissements d'enseignement et de recherche français ou étrangers, des laboratoires publics ou privés.

Methodology article

Open Access

## Identification of three novel OAI gene mutations identified in three families misdiagnosed with congenital nystagmus and carrier status determination by real-time quantitative PCR assay

Valérie Faugère<sup>1</sup>, Sylvie Tuffery-Giraud<sup>1</sup>, Christian Hamel<sup>2</sup> and Mireille Claustres\*<sup>1</sup>

Address: <sup>1</sup>Laboratoire de Génétique Moléculaire, Institut Universitaire de Recherche Clinique IURC et CHU, 641 Avenue du Doyen Gaston Giraud, 34093 Montpellier cedex 5, France and <sup>2</sup>Inserm U. 254, rue de Navacelles, 34090 Montpellier, France

Email: Valérie Faugère - vfaugere@igh.cnrs.fr; Sylvie Tuffery-Giraud - tuffery@igh.cnrs.fr; Christian Hamel - hamel@montp.inserm.fr; Mireille Claustres\* - Mireille.Claustres@igh.cnrs.fr

\* Corresponding author

Published: 7 January 2003

Received: 21 October 2002

BMC Genetics 2003, 4:1

Accepted: 7 January 2003

This article is available from: <http://www.biomedcentral.com/1471-2156/4/1>

© 2003 Faugère et al; licensee BioMed Central Ltd. This is an Open Access article: verbatim copying and redistribution of this article are permitted in all media for any purpose, provided this notice is preserved along with the article's original URL.

### Abstract

**Background:** X-linked ocular albinism type I (OAI) is caused by mutations in *OAI* gene, which encodes a membrane glycoprotein localised to melanosomes. OAI mainly affects pigment production in the eye, resulting in optic changes associated with albinism including hypopigmentation of the retina, nystagmus, strabismus, foveal hypoplasia, abnormal crossing of the optic fibers and reduced visual acuity. Affected Caucasian males usually appear to have normal skin and hair pigment.

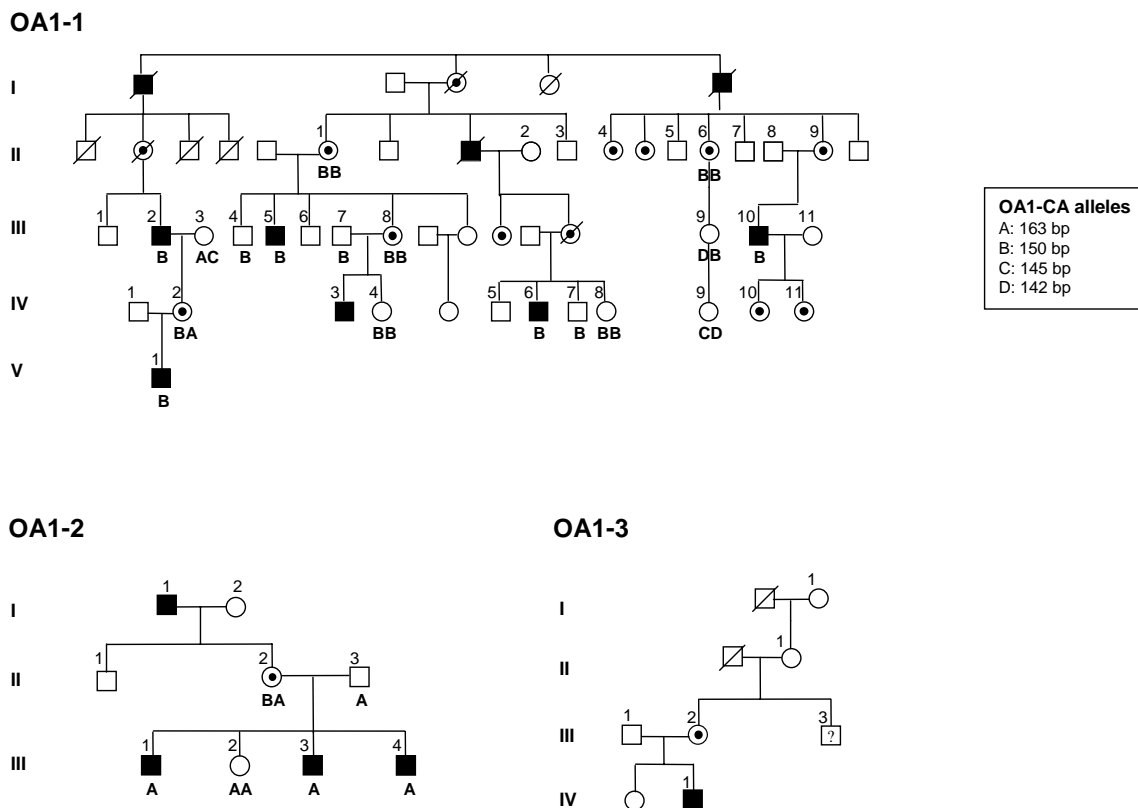
**Results:** We identified three previously undescribed mutations consisting of two intragenic deletions (one encompassing exon 6, the other encompassing exons 7–8), and a point mutation (310delG) in exon 2. We report the development of a new method for diagnosis of heterozygous deletions in *OAI* gene based on measurement of gene copy number using real-time quantitative PCR from genomic DNA.

**Conclusion:** The identification of *OAI* mutations in families earlier reported as families with hereditary nystagmus indicate that ocular albinism type I is probably underdiagnosed. Our method of real-time quantitative PCR of *OAI* exons with *DMD* exon as external standard performed on the LightCycler™ allows quick and accurate carrier-status assessment for at-risk females.

### Background

Congenital nystagmus (CN) is the common symptom of a range of diseases involving the macula from infancy on, and includes at least three X-linked disorders: Nettleship-Falls ocular albinism type 1 (OA1; MIM#300500) mapped to Xp22.3, complete congenital stationary night blindness (CSNB1; MIM#310500), mapped to Xp11.3 and blue-cone monochromatism (CBBM; MIM#303700), mapped to Xq28. These genetic disorders must be distin-

guished from the congenital motor nystagmus (CMN), a hereditary disorder characterized by bilateral ocular oscillations which occurs in the absence of any apparent ocular disease [1]. Diagnosis of the underlying disease often requires extensive clinical and electrophysiological examinations. Prevalence of OA1 is estimated around 1 in 50,000 live births in Caucasian populations. The most frequent findings in hemizygous individuals with OA1 are foveal hypoplasia, hypopigmentation of the retina and



**Figure 1**  
**Pedigrees initially referred for congenital X-linked nystagmus.** Black squares are for affected males, small solid circle within open circles for obligate carrier females, open symbols for non affected individuals. ?: undefined clinical status prior to doing molecular study. Numbered individuals are those in whom molecular investigation of the *OA1* gene was performed. Results of the *OA1-CA* microsatellite analysis are given in families OA1-1 and OA1-2 as indicated by alleles A, B, C, or D.

iris translucency together with normally pigmented skin and hair [2]. The disease typically results in severely impaired visual acuity in affected males who also manifest variable strabismus, photophobia, and misrouting of optic pathway. The size, shape and number of melanocytes are normal in the skin, hair follicle and retinal pigment epithelium in OA1 patients, but they contain (although not specifically) variable proportions of giant melanosomes [3]. In spite of a well-defined clinical presentation, a few individuals initially misdiagnosed with congenital nystagmus have been shown to be affected by ocular albinism type 1 by screening the *OA1* gene [3,4]. We report on three additional white OA1 unrelated families, with a total of fourty seven individuals, which were initially referred to our laboratory for congenital nystagmus. The aim of the study was to elucidate the molecular genetic de-

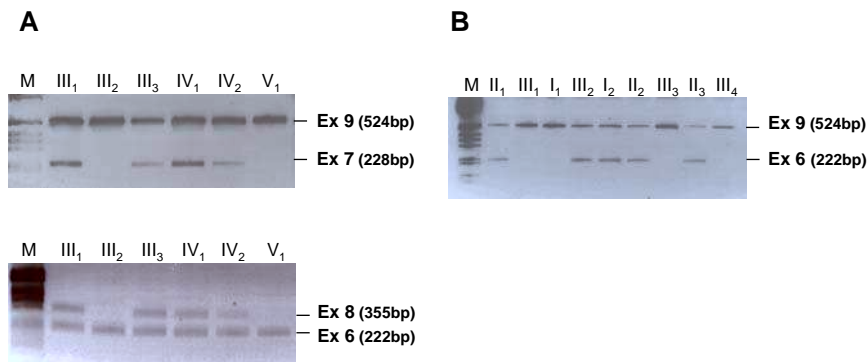
fect responsible for the phenotype and to define a reliable strategy to assess the genetic status of at-risk females.

**Results and discussion**

Analysis of X-linked markers in the two pedigrees (OA1-1 and OA1-2) initially reported as familial cases diagnosed with X-linked congenital nystagmus was consistent with an association between the affected phenotype and the *OA1* locus, as exemplified in Fig. 1 for a microsatellite in *OA1* intron 1. *OA1* gene was then extensively screened, and the disease-causing mutation could be identified in the three families reported in this study.

**Two novel *OA1* gene deletions**

The *OA1* gene was then examined for mutations, and we detected one deletion encompassing exons 7–8 (pedigree OA1-1), and one deletion encompassing exon 6 (pedigree



**Figure 2**

**Detection of *OAI* intragenic deletions in males.** (A) Exon 7 (top) and exon 8 (bottom) failed to amplify in two affected males III2 and V1 from family OA1-1 while the two exons amplified normally from DNA obtained from unaffected individuals (III1, III3, IV1) and a female carrier (IV2). As internal control, exon 9 of the *OAI* gene has simultaneously amplified from the DNA samples of family members. (B) A deletion of exon 6, using primers 6H6F and 6H6R [5], was detected in the proband III1 of family OA1-2. The deletion of exon 6 was found in all affected individuals of the family (II1, III1, III3, and III4). Alternative primers were used to confirm the deletion (data not shown). M: molecular weight marker, one kilobase ladder, Gibco BRL.

OA1-2). The amplification failure was shown to be specific for this portion of the *OAI* gene by using duplex-PCR. In pedigree OA1-1, exons 7 and 8 were co-amplified with *OAI* exons 9 and 6, respectively (Fig. 2A). In pedigree OA1-2, exon 6 was co-amplified with *OAI* exon 9 (Fig. 2B). Moreover, the single exon 6 deletion was confirmed using alternative primers to exclude possible sequence changes in primer annealing sites.

As heterozygous deletions are not detected by conventional PCR, assessment of genetic status in females was performed by using two complementary strategies.

#### Indirect analysis

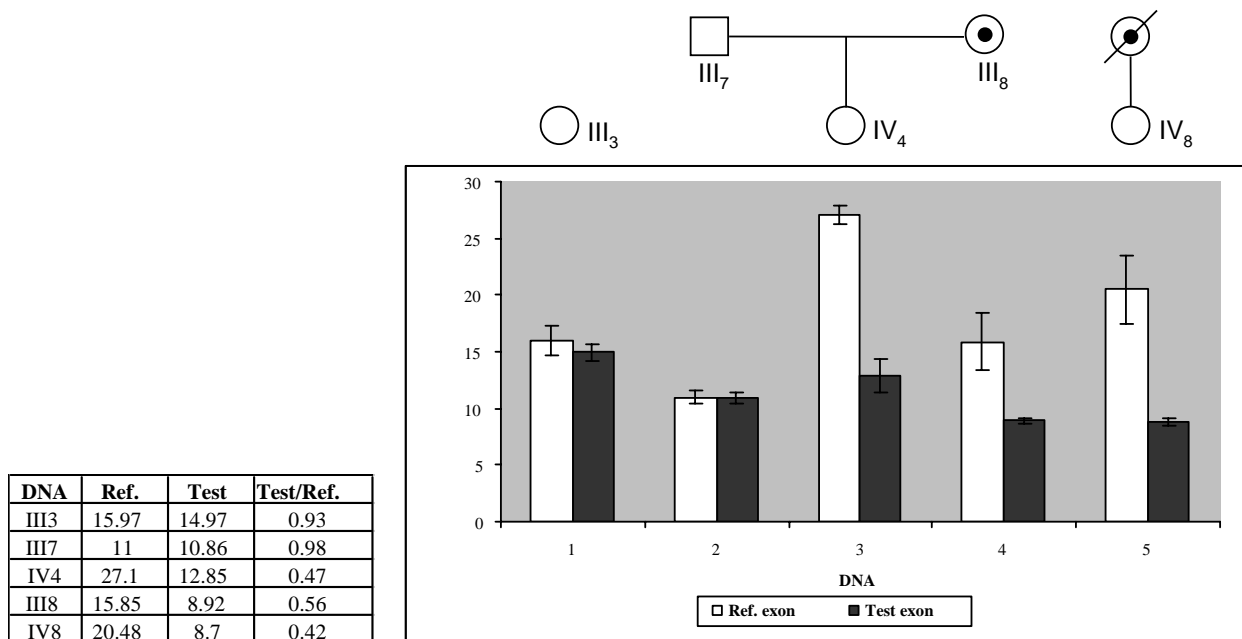
A highly polymorphic dinucleotide repeat *OAI-CA* located within intron 1 [5] was used for carrier testing in both families. Segregation analysis using the *OAI-CA* marker in the family OA1-2 showed that the sister (III2) of the affected individuals had inherited the maternal allele (A) that has been transmitted to the affected males (Fig. 1), thus indicative of the sister to be a probable carrier of the exon 6 deletion in the *OAI* gene. In family OA1-1, the analysis of marker *OAI-CA* revealed full cosegregation between one allele (B) of the dinucleotide repeat and the disease (Fig. 1), which allowed to exclude one at-risk female (IV9) of being a carrier.

#### Establishment of a quantitative real-time PCR for *OAI* gene dosage assay

Indirect analysis was not able to elucidate the carrier status of two other females IV4 and IV8 in family OA1-1. We therefore developed a quantitative test for detection of heterozygous deletions on the basis of real-time PCR on a LightCycler™ instrument. The method involves amplification of an exon included in the deletion (*OAI*-exon 8) and normalization of genomic template by analyzing a reference locus with known copy number. We used a fragment (exon 4) of the *DMD* gene as reference locus because it yielded previously highly reproducible amplification results. Heterozygosity for a deletion is expected to reduce the gene dose from two to one in carriers. We detected an *OAI*-exon 8/*DMD*-exon 4 ratio of 0.56 in female III8, thus confirming the presence of the heterozygous deletion of exon 8 in this obligate carrier, while the female and male controls showed a ratio of approximately 1.0 (0.93 and 0.98, respectively) (Fig. 3). Gene dosage analysis in the two females IV4 and IV8 whose carrier status was previously undefined clearly established that they were both carriers of an exon 8 deletion (*OAI*-exon8/*DMD*-exon 4 ratio of 0.47 and 0.42, respectively).

#### A novel frameshift *OAI* point mutation

In the index patient (IV1) of family OA1-3 that did not show exon deletion, sequence analysis of all coding exons including the exon-intron boundaries revealed a deletion of a single nucleotide G at position 310 of the cDNA in-



**Figure 3**  
**Real-Time Fluorescent PCR Gene Dosage Test.** Segregation of the deletion of exons 7–8 in pedigree OAI-1 was demonstrated by quantitative screening using the Light Cycler™ technology. Results of dosage of the *DMD*-exon 4 (reference locus) and *OAI*-exon 8 (test locus) are shown on the histogram (white bars and grey bars, respectively). Each DNA sample was run in quadruplicate. Errors bars indicate standard deviation. Mean values of dosages and ratios [*OAI*-exon 8 (test) *DMD*-exon 4] are given in the Table. Lane 1, normal control female; lane 2, normal male; lane 4, obligate carrier of the exons 7–8 deletion (ratio test/ref of 0.56). Lanes 3 and 5, females IV4 and IV8 (with undefined status initially) showing a heterozygous deletion of *OAI*-exon 8 indicated by ratios of approximately 0.5.

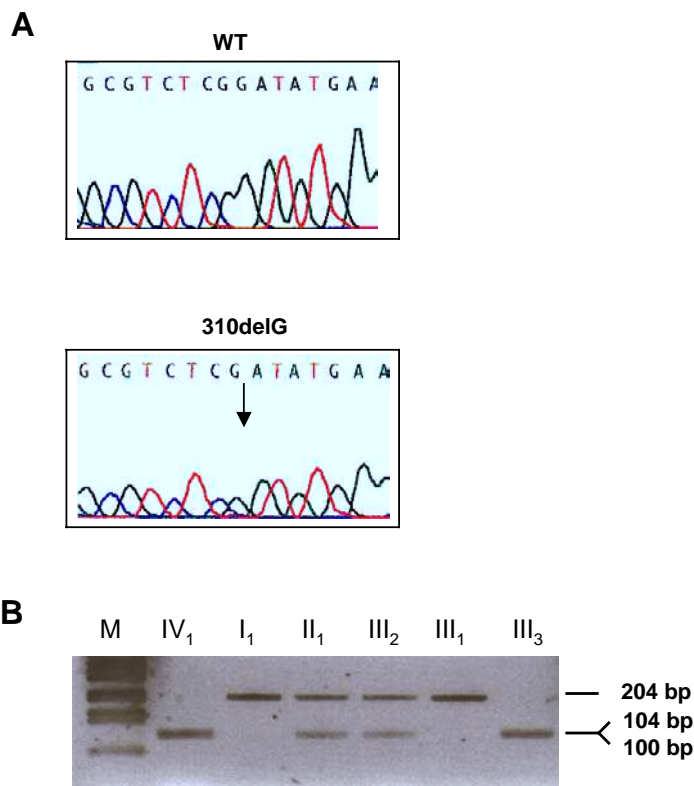
producing a subsequent premature stop codon one codon downstream, predicting a deleterious protein product. This newly described mutation (310delG) in exon 2 of the *OAI* gene creates a *TaqI* restriction site. Although the pedigree of family OAI-3 initially suggested the patient IV1 to be a sporadic case, PCR-restriction analysis identified the patient's maternal uncle (III3), known to have only a decreased visual acuity at age 38, as hemizygous for the mutation. The mother (III2) and the maternal grand-mother (II1) of the proband were found to be carriers (Fig. 4B), as expected, while the great-grandmother (I1) showed a normal pattern of PCR restriction, which is indicative either of a *de novo* mutation in her germline or inheritance of the mutation from her deceased husband.

Different prevalences of intragenic *OAI* deletions have been reported, ranging from 8% to 50% in different studies [6,7]. As approximately 50% of the *OAI* mutations reported to date [7], the three mutations described in this study lead to a truncated *OAI* protein and, presumably, to

a complete loss of function. Several missense mutations have also been described in *OAI* which result in defective intracellular transport and glycosylation due to misfolding of the protein [8]. *OAI* encodes a seven helix membrane G protein coupled receptor (GPCR) localized to the membrane of intracellular organelles, namely the melanosomes in pigment cells [3,9]. *OAI* is thought to be involved in the regulation of biogenesis and maturation of melanosomes through activation of heterotrimeric G proteins on the cytoplasmic side of melanosomal membrane [8]. The aberrant pigment production associated with *OAI* could be caused by a defect in a yet unidentified intracellular signal transduction system that regulates the growth of melanosomes [3,10,11]

**Conclusions**

The three mutations reported here have been found in patients who were initially misdiagnosed with congenital nystagmus when they were examined first. Our observation is in agreement with previous report by Rosenberg



**Figure 4**

**Characterisation of the 310delG mutation in the family OAI-3.** (A) Direct sequencing of the *OAI* gene exon 2 showing a one-bp deletion in the index case (bottom) compared with the wild-type sequence (top). (B) Familial segregation of the 310delG mutation is illustrated by restriction analysis. The mutation creates a new restriction site for *TaqI*, which cleaves the 204-bp exon 2 PCR product into two fragments (104 and 100 bp) in III3 and IV1, showing a heterozygous pattern in the carrier females III1 and III2. M: molecular weight marker, one kilobase ladder, Gibco BRL.

and Schwartz. [9] who stated that ocular albinism type 1 is underdiagnosed and pinpoints the fact that the clinical investigation of patients in specialized consultation may be required for accurate and differential diagnosis of OA1. The female carriers are usually asymptomatic, but have been reported to exhibit punctuate areas of iris transillumination defects and a characteristic mottled appearance of the retinal pigment epithelium resulting from Lyonisation [12]. Also, the identification of macromelanosomes on skin biopsy can be useful for supporting the diagnosis and identifying carriers even though it is not a specific and obligate criteria [4]. However, if clinical examination will detect approximately 70 % of carrier females, it will not allow reliable genetic counselling for all at-risk females because of the variability in clinical manifestations. Reliable carrier determination can be achieved by molecular studies as presented in this study. It relies on different molec-

ular approaches depending on the familial history (familial versus sporadic cases) and the type of the mutation (point mutation versus large deletions). In familial cases with unidentified OA1 mutations, indirect approach based on linkage analysis using microsatellites may be of help but requires extensive familial DNA analysis and may be inconclusive in some individuals. Direct testing of previously characterized point mutations in at risk females can be performed either by direct sequencing or by scanning methods such as DGGE (Denaturing Gradient Gel Electrophoresis) or dHPLC (denaturing High Performance Liquid Chromatography), although these methods may be more technically difficult to set up. For detection of intragenic deletions in females, Southern blotting is not the method of choice as it is time-consuming, radioactive, and as estimation of gene dosage by measuring the intensity of probe hybridized is not accu-

rate enough. The real-time fluorescent PCR gene dosage assay that we have developed in this study is an accurate, non radioactive and fast method for gene carrier assessment that can be applied to any type of *OA1* gene deletion.

## Methods

### Families

Affected males in pedigrees OA1-1, OA1-2, and OA1-3 were initially diagnosed with congenital nystagmus inherited in an X-linked pattern, and blood samples from 47 individuals were referred to our laboratory for genotyping in the purpose to identify the genetic interval with which a putative gene could be located. Blood samples were taken from patients and available family members after informed consent, and genomic DNA was isolated by standard techniques. All individuals were Caucasians originating from South of France.

### Clinical examination

Congenital nystagmus was diagnosed in individuals IV3 in pedigree OA1-1, I1, III1 and III3 in pedigree OA1-2 and IV1 in pedigree OA1-3 following routine ophthalmological examination. The patients had normal hair and skin pigmentation. There was no photophobia or nyctalopia.

After identification of a mutation in the *OA1* gene, clinical signs were re-evaluated. Kinetic visual fields were determined in a Goldman perimeter with targets V4e, III4e, et I4e. Full-fields ERG was recorded using a ganzfeld apparatus (Metrovision, France) with a bipolar contact lens electrode on maximally dilated pupils. Ophthalmological examination revealed signs consistent with ocular albinism type 1 in all affected males re-examined.

In family OA1-1 the affected male IV3, aged 10 at the time of presentation, had a visual acuity of 30/200 in RE (+2.50 sph/+1.50 cyl A 70°) and 40/200 in LE (+2.50 sph/+1.00 A 180°). At slit-lamp examination there was no abnormality of the iris pigmentation and the lenses were transparent. The fundus revealed a patchy aspect of the pigmentation in peripheral retina with some areas of hypopigmentation. There was a foveal hypoplasia that was confirmed by the absence of the normal autofluorescence of the macula.

In family OA1-2, the 9-year old proband III4 had a visual acuity of 40/200 in both eyes. Slit-lamp examination revealed retroillumination of the iris periphery. The lenses were transparent. Fundus examination showed a slight depigmentation with moderate foveal hypoplasia. The 44 year-old mother (II2) who was also examined had 20/20 of visual acuity in both eyes and normal iris pigmentation; however, fundus examination revealed a patchy pig-

mentation at the posterior pole and numerous, low contrasted gray dots in the mid periphery of the retinas.

The apparently sporadic case IV2 in family OA1-3 had, at 26 years of age, a visual acuity of 30/200 in both eyes with RE (+3.00 sph/3.50 cyl A 180°) and LE (+4.25 sph/2.75 cyl A 180°). Slit-lamp examination revealed a spoke like atrophy of the iris with retroillumination. The lenses were transparent and the intraocular pressure was 14 (RE) and 15 (LE). Fundus examination showed a radial pattern of hypopigmentation that spared the macula. There was foveal hypoplasia with some retinal vessels that crossed the macular area, confirmed by the absence of the normal autofluorescence of the macula. ERG recording of the mixed rod-cone response was in the normal range but the rod response was slightly diminished and the cone response (30-Hz flickers) was markedly diminished.

Skin biopsy was unavailable for any patient at the time of the study.

### Linkage analysis

X chromosome marker set (Panel 28) from the ABI PRISM Linkage Mapping set MD-10 (Applied Biosystems) was used. Markers were amplified from genomic DNA, according to methods specified by the manufacturers. PCR products were loaded onto an ABI 377 automated sequencer, and data were analyzed by ABI GeneScan 3.5 and Genotyper softwares.

### Screening *OA1* gene for mutations

All nine exons of the *OA1* gene and part of the flanking introns were PCR-amplified from genomic DNA using the primers described by Schiaffino et al. [5], with some modifications. A new forward primer was used for exon 3 amplification (5'-TGACCTTCCAGAGCGCAG-3'). Also, new primers were designed to confirm the single exon 6 deletion in family OA1-2 (forward 5'-GCCTTGCTTGTGGGCTCAC-3'; reverse 5'-TCAAAGGGCACCTAGCACAGTCT-3'). PCR products of the 9 exons were sequenced on both strands using the BigDye terminator cycle sequencing kit (Applied Biosystems, Foster City, CA) and analyzed on an ABI 310 automated sequencer with the sequence analysis software, according to the manufacturer's protocols.

### Carrier status determination

#### Restriction analysis

The PCR products were digested with 10 units of the appropriate restriction enzyme, resolved on NuSieve agarose gels, and visualized with ethidium bromide.

#### Indirect diagnosis using *OA1*-CA repeat

The dinucleotide repeat sequence was amplified using primers and PCR conditions previously described [5]. Flu-

orescent PCR products were analyzed on an ABI 310 automated sequencer.

#### Gene dosage analysis in family OAI-2

The quantification was performed with a LightCycler instrument (Roche Diagnostics) using SYBR Green I for on-line measurement of PCR products. The method involves amplifications of a test exon located within the deleted region (OAI exon 8) with unknown copy number and a reference locus (exon 4 of the X-linked DMD gene) with known copy number. Using standard curves, the copy number of the test DNA relative to a common standard DNA is determined for each locus. From the ratio of the relative copy numbers, the genomic copy number of the test locus is determined. In each assay, 3 family members, 2 normal controls (male and female), and a no-template control (background) were included. Each sample was run in quadruplicate. The PCR was performed in a total volume of 20 µl, containing 4 pmol of each primer, 2 µl of Faststart DNA kit SYBR Green I, 5 mM MgCl<sub>2</sub>. The reactions were cycled 45 times with a 95°C denaturation for 15 sec, a 55°C (OAI exon 8) or 65°C (DMD exon 4) annealing for 5 sec, and 72°C extension for 10 sec (DMD exon 4) or for 15 sec (OAI exon 8). The primer sequences for OAI-exon 8 and DMD-exon 4 have been previously described [5,13]. This quantification program was followed by a melting program for every PCR product for each sample. Quantification data were analyzed using the fit points method of the LightCycler software.

#### List of abbreviation

OAI: ocular albinism type 1

PCR: polymerase chain reaction

CN: congenital nystagmus

CSNB: complete congenital stationary night blindness

CBBM: blue-cone monochromatism

CMN: congenital motor nystagmus

DMD: duchenne muscular dystrophy

GPCR: G protein coupled receptor

ERG: electroretinography

DGGE: denaturing gradient gel electrophoresis

DHPLC: denaturing high performance liquid chromatography

#### Author's contribution

VF carried out the molecular genetic studies. STG conceived the real time quantitative PCR. CH collected the clinical data. MC coordinated the study.

#### Acknowledgements

The authors express their gratitude to SOS-Rétinite France for their support to this study.

#### References

1. King RA, Hearing VJ, Creel DJ and Oetting WS **The metabolic and molecular bases of inherited disease**. In: *Albinism* (Edited by: Scriver CR, Beaudet AL, Sly WS, Valle D) New York: McGraw-Hill 2001, 5587-5627
2. Creel D, O'Donnell FE and Witkop CJ **Visual system anomalies in human ocular albinos**. *Science* 1978, **201**:931-3
3. Preising M, Op de Laak JP and Lorenz B **Deletion in the OAI gene in a family with congenital X linked nystagmus**. *Br J Ophthalmol* 2001, **85**:1098-103
4. Lam BL, Fingert JH, Shutt BC, Singleton EM, Merin LM, Brown HH, Sheffield VC and Stone EM **Clinical and molecular characterization of a family affected with X-linked ocular albinism (OAI)**. *Ophthalmic Genet* 1997, **18**:175-84
5. Schiaffino MV, Bassi MT, Galli L, Renieri A, Bruttini M, De Nigris F, Bergen AA, Charles SJ, Yates JR and Meindl A **Analysis of the OAI gene reveals mutations in only one-third of patients with X-linked ocular albinism**. *Hum Mol Genet* 1995, **4**:2319-25
6. Bassi MT, Bergen AA, Bitoun P, Charles SJ, Clementi M, Gosselin R, Hurst J, Lewis RA, Lorenz B and Meitinger T **Diverse prevalence of large deletions within the OAI gene in ocular albinism type I patients from Europe and North America**. *Hum Genet* 2001, **108**:51-4
7. Oetting WS **New insights into ocular albinism type I (OAI): Mutations and polymorphisms of the OAI gene**. *Hum Mutat* 2002, **19**:85-92
8. d'Addio M, Pizzigoni A, Bassi MT, Baschiroto C, Valetti C, Incerti B, Clementi M, De Luca M, Ballabio A and Schiaffino MV **Defective intracellular transport and processing of OAI is a major cause of ocular albinism type I**. *Hum Mol Genet* 2000, **9**:3011-8
9. Rosenberg T and Schwartz M **X-linked ocular albinism: prevalence and mutations – a national study**. *Eur J Hum Genet* 1998, **6**:570-7
10. Schiaffino MV, d'Addio M, Alloni A, Baschiroto C, Valetti C, Cortese K, Puri C, Bassi MT, Colla C and De Luca M **Ocular albinism: evidence for a defect in an intracellular signal transduction system**. *Nat Genet* 1999, **23**:108-12
11. Shen B and Orlow SJ **The ocular albinism type I gene product is an N-glycoprotein but glycosylation is not required for its subcellular distribution**. *Pigment Cell Res* 2001, **14**:485-90
12. Charles SJ, Moore AT and Yates JR **Genetic mapping of X linked ocular albinism: linkage analysis in British families**. *J Med Genet* 1992, **29**:552-4
13. Beggs AH, Koenig M, Boyce FM and Kunkel LM **Detection of 98% of DMD/BMD gene deletions by polymerase chain reaction**. *Hum Genet* 1990, **86**:45-8

Publish with **BioMed Central** and every scientist can read your work free of charge

"BioMed Central will be the most significant development for disseminating the results of biomedical research in our lifetime."

Sir Paul Nurse, Cancer Research UK

Your research papers will be:

- available free of charge to the entire biomedical community
- peer reviewed and published immediately upon acceptance
- cited in PubMed and archived on PubMed Central
- yours — you keep the copyright

Submit your manuscript here:  
http://www.biomedcentral.com/info/publishing\_adv.asp

