



HERPES SIMPLEX VIRUS ASSOCIATED ACUTE LIVER FAILURE: A DIFFICULT DIAGNOSIS WITH A POOR PROGNOSIS

Philippe Ichai¹, Anne Marie Roque Afonso², Mylène Sebah³, Daniel Azoulay¹, Liana Codés¹, Maria Eugenia Gonzalez¹, Faouzi Saliba¹, Vincent Karam¹, Elisabeth Dussaix², Catherine Guettier³, Denis Castaing¹, and Didier Samuel¹.

1- Centre Hépatobiliaire EA 3541, Assistance Publique-Hôpitaux de Paris, Université Paris Sud, Hôpital Paul Brousse, F-94800 Villejuif, France

2- Department of Virology, EA 3541, Assistance Publique-Hôpitaux de Paris, Université Paris Sud, Hôpital Paul Brousse, Villejuif, France

3- Department of Pathology, EA 3541, Assistance Publique-Hôpitaux de Paris, Université Paris Sud, Hôpital Paul Brousse, Villejuif, France

Key words:

Acute liver failure, Herpes simplex virus, liver transplantation, real time PCR, histology, immunohistochemical

Correspondence:

Dr Philippe ICHAI, MD.

Centre Hépatobiliaire- Hôpital Paul Brousse,

12 avenue Paul Vaillant Couturier

94800 Villejuif Cedex

France

Tel : 33 1 45 59 33 31,

Fax : 33 1 45 59 38 57

Email:philippe.ichai@pbr.ap-hop-paris.fr

Abbreviations:

HSV : herpes simplex virus; LT: Liver transplantation; ICU : Intensive Care

Unit; APOLT: auxiliary partial orthotopic liver transplantation; ARDS: acute respiratory distress syndrome

ABSTRACT

Herpes Simplex (HSV) 1 or 2 infection is a rare cause of fulminant hepatitis. If the diagnosis is made early, aciclovir therapy can be effective. Otherwise, liver transplantation (LT) remains the standard treatment. Rapidity of diagnosis is therefore crucial.

Methods: Five patients presented with acute liver failure related to HSV infection. Four of them were immunosuppressed. HSV serology, blood viral cultures and histologic examination of the liver were performed, as well as HSV DNA detection on serum samples at admission.

Results: Four patients were listed for LT and three of them underwent LT. LT was not indicated in one patient who was too ill. All patients died. The diagnosis of herpetic hepatitis was made antemortem in two patients on the basis of positive blood cultures and/or immunohistochemical findings, and in the other three patients on further histologic or viral evaluation. All patients presented with primary HSV infection. One patient had primary HSV2 infection while being anti-HSV1-positive, and two other patients had HSV superinfection of an HBV-related chronic liver disease.

Conclusion: The diagnosis of HSV fulminant hepatitis is difficult to establish in the absence of specific clinical signs. This may suggest the need for early administration of aciclovir in patients with suspected HSV hepatitis, without waiting for virologic confirmation. Diagnostic methods providing fast (real time PCR) results should be implemented in such cases.

Introduction

The spontaneous prognosis of Herpes Simplex Virus (HSV)-associated fulminant hepatitis is poor, even though an effective antiviral treatment is available. This may be explained by the fact that the diagnosis is usually delayed, so that initiation of treatment is too late. At an advanced stage, liver transplantation may improve prognosis (1). The delay in diagnosis is essentially due to the lack of specific symptoms. We describe a series of five patients presenting with fulminant hepatitis related to HSV, and report the first case of a liver transplant patient presenting with HSV-2 superinfection while already anti-HSV-1-positive. The article describes the presentation and clinical outcome of these patients, with particular emphasis on virologic and histologic findings.

PATIENTS (Table 1)

From 1990 to 2003, 360 patients with fulminant hepatitis or acute liver failure were admitted to our Liver Intensive Care Unit (ICU). The etiology of acute liver failure was viral (28%), drug and toxic-induced (41%), undetermined (14 %) and due to other causes (17 %). Of these 360 patients, five (three female, two male), mean age 35.6 years (range: 15 to 55) had a final diagnosis of HSV-associated hepatitis (1.4 %). The main clinical and biological data are given in Table 1.

One patient (patient 2) was apparently immunocompetent and had no previous disease. Among the remaining four patients, one (patient 1) was infected by

Human Immunodeficiency Virus-1, and the other three had received immunosuppressive treatment after liver transplantation (patient 5), kidney transplantation (patient 3) or neurosurgery (patient 4). All patients presented with fever (between 38°C and 39°C) and two of them had leukopenia (patients 2 and 4). None presented with skin lesions suggestive of HSV. HSV hepatitis was suspected in only one patient (patient 3) because of her immuno-depressed status, and empiric therapy with aciclovir was started.

Three patients (patients 1- 3) were referred to our center with acute liver failure of unknown etiology, having been initially managed in other centers before transfer to our unit. The mean time period between onset of symptoms and admission to our ICU was 7.7 ± 1.1 days (range, 7-9 days). In one patient (patient 4), fulminant hepatitis occurred during hospitalization 12 days after neurosurgery for a benign brain tumor. In the last patient (patient 5), liver failure occurred 31 days after an auxiliary partial orthotopic liver transplantation (APOLT) with a left liver and two days after native right hepatectomy (Figure 1 and legend). On admission or at the time of diagnosis of fulminant hepatitis, the mean Glasgow coma score was 10.3 ± 3.4 (range, 7-15) and mean prothrombin level 22.7 ± 20.4 % (range, 9-53). Percutaneous liver needle biopsy was performed in one patient (patient 3) within 24 hours of admission. In three patients, HAV, HBV, HCV, EBV, and CMV serologies were negative. No vascular, toxic, or drug-related cause for hepatitis was found and the origin remained undetermined at this stage. Two patients (patients 1 and 3) were chronically infected with HBV. Antiviral treatment with lamuvidine

was started on admission, only on the assumption of viral HBV reactivation.

METHODS

Patient management

Clinical assessment was performed using the Glasgow Coma Score (GCS) and the Trey and Davidson classification of encephalopathy. Cerebral edema was treated with mannitol 20 % (0.5-1 g / kg body weight every 4 hours). Hyponatremia, hyponatremia, hypophosphoremia and hypoglycaemia, as potential causes of neurological disturbance, were corrected. Patients with renal failure or cerebral edema were placed on continuous veno-venous hemofiltration (Prisma, Hospal, Lyon, France). In all patients, arterial blood pressure, central venous pressure, pulmonary artery capillary wedge pressure, and cardiac output were measured with radial arterial lines and Swan-Ganz catheters (Baxter-Edwards, Abbot, USA), with the objective of maintaining mean arterial blood pressure greater than 65 mmHg.

Criteria for liver transplantation were the presence of grade 3 to 4 hepatic encephalopathy associated with either factor V level less 20% of normal for patients less than 30 years of age, or factor V level less than 30 % of normal in patients more than 30 years of age (2, 3, 4).

After liver transplantation, patients received immunosuppressive induction by thymocyte globulin (patients 2, 4 and 5), followed by maintenance with prednisolone, ciclosporin (patient 4) and/or Tacrolimus (Fujisawa, Munich, Germany) (patients 2 and 5) and azathioprine (patient 5).

Virological methods

On admission, patients with acute liver failure or fulminant hepatitis were screened for anti-HAV IgM, hepatitis B surface antigen (HBsAg), anti-HBc IgM (Biomerieux, Marcy l'Etoile France), anti-VCA (EBV) IgM (Meridian Bioscience, Ohio), anti-CMV IgM, anti-HSV1 and 2 IgM (Dade Behring, Marburg, Germany) and anti-HCV antibodies (Biomerieux, Marcy l'Etoile France). Results for HAV IgM, HBsAg and HBc IgM, HCV and CMV IgG were available within 4 hours ; however others serologies were not performed on an emergency basis and results became available within a maximum of 7 days. In addition, viral blood cultures on human fibroblasts were performed at admission. Cultures were examined at 24 and 48 hours for eventual cytopathic changes. Cultures were fixed after 48 hours and examined by the immunoperoxidase technique for CMV antigen.

After 1997, qualitative HSV DNA amplification was performed on serum or liver biopsy samples if preliminary serological investigations (HAV and HBV) were negative. PCR results were available within a maximum of 5 days. This investigation was performed for three patients (patients 1, 2, 3). A retrospective investigation was undertaken for patient 5 on stored sera and biopsies. In the case of patient 4, no material was available for molecular testing.

In some cases, type-specific HSV serology was performed (HSV-1 recombinant IgG ELIT and HSV-2 recombinant IgG ELIT, Eurobio, Paris, France).

In patients who were HBsAg positive, HBV viral load was quantified with the

Cobas HBV Monitor technique (Roche Diagnostics, Emeryville NJ).

Histological methods

Tissue was fixed, embedded in paraffin and stained with hematein eosin safran, Picrosirius for collagen and Perls for hemosiderin. Histological review was performed on specimens from native livers in all patients (at the time of transplantation in patients 2 and 4, and at the time of right hepatic resection in patient 5, with post-mortem liver biopsies in patients 1 and 3); samples were also taken from the allograft in patient 5 (liver biopsies and explant at the time of the retransplantation). Slides were reviewed by one pathologist (MS), who evaluated portal tracts, lobular parenchyma, and centrilobular areas in a systematic fashion.

Findings were regarded as consistent with HSV-related hepatitis in the presence of extensive areas of hepatocyte necrosis with adjacent congestion, few inflammatory infiltrates, purple nuclear inclusions with a clear halo in the hepatocytes, and the presence of multinucleated hepatocytes (5).

Immunohistochemical staining to confirm the diagnosis of HSV was performed when histological findings were suggestive of HSV-related hepatitis or when virological tests were previously positive for HSV. The presence of viral antigens was demonstrated by an indirect three-layer immunoperoxidase staining and by monoclonal antibodies against HSV-1 and HSV-2 antigens (Dakopatt)

RESULTS

Clinical outcome

Clinical and biological results are detailed for each patient in Table 2.

Three patients were referred to the ICU for fulminant hepatitis (patients 1, 2, 3). Two of these three patients (patients 1 and 2) were listed for liver transplantation on a super-emergency basis because of deteriorating liver function and neurological status. One patient (patient 1) was withdrawn from the list because of worsening respiratory distress and cardio-vascular collapse and finally died from multi-organ failure within 12 hours of admission. The second (patient 2) underwent liver transplantation. The Third patient (patient 3) deteriorated very rapidly, within hours after a percutaneous liver biopsy, and died of a hemoperitoneum and intrahepatic hematoma. These three patients required respiratory intubation and mechanical support 25.3 ± 14.1 hours (range, 12- 40) after admission. Aggressive continuous veno-venous hemofiltration was also performed in one patient (patient 1) because of cerebral edema. Two of these three patients (patients 2 and 3) were treated with aciclovir IV (30mg/kg/d), for one day before death and before liver transplantation, respectively, without improvement of hepatic function. Hepatic function returned to normal after liver transplantation in patient 2 (factor V level more than 50 % on the fourth postoperative day), and she was weaned from mechanical ventilation after neurologic recovery. However, 29 days after liver transplantation, this patient died of haemothorax.

Acute Liver Failure occurred during hospitalization for other causes in two patients (patients 4 and 5). One of these patients (patient 4) underwent liver transplantation. After liver transplantation, although hepatic function returned to normal, she developed many complications : subdural haematoma, kidney failure and sepsis. Neurologic recovery was slow and she retained some neurologic sequelae (motor deficits). This patient died from chronic rejection and immunosuppression-induced complications one year later. The second patient was retransplanted as an emergency for acute liver failure of unknown etiology occurring 31 days after a first liver transplantation (figure 1). This liver failure was recognized a posteriori as herpetic hepatitis on the first graft. In the post-transplant period she developed acute respiratory distress syndrome (ARDS). The broncho-alveolar lavage recovered HSV-2. At the same time, liver enzymes were re-increasing 4 days after the second liver transplantation due to herpetic hepatitis. The patient was treated by intravenous aciclovir (30mg/kg/d) but died of multiorgan failure 11 days later.

Virological results (Tables 3 & 4)

HSV was detected by viral culture or PCR amplification in the antemortem period only in the patients (patients 2 and 4) who underwent liver transplantation. In the case of patient 2, HSV-2 was isolated before liver transplantation from blood viral cultures 24 hours after admission. HSV serology was negative at admission and seroconversion was observed on day 8 after admission. In the case of patient 4, HSV-2 was isolated from the culture of

the explanted liver 24 hours after transplantation. Anti-HSV IgM was positive on admission to our ICU.

Two patients (patients 1 and 3) died within 24 hours of admission. HSV-1 was detected in serum in both cases by PCR amplification. Anti-HSV serology was negative for patient 1 but anti-HSV IgM was detected for patient 3. These two patients were also serum HBsAg positive and anti-HBcIgM negative with high HBV viral loads : over 8.0 log copies/ml for patient 1 and 7.1 log copies/ml for patient 3.

On the basis of positive immunostaining of the right liver with anti-HSV-2 antibodies (Figure 1), a retrospective virologic investigation was undertaken for patient 5. HSV DNA was not detected in serum on days 0 and 15 after APOLT and was not detected either at day 0 in the native liver or in the first liver graft. HSV DNA was negative in a liver graft biopsy sampled on day 15. HSV-2 DNA was detected in a serum sample on the day of the right hepatectomy, which was 30 days after APOLT. HSV 1 serology was positive prior to transplantation, and anti-HSV-2 seroconversion was seen on day 30 after APOLT. The recipient of the right graft from the same donor did not show HSV-2 seroconversion.

Thus a virological diagnosis of primary HSV infection was made for all five patients : HSV-1 in two cases and HSV-2 in three.

Histological results

The diagnosis of fulminant hepatitis due to HSV was made histologically in

two patients (patients 1 and 3) at post mortem and in two patients (patients 2 and 4) after liver transplantation. The diagnosis of herpetic hepatitis in patient 5 was not made until her death. Histologic results are shown in Table 3 and Figure 1.

In all patients, hepatocyte necrosis was present. The intensity and topography of the necrosis varied between patients (Table 3 and Figure 1). The characteristic pattern of necrosis (Figure 2) was suggestive of HSV in all but two patients (patients 1 and 3), in whom the necrosis was suggestive of a shock liver. In addition to the acute hepatitis, there was an underlying hepatopathy due to HBV in these two patients with high viral loads. For the remaining three patients, the liver was not fibrotic.

Immunohistochemical stains were positive for HSV1 and/or HSV2 in all patients.

DISCUSSION

The diagnosis of HSV-related hepatitis is difficult. Of the 52 HSV hepatitis cases reviewed by B Kaufman et al, the diagnosis was made in the antemortem period for only 23% (6). Our series of 5 patients with HSV-1 or 2-associated acute liver failure emphasizes the difficulty of the diagnosis, in a life-threatening context. In most cases, a positive diagnosis is made too late. However, some features should be emphasized : (i) All patients had fever on admission but none had herpetic lesions. (ii) Leukopenia was present in only two of five patients. (iii) In this study, virologic and histologic results were concordant, but available too late. (iiii) Only two patients were treated with intravenous aciclovir ; one as an empiric preemptive treatment in a immunosuppressed patient and the second after positive results of viremia.

The diagnosis of HSV hepatitis was considered on the basis of histological findings in three patients, emphasizing the importance of histology in severe hepatitis not due to a classical virus (HBV, HAV) and when virological results are delayed. Virological results were available before histology findings in only two cases.

Thus histology, assessed on transjugular liver biopsy specimens, can establish or confirm the diagnosis of herpetic hepatitis (7, 8) when tests have ruled out the main causes of hepatitis (HAV, HBV, CMV, toxic, vascular and metabolic). This is so even in the presence of an underlying liver disease, such as HBV chronic liver disease, as shown in two of the five patients. This liver biopsy should performed by the transjugular route, even if liver function do not

contraindication the percutaneous route. Indeed, a secondary bleeding is always possible if the liver function deteriorate as was the case in one patient in this series (pt 3).

Immunohistochemistry using anti-HSV1 and anti-HSV2 antibodies can make or confirm the diagnosis within four to eight hours. HSV culture from liver biopsies also provides a definitive diagnosis, although this invasive procedure is not always possible with such severely ill patients (for example with hemodynamic instability or cerebral edema).

This study demonstrates that virological testing of serum could establish the diagnosis in such cases, since HSV viremia was positive in all cases. However, virological diagnosis is often delayed in such patients, partly because the diagnosis is not suspected by clinicians and partly because most virological investigations are not made on an emergency basis. Furthermore, serological assays have very limited value for establishing an early diagnosis and their results do not always contribute (9, 10,11) (for example with absence of IgM, or even negative serology), as shown in two cases in our series. Viral blood cultures have traditionally been regarded as the gold standard for diagnosis (11). They can be rapidly positive (24 to 48 hours) but false negative results may be obtained when empiric antiviral treatment has been given. This was probably the case for patient 3 in this series. Thus, the molecular methods appear as the most reliable for diagnosis (12). In our series, PCR was positive in all four patients with available sera. However, “classical” PCR is time consuming and does not provide fast results. The recently-developed real time

PCR should change the situation by providing results in less than three hours after sampling (13, 14, 15).

The diagnosis of herpetic hepatitis was certain in three patient (2,4 and 5) because of 1) clinical history, 2) positive PCR, 3) presence of massive hepatocyte necrosis on native livers, and 4) the presence of nuclear inclusions and immunohistochemical strongly positive staining.

In the two remaining patients, the diagnosis was more misleading at early clinical presentation because of the concomitant chronic infection by HBV, high HBV DNA viral, and the absence of signs of cirrhosis. However, the histological findings, the presence of strongly positive HSV immunohistochemical staining on liver autopsy specimens are more in favour of the HSV etiology. We couldn't rule out the fact that infection of HBV had contributed to the severity of the hepatitis.

The spontaneous prognosis of HSV-related hepatitis is poor, in spite of the existence of an antiviral treatment. In the series of Aboguddach et al., 81 % of the patients presenting with herpetic hepatitis died (16). In view of this very poor prognosis, we feel that the diagnosis of HSV-related hepatitis should be considered in immunocompetent or immunocompromised patients with high fever, leukopenia, marked elevations of aminotransferase levels after exclusion of other causes of fulminant hepatitis (on the basis of a careful history and laboratory studies). In such cases, systematic preemptive treatment with aciclovir should be given. This treatment could be stopped in the case of subsequent negative viremia or negative histology (7, 17). Several case reports

and extensive studies of aciclovir for neonatal HSV infection have shown the effectiveness of this drug (18, 19). In addition, aciclovir is easy to administer and has few side effects ; it requires only dose reduction in the presence of renal insufficiency (20). Unfortunately, only two patients in our series were treated with aciclovir and despite treatment one patient required transplantation and the other died rapidly.

In terms of pathogenesis, HSV hepatitis has been described during both recurrent and primary HSV infection in immunocompromised hosts (21, 22, 23, 24). In immunocompetent hosts, however, only primary infections have been associated with hepatitis (20, 25, 26, 27). All our patients presented with primary infection. Both HSV types can induce severe or fulminant acute hepatitis (24) although HSV-2 is more frequent, perhaps because HSV-2 primary infections are more common in adulthood as sexually transmitted diseases (25, 28). Since the late 1970s, the prevalence of HSV-2 infection has increased by 30 percent (29). The prevalence of HSV 1 and HSV2 in teenagers is 62 % and 12 % respectively (30). Another study reported that 21.9 % of teenagers over the age of 12 years were HSV 2 positive, with a higher proportion of girls affected (prevalence 25.6 %). Less than 10 percent of those who were anti-HSV-2 positive reported a history of genital herpes infection. Among the three patients with HSV-2 primary infection in our series, only one (patient 2) had evidence of sexual transmission. In other two patients (patients 4 and 5), the primary infection developed during hospitalization, suggesting nosocomial transmission. However the source could have been either hospital

staff or visitors, excreting HSV with or without visible lesions (31). The transmission mode of the two HSV-1 primary infections was not ascertained. This is the first reported case, to our knowledge, of an HSV-related hepatitis due to an HSV-2 super-infection in a patient already immune to HSV1. It is not certain whether the HSV-2 infection was implicated in the first liver failure, since no massive HSV-induced necrosis was seen ; however HSV disseminated infection certainly contributed to clinical deterioration after the second transplantation, with sequelae including ARDS, liver failure and septic shock. We also report two cases of HSV superinfection and hepatitis in patients with chronic HBV liver disease.

CONCLUSION

HSV-related fulminant hepatitis is rare and the diagnosis is difficult to establish **without** specific clinical signs. However, this difficulty can be mitigated by a systematic approach in cases where other possible etiologies have been ruled out. Diagnostic methods providing rapid results should be implemented and if necessary pre-emptive aciclovir treatment should be started before a definitive diagnosis is made.

Legends of Figures and Tables

Figure 1 : Evolution of liver tests, virologic and histological findings in patient 5

LB : Liver Biopsy ; APOLT : auxiliary partial orthotopic liver transplantation.

Patient 5 had an APOLT with a left liver because of the small size of the graft (320 mm³). The right native liver was removed on day 30 because portal cavernoma shunted the portal flow of the graft, imparting a medium term risk of inducing graft dysfunction. 48 hours after the right hepatectomy, the patient developed acute liver failure and was retransplanted. Six days later, the patient developed ARDS with shock, which proved fatal.

Figure 2 :

Explant at the time of retransplantation in patient 5 showing large foci of inflammatory necrosis. The star (*) shows a hepatocyte nuclear inclusion with a clear halo; the double star (***) shows a multinucleate hepatocyte.

Immunostaining against Herpes virus. Nuclei are positive as well as the cytoplasm of some cells.

Table 1 : Characteristics of the five patients on admission

SAPS, Simplified acute physiology score ; APACHE, Acute physiology and chronic health evaluation ; AST, aspartate aminotransferase ; ALT, alanine aminotransferase ; LT, liver transplantation ; IMS, immunosuppressant drugs ; HBV, hepatitis B virus ; HCV, hepatitis C

virus ; AIDS, acquired immune deficiency syndrome ; PT, prothrombin time ; JE, jaundice-encephalopathy ; ALS, anti-lymphocyte serum.

a: The patient was treated by ciclosporin and mycophenolate mofetyl.

b: The immunosuppressant treatment was steroids, azathioprine, ALS and ciclosporin. The patient received a 1 g steroid bolus at day 15 following an acute rejection.

Table 2 : Results

a: This patient has not been transplanted - a graft was refused because of the state of the patient. The different parameters correspond to the time that the graft was proposed.

b: After re-transplantation

c: At the time of liver transplantation

SE, super-emergency; PT, prothrombin time

Table 3 : Virologic and histologic diagnosis in patients 1 - 4

1, culture and PCR ; 2, positive by PCR amplification and blood viral culture negative; 3,

culture ; 4, chronic hepatitis due to HBV ; * known before the death or the LT ; ** available

after death

REFERENCES

- 1) CJ Shanley, DK Braun, K Brown et al. Fulminant hepatic failure secondary to herpes simplex virus hepatitis. *Transplantation* 1995; 59 :145-149
- 2) Bismuth H, Samuel D, Castaing D, Adam R, Saliba F, Johan M, Azoulay D, et al. Orthotopic liver transplantation in fulminant and subfulminant hepatitis. The Paul Brousse experience. *Ann Surg* 1995;222:109-119
- 3) Bernuau J, Goudeau A, Poynard T, Dubois F, Lesage G, Yvonnet B, Degott C, et al. Multivariate analysis of prognostic factors in fulminant hepatitis B. *Hepatology* 1986;6:648-651
- 4) Bernuau J, Samuel D, Durand F. Criteria for emergency liver transplantation in patients with acute viral hepatitis and factor V below 50% of normal: a prospective study [Abstract]. *Hepatology* 1991;14:49A.
- 5) Lucas SB. Other viral and infectious diseases and HIV-related liver disease. In: MacSween RNM, Antony PP, Scheuer PJ, eds. *Pathology of the liver*. 4th ed Edinburgh: churchill Livingstone, 2002:363-414
- 6) B Kaufman, SA Gandhi, E Louie. Herpes simplex virus: case report and review. *CID* 1997 ; 24 :334-8
- 7) RW Farr, S Short, D Weissman. Fulminant hepatitis during herpes simplex virus infection in apparently immunocompetent adults: report of two cases and review of the literature. *CID* 1997 ; 24 :1191-4

- 8) DJ Peters, WH Greene, F Ruggiero, TJ McGarrity. Herpes simplex-induced fulminant hepatitis in adults. *Digestive, Disease and Science* 2000 ;45 :2399-2404
- 9) S Ustacelebi. Diagnosis of herpes simplex virus infections. *J Clin Virol* 2001 ; 21 :255-9
- 10) BD Goldman. Herpes serology for dermatologists. *Arch Dermatol* 2000, 136 :1158-61
- 11) B Ohana, M Lipson, N Vered, I Srugo, M Ahdut, A Morag. *Clin Diagn Lab Immunol* 2000 ; 7 :904-8
- 12) G Lucotte, C Bathelier, V Lespiaux, C Bali, T Champenois. Detection and genotyping of Herpes simplex virus type 1 and 2 by polymerase chain reaction. *Mol Cell Probes* 1995 ; 9 : 287- 90
- 13) G JJ van Doornum, J Guldemeester, ADME Osterhaus, HGM Niesters. Diagnosing Herpesvirus infections by real time amplification and rapid culture. *J Clin Microbiol* 2003 ; 41 :576-580
- 14) J Burrows, A Nitsche, B Bayly, E Walker, G Higgins, T Kok. Detection and subtyping of Herpes simplex virus in clinical samples by LightCycler PCR, enzyme immunoassay and cell culture. *BMC Microbiol* 2002 ;2 :12
- 15) HH Kessler, G Muhlbauer, B Rinner, E Stelzl, A Berger, HW Dorr, B Santner, E Marth, H Rabenau. Detection of Herpes simplex virus DNA by real-time PCR. *J Clin Microbiol* 2000 ; 38 :2638-42
- 16) Aboguddah A, Stein HB, Phillips P, English R. Herpes simplex hepatitis in a patient with psoriatic arthritis taking prednisone and methotrexate. Report and review of the literature. *J Rheumatol* 1991;18:1406
- 17) AD Pinna, J Rakela, AJ Demetris, JJ Fung. Five cases of fulminant hepatitis due to herpes simplex virus in adults. *Digestive Disease and Science* 2002 ; 47(4) : 750-754

- 18) AH Kang, CR Graves. Herpes simplex hepatitis in Pretentaine [?]: a case report and review of the littérature. *Obstet Gynecol Survey* 199X[?] ; 54 :463-468
- 19) H Egawa, Y Inomata, S Nakayama et al. Fulminant hepatic failure secondary to herpes simplex virus infection in a neonate : a case report of successful treatment with liver transplantation and perioperative aciclovir. *Liver Transplantation and Surgery* 1998. 4 : 513-516
- 20) R Whitley, A Arvin, C Prober et al. A controlled trial comparing vidarabine with acyclovir in neonatal herpes simplex virus infection. *Infectious Diseases Collaborative Antiviral Study Group. N Engl J Med* 1991 ; 324 :444
- 21) M Velasco, E Llamas, M Guijarro-Rojas, M Ruiz-Yagüe. Fulminant herpes hepatitis in a headline adult: a treatable disorder. *J Clin Gastroenterol* 1999; 28 :386-389
- 22) Y Miyazaki, S Akizuki, H Takaoka, S Yamamoto, H Terao. Disseminated infection of herpes simplex virus with fulminant hepatitis in a healthy adult. *APMIS* 1991 ;99 : 1001-1007
- 23) M Lasserre, C Huguet, O Terno. Acute sévère herpes simplex healthy [??] with virus-associated hemophagocytic syndrome in an immunocompetent adult. *J Hepatol.* 1993 ; 18 : 256-7
- 24) Chase RA, Pottage JC Jr, Haber MH, Kistler G, Jensen D, Levin S. Herpes simplex viral hepatitis in adults: two case reports and review of the literature. *Rev Infect Dis* 1987;9: 329
- 25) RJ Taylor, SH Saul, JN Dowling, TR Hakala, RL Peel, M Ho. Primary disseminated herpes simplex infection with fulminant hepatitis following renal transplantation. *Arch Intern Med* 1981 ; 141 : 1519-1521
- 26) RD Shlien, S Meyers, JA lee, R Dische, HD Janowitz. Fulminant herpes simplex hepatitis in a patient with ulcerative colitis. *Gut* 1988 ; 29 : 257-261.

- 27) SR Holdsworth, RC Atkins, DF Scott, K Hayes. Systemic herpes simplex infection with fulminant hepatitis post-transplantation. *Aust.N.Z.J. Med* 1976 ;6 : 588-590
- 28) JL Auch Moedy, SJ Lerman, RJ White. Fatal disseminated herpes simplex virus infection in a healthy child. *Am J Dis Child* 1981 ;135 : 45-47
- 29) DT Fleming, GM McQuillan, RE Johnson, AJ Nahmias, SO Aral, FK Lee, ME St Louis. Herpes simplex virus type 2 in the United States, 1976 to 1994. *N Engl J Med* 1997 ; 337 : 1155-11
- 30) SL Rosenthal, LR Stanberry, FM Biro et al . Seroprevalence of herpes simplex type 1 and 2 and cytomegalovirus in adolescents. *Clin Infect Dis* 1997 ; 24 :135-139
- 31) A Wald, J Zeh, S Selke, R Ashley, L Corey. Virologic characteristics of subclinical and symptomatic genital herpes infections. *N Engl J Med* 1995 ; 333 : 770-5

Table 1

	1	2	3	4	5
Age/Gender	36/M	24/F	55/F	15/F	48/F
Main antecedent	AIDS (opportunistic infection)	0	Renal transplantation 30 yrs earlier	Cerebral Cavernoma	LT for familial amyloid polyneuropathy 1 m earlier
Immunity state	AIDS	Normal	IMS ^a	Prednisolone therapy	IMS ^b
Chronic hepatothopathy	HBV	No	HBV and HCV	No	No
SAPS II	83	30	27	30	41
APACHE II	39	14	22	21	13
INITIAL CLINICAL FEATURES					
Fever	38°C	39°C	39°C	38.5°C	38.5°C
Abdominal pain	Yes	Yes	Yes	No	No
Herpetic skin lesions	No	No	No	No	No
Leukopenia (/mm ³)	5600	2700	5000	9000	8000
Hepatic encephalopathy	4	0	4	4	3
Glasgow (NI:3 to 15)	7	15	9	10	11
Hemodynamic shock	Yes	No	Yes	No	No
ME interval (days)	1	2	3d	5	-
PT	16 %	< 9 %	53 %	13 %	30 %
Factor V	15 %	6 %	70 %	13 %	25 %
Bilirubin (µm/L)	65	61	76	95	20
AST (IU/L)	5093	1170	2064	5000	70
ALT (IU/L)	1650	432	355	4500	22
Creatinin (µm/L)	321	73	402	320	70
Aciclovir treatment (days after onset of the disease)	No	Yes (2d)	Yes (5d)	No	No

	Yes	Yes, post-LT	No	Yes, pre and post LT	No
HE _{LT} or during evolution	4	4	4	4	4
GCS _{LT} ^c	3	7	5	7	10
Coma stage _{LT} ^c	1 ^a	2	3	4	5
SE list _{LT}	Yes	Yes	No	Yes	Yes
FTLT (%)	< 10 %	< 10 %	No	17 %	19 %
Factor V ^c or SE cerebral edema	Yes	No	Yes	No	No
Bilirubin (µm/L) or SE hemodynamic necessity	65	70	Spontaneous	95	47
AST treatment (IU/L) positive	6000	8000		4500	70
aptrop _{LT} ^c (IU/L)	2300	2000		5001	22
Hemodiafiltration	Yes	Yes, post-LT	No	Yes, pre and	No

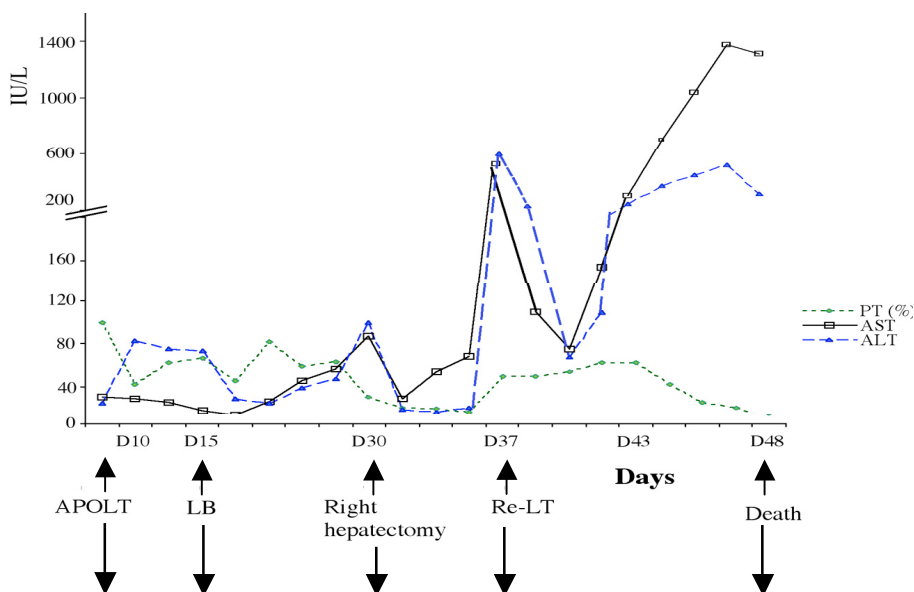
Creatinin _{LT} ^c (µm/L)	280	250		210	150
Delay LT-wake up	-	10 d	-	32 d	No wake up
Alive / follow-up	Died	Died	Died	Died	Died
Cause of death	Decortication	Haemothorax	Haemorrhage shock	sepsis	SDRA Sepsis
HSV persistence after LT	-	No	-	No	Yes
Prophylactic aciclovir therapy after LT	-	No	-	No	No

Table 2

Table 3

	1	2	3	4
VIROLOGICAL FINDINGS				
HSV1 & HSV-2 serology adm	negative	negative	IgG : pos IgM : pos	IgG :800, IgM > 200
Seroconversion	-	Yes J7 IgG>1000, IgM weakly positive	-	-
Viremia adm	HSV 1 positive§§	HSV 2 positive ^{1*} HSV1 negative ¹	HSV1 positive ^{2**}	HSV1 negative ^{3§} HSV2 positive
HISTOLOGICAL				
● Material	Autopsy liver biopsy	Whole native liver	Autopsy liver biopsy	Entire native liver
● Histological findings				
Fibrosis	Porto-portal ⁴	No	Septal ⁴	No
Necrosis	Almost total	Periportal & mediolobular	Disseminated foci	Medio & centrilobular
Inflammation	No	Mild (neutrophils)	Mild (neutrophils)	Mild (lymphocytes and neutrophils)
Multinucleated cells	No	++	No	No
Nuclear inclusions	+	++	No	++
Steatosis	Microvacuolar	Macro & microvacuolar	Macro & microvacuolar	No
Sinusoidal congestion	No	+	No	+++
Centrolobular endothelialitis	No	+	No	No
Histological findings suggestive or non suggestive of herpetic hepatitis				
	Non suggestive	Suggestive	Non suggestive	Suggestive
Immunohistochemical findings				
HSV 1	0	-	+	-
HSV2	+++	+	+++	+

Figure 1



VIROLOGICAL FINDINGS						
Serology						
HSV 1 & 2 serology	+					
HSV1 serology	+		+			
HSV2 serology	-		+			+
PCR blood						
HSV 1 PCR	-		-			
HSV 2 PCR	-		+			+
HISTOLOGICAL FINDINGS						
material			Right native liver	Left graft	Autopsy LB	
Fibrosis			No	No	No	
Necrosis			Under the capsule	Periportal	Periportal & mediolobular	
Inflammation			Moderate (neutrophils)	Moderate (neutrophils)	Mild (neutrophils)	
Multinucleated cells			+	No	+	
Nuclear inclusions			++	++	+	
Steatosis			No	microvacuolar	No	
Sinusoidal congestion			No	+	+	
Centrolobular endothelialitis			No		No	
Histological findings suggestive or non suggestive of herpetic hepatitis						
			Suggestive	Suggestive	suggestive	
IMMUNOHISTOCHEMICAL FINDING						
HSV1			-	+	Inadequate	
HSV2			+	+	Inadequate	

